

**Abdulkadir I  
Abdullahi F  
Hassan L  
Purdue S  
Okpe M  
Mohammed A  
Aminu AT  
Usman N  
Aliyu H  
Ogala WN**

## The Use of bubble nasal CPAP in the management of IRDS -A Case report and literature review

DOI:<http://dx.doi.org/10.4314/njp.v40i3.22>

Accepted: 27th January 2013

Abdulkadir I, (✉)  
Abdullahi F, Hassan L, Purdue S, Okpe M, Mohammed A, Aminu AT, Usman N, Aliyu H, Ogala WN  
Department of Paediatrics  
Ahmadu Bello University Teaching Hospital Shika – Zaria, Kaduna State Nigeria.

**Abstract** A one hour old baby boy presented to the Special Care Baby Unit (SCBU) of the Ahmadu Bello University Teaching Hospital (ABUTH), Shika, Zaria, on account of respiratory distress noticed from birth. He was a product of supervised pregnancy, delivered at 37 weeks gestation via emergency caeserian section performed due to severe pre eclampsia and fetal distress. APGAR scores were 2 and 7 at one and five minutes respectively. He weighed 1850 grams and was found to be dusky, inactive, hypothermic ( $T = 35.5^{\circ}\text{C}$ ) and in severe respiratory distress ( $\text{SPO}_2$  ranged between 60 % and 72 %). He was tachypnoeic with respiratory rate persistently above 80 cycles/ min, and had reduced air entry in the mid and lower zones of the lungs bilaterally with wide spread coarse crepitations. A diagnosis of perinatal asphyxia was

entertained with differential diagnoses of pulmonary hypoplasia, hyaline membrane disease and group B streptococcal (GBS) pneumonia. He had a full sepsis screen including chest radiograph and was commenced on supplemental oxygen via nasal cannula, antibiotics and other supportive measures. The patient however continued to have laboured breathing and subsequently had an apnoeic attack. He was resuscitated and commenced on bubble nasal CPAP. He did remarkably well and was weaned off CPAP after a total of 60 hours. A repeat chest radiograph showed remarkable aeration of the lungs as against an earlier one which showed a reticulogranular (ground glass) appearance.

**Key words:** Neonates, Respiratory distress, Bubble nCpap, Downes score.

### Introduction

Newborns who develop respiratory distress may require respiratory support which could be provided via various methods. Continuous positive airway pressure (CPAP) refers to a mode of respiratory support where positive pressure is provided to a spontaneously breathing neonate. This has become a popular and effective therapy in the management of idiopathic respiratory distress syndrome (IRDS) which remains a common cause of respiratory distress in the preterm neonate.<sup>1</sup> CPAP can be applied via different types of interface including nasal prongs, nasopharyngeal tube and face mask using a conventional ventilator, bubble circuit or a CPAP driver as

the pressure generating source.<sup>1-6</sup> Bubble CPAP is a low cost nasal continuous positive airway pressure delivering system which has been in use since the seventies but is regaining popularity due to its gentleness on the fragile lungs of the neonate. Also, it is free of severe complications associated with modern mechanical ventilator usage in newborns.<sup>3-6</sup> Indications for the use of CPAP include idiopathic respiratory distress syndrome (IRDS), apnoea of prematurity or obstructive apnoea, post-extubation in preterm VLBW infants and transient tachypnoea of newborn (TTNB)/delayed adaptation.<sup>3-9</sup> Other indications include pneumonia, mild meconium aspiration or other aspiration syndromes, pulmonary edema, pulmonary hemorrhage and laryngomalacia.<sup>3-9</sup>

The bubble CPAP system essentially consists of three components: a continuous gas flow into the circuit, an expiratory limb with the distal end submerged into a liquid to generate positive end expiratory pressure (PEEP) and the nasal interface connecting the infant's airway to the circuit.<sup>1,4</sup> It was developed and first used by Dr. Jen-Tien Wung at the Columbian Presbyterian Medical Center, New York.<sup>1</sup> Subsequently the use of bubble CPAP has been associated with a reduction in the number of newborns requiring mechanical ventilation.<sup>5</sup> A retrospective study of neonates at Columbia University, where the predominant mode of respiratory support was the use of nasal CPAP, revealed that treated babies had the lowest incidence of chronic lung disease (CLD) without any significant difference in mortality.<sup>6</sup> Other studies have also shown that the use of bubble CPAP is not associated with increase in short or long term morbidities.<sup>7-12</sup> In Nigeria, management of newborns with respiratory distress continues to pose challenge to neonatal care providers and experience with the use of bubble CPAP remains very low. The use of bubble CPAP was introduced in our centre in June 2012. We present the case of a neonate who was admitted and successfully managed for IRDS using bubble CPAP to highlight the practicability of providing this mode of respiratory support to neonates with respiratory distress in resource - poor setting like ours.

### Case report

An hour old baby boy, who was delivered via emergency caesarian section to a 31 yr old Para 3 mother was admitted to the Special Care Baby Unit of Ahmadu Bello University Teaching Hospital (ABUTH) due to respiratory distress.

An early obstetric scan revealed a normal singleton pregnancy which was subsequently booked at the 28th week of gestation with normal booking parameters at a private hospital in Zaria. She had a total of three visits at 4-weekly intervals before she presented to the Obstetric unit of ABUTH at about the 37<sup>th</sup> week of gestation where she was evaluated and subsequently delivered of a live male neonate via emergency caesarian section performed on account of complications of hypertension in pregnancy, severe oligohydramnios and fetal distress. APGAR scores were 2 and 7 at one and five minutes respectively, and the baby was dried, covered, kept warm, suctioned and oxygen administered via face mask before he was transferred to the SCBU.

In the SCBU he was found to be dusky, in severe respiratory distress and moderately hypothermic ( $T = 35.5^{\circ}\text{C}$ ). He weighed 1850 grams and was adjudged small for gestational age (SGA). He was floppy, tachypnoeic with respiratory rate of 80 cycles/ min and had reduced air entry in the mid and lower zones of the lungs with widespread coarse crepitations. His Downes' score<sup>5</sup> was 6 (cyanosis = 1, retraction =1, respiratory rate = 2, air entry = 1, grunting = 1) and oxygen saturation ranged between 60% and 72% but rose to 80% with commencement of oxygen supplementation via nasal cannula at a flow of 2L/ min. He had a heart rate of 142 beats/min

and heart sounds were normal. Other systems were essentially normal.

A diagnosis of perinatal asphyxia was made with differential diagnoses of pulmonary hypoplasia, hyaline membrane disease, GBS pneumonia, early onset neonatal sepsis and cyanotic congenital heart disease.

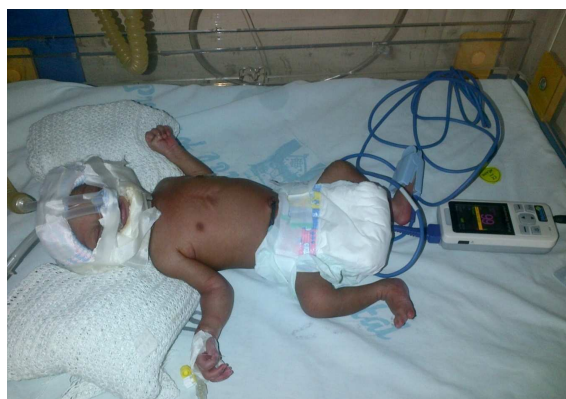Investigations including Full Blood Count (FBC) and differential, blood culture, RBS, serum urea and electrolytes, chest radiograph and intermittent oxygen saturation monitor were conducted.

### Results

Packed cell volume (PCV) of 0.40 L/L, total white cell count of  $4.7 \times 10^9/\text{L}$ , with differential white cell count of 56.4% neutrophils and 34.6% lymphocytes and platelet count of  $167 \times 10^9/\text{L}$ . Serum urea and electrolyte were normal and blood culture was negative.

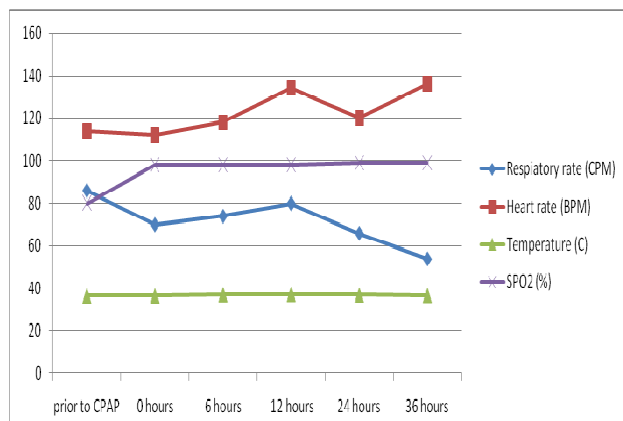
He was commenced on parenteral antibiotics - crystalline penicillin, gentamicin; intravenous fluids and subsequently upgraded to partial parenteral feeding with addition of amino acids after 24 hours. Respiratory distress worsened and he eventually had an episode of apnoea at about the 24<sup>th</sup> hour of life. The baby was resuscitated using bag and mask ventilation and after resumption of spontaneous breathing he was commenced on bubble nasal CPAP at a PEEP of 5cmH<sub>2</sub>O and a flow of 7 L/ min (Fig 1).

**Fig 1:** Neonate under Bubble Nasal CPAP



With the commencement of bubble nasal CPAP he progressively stabilized. Respiratory rate declined from 86 to 54 cycles/ min over 36 hours, his Downes' score improved to < 3, oxygen saturation rose from 70% to 98% almost immediately while heart rate and temperature remained within normal limits (Fig 2). Warmth was provided from a radiant warmer before he was transferred to an incubator.

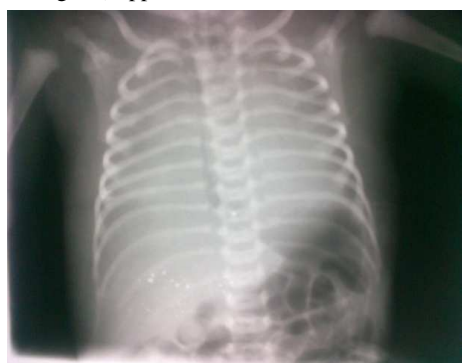**Fig 2:** Line Plot Showing Parameters of Neonate on Bubble Nasal CPAP



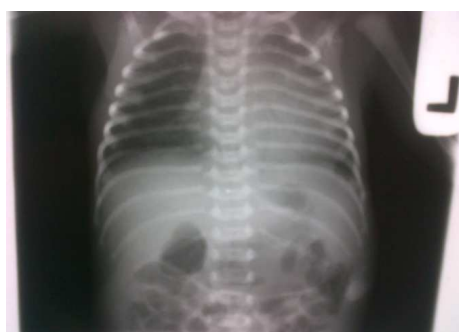He was weaned off CPAP after 36 hours when all parameters were normal. He however began to desaturate eight hours later with SPO<sub>2</sub> dropping from between 88 – 94% to 80 – 86% and respiratory rate rose from 54 cycles/ min to above 80 cycles/ min. He was recommenced on CPAP for a further 24 hours before weaning. He maintained normal oxygen saturation on supplemental oxygen at 1.5 L/min for another 18 hours before he was completely weaned off oxygen. Nasogastric tube feeding was gradually introduced and intravenous fluids gradually withdrawn.

Results of chest radiograph revealed a uniform reticulogranular (ground glass) appearance of the lung fields suggestive of grade IV IRDS (Fig 3A. taken within the first 24 hours of life) which subsequently became clear with management (Fig 3B taken on the fifth day of life).

**Fig 3A:** Chest radiograph showing reticulogranular (ground glass) appearance



**Fig 3B:** Chest radiograph showing normal findings after CPAP



## Discussion

This is the first report of the use of CPAP in the management of IRDS in our centre. The patient presented with features of respiratory distress from birth which progressively worsened, with a falling oxygen saturation pressure, apnoea and a Downes' score of 6 suggesting the requirement of respiratory support and heralding an impending respiratory failure. The chest radiograph also showed reticulogranular (ground glass) appearance suggestive of a grade IV idiopathic respiratory distress of the newborn. These factors were indications for the use of CPAP. Though IRDS is thought to be uncommon among SGA neonates due to the common assumption that intrauterine stress led to accelerated pulmonary maturation of such neonates and decreased incidence of IRDS, recent published studies however have not been supportive of this concept.<sup>12-15</sup> In addition impaired maturation of type II alveolar epithelial cells and reduced surfactant content and activity have also been reported in infants with IUGR possibly resulting from the effect of chronic hypoxia and acidosis on surfactant synthesis.<sup>13-15</sup> Oligohydramnios a known cause of pulmonary hypoplasia, which was a presentation in the index case, has also been shown to increase the risk of IRDS.<sup>16</sup> Conversely meconium aspiration syndrome and polycythaemia which are other possible causes of respiratory distress in a small for gestational age neonate were less likely in this patient with no history of meconium stained liquor and a packed cell volume of 0.40 L/L.

Initiation of CPAP resulted in a sharp rise in oxygen saturation, a decline in respiratory rate and an improvement in his Downes score. The improvement followed well known principles. By maintaining positive pressure in the airway during spontaneous breathing, alveoli are prevented from collapsing, functional residual capacity is increased, gaseous exchange is enhanced and oxygen saturation is improved.<sup>1-4</sup> After initial discontinuation of CPAP, our patient experienced deterioration which we attribute to excessive airway secretions or inadequate recruitment of alveoli. However, recommencement of CPAP for a further 24-hour period resulted in sustained improvement. Management of IRDS sometimes involves the use of exogenous surfactant. However, this potentially useful agent was not available to us and was thus not employed. This modality of treatment may or may not have influenced the course of illness in the index case because some studies<sup>1,17</sup> have compared the use of early CPAP alone to the use of a combination of surfactant and intubation and did not find superiority of either technique. Similarly the initiation of CPAP also prevented the recurrence of obstructive apnoea in this patient, a benefit which is a known indication of CPAP use.

Complications like pneumothorax, nasal septal erosion or necrosis and gastric distention (CPAP belly syndrome) may arise with use of bubble CPAP. However, our patient did not suffer any such complication possibly because care was taken to use appropriate snug-fitting

nasal prongs among other measures. The patient also did well on CPAP even on a low PEEP of 5cmH<sub>2</sub>O. Occasionally some babies may require higher PEEP and yet are not able to maintain saturation suggesting the requirement of more respiratory support in form of mechanical ventilation.

The provision of optimal newborn care and adequate management of hypothermia, an important contributor to neonatal morbidity and mortality which aggravates IRDS, would have contributed the outcome in this patient. Similarly the use of antibiotics and provision of optimal fluid and electrolytes are important. While antibiotics were employed as possible treatment for group B streptococcal pneumonia, an important differential diagnosis which may be clinically and radiographically indistinguishable from IRDS, the optimal fluid and electrolytes management provided adequate caloric requirements and prevented fluid overload, all of which are essential determinants of outcome in newborn care.

## Conclusion

The successful use of nasal bubble CPAP, a simple and inexpensive respiratory support in the management of this case of idiopathic respiratory distress syndrome in our unit promises an improved care to newborns who may require respiratory support particularly in our poor socio economic setting where there is paucity of neonatal intensive care units with ventilator support and inadequate skilled manpower to provide such care. We recommend therefore, that neonatal care providers be trained and acquainted with the use of bubble CPAP to improve newborn care in the country.

**Conflict of interest:** None

**Funding:** None

## References

1. Medha W. Non invasive respiratory support in the neonate: Continuous positive airway pressure (CPAP). *Sri Lanka Journal of Child Health* 2011; 40:172-6
2. Neil NF, Waldemar AC, Michele CW, Wade R, Marie GG et al. Early CPAP versus Surfactant in Extremely Preterm Infants. *N Engl J Med* 2010; 362 (21):1970-9
3. Prashanth SU, Firdose K, Maiya PP. Bubble CPAP - A Primary Respiratory Support for Respiratory Distress Syndrome in Newborns. *Indian Pediatr* 2009; 46: 409 - 11.
4. Chan KM, Chan HB. The Use of Bubble CPAP in Premature Infants: Local Experience. *HK J Paediatr* 2007; 12:86-92.
5. Mathai SS, Raju U, Kanitkar M. Management of Respiratory Distress in the Newborn. *MJAFI* 2007; 63(3) : 269 - 72.
6. Nowadzky T, Pantoja A, Britton JR. Bubble Continuous Positive Airway Pressure, A potentially better practice reduces the use of mechanical ventilation among very low birth weight infants with respiratory distress syndrome. *Pediatrics* 2009;123(6):1534-40
7. Avery ME, Tooley WH, Keller JB, et al. Is chronic lung disease in low birth weight infants preventable? A survey of eight centers. *Pediatrics* 1987; 79:26-30.
8. Bahareh BB, Arash M, Pedram N, Mohammad RB. Bubble-CPAP vs. Ventilatory-CPAP in Preterm Infants with Respiratory Distress. *Iran J Pediatr* 2011; 21 (2):151-8
9. Roehr CC, Schmalisch G, Khakban A, Proquitté H, Wauer R.R. Use of continuous positive airway pressure (CPAP) in neonatal units - A survey of current preferences and practice in Germany *Eur J Med Res* 2007; 12: 139 - 44
10. Roberts CL, Badgery-Parker T, Algert CS, Bowen JR, Nassar N. Trends in use of neonatal CPAP: A population-based study. *BMC Pediatrics* 2011, 11:89
11. Vidyasagar D, Velaphi S, Bhat VB. Surfactant Replacement Therapy in Developing Countries. *Neonatology* 2011; 99: 355 - 66
12. Narang A, Chaudhuri MK, Kumar P. Small for gestational age babies: Indian scene. *Indian J Pediatr* 1997; 64(2): 221-4.
13. Regev RH, Reidman B. Prematurity and intrauterine growth retardation - double jeopardy. *Clin Perinatol* 2004; 31: 453 - 73
14. Torrance HL, Derks JB, Scherjon SA, Wijnberger LD, Visser GH. Is antenatal steroid treatment effective in preterm IUGR fetuses? *Acta Obstet Gynecol Scand* 2009; 88 (10):1068-73.
15. Morrison JL, Botting KJ, Soo PS, McGillick EV, Hiscock J, Zhang S, McMillen IC, Orgeig S. Antenatal Steroids and the IUGR Fetus: Are Exposure and Physiological Effects on the Lung and Cardiovascular System the Same as in Normally Grown Fetuses? *J Pregnancy* 2012 Published online 2012 November 22. doi: 10.1155/2012/839656 Epub 2012 Nov 22.
16. Abbasalizadeh SH, Abbasalizadeh F, sharifan Z. Pulmonary Maturation in Preterm Rupture of Membranes with Oligohydramnios *J Med Sci* 2007 7: 203- 9.
17. Colin JM, Peter GD, Lex WD, Luc PB, Jean-Michel H, John BC. Nasal CPAP or Intubation at Birth for Very Preterm Infants *N Engl J Med* 2008; 358:700 - 8