

**Afolabi JK**  
**Oloko GYA**

## Paediatrics Electrocardiography

DOI:<http://dx.doi.org/10.4314/njp.v39i2.10>

Received: 28th November 2011

Accepted: 28th November 2011

Afolabi JK (✉)

Oloko GYA

Department of Paediatrics and  
Child Health

University of Ilorin Teaching Hos-  
pital, Ilorin - Nigeria

**Abstract** Electrocardiogram (ECG) is a graphic recording of the electrical potential generated in the heart on the body surface using a device called electrocardiograph which was invented more than 100 years ago by Eithoven. The cardiac muscle possesses intrinsic properties of automaticity, excitability and conductivity. Sinoatria (SA) node is the dominant pace maker. Therefore the electrical activity generated here spreads through the conduction tissue pathways, (i.e. atria, then to atrioventricular (AV) node, bundle of His and its branches, the purkinje system and ultimately to the ventricles resulting in an electrocardiographic complex consisting of P-QRS-T during a cardiac cycle. One cardiac cycle is represented by successive wave forms on an electrocardiographic tracing, the P wave, QRS complex, and the T wave.

These waves' produce two important intervals (PR and QT) and two segments (PQ and ST). After the recording has been made, each strip of the electrocardiogram should be analyzed systematically for the following: Rate, rhythm, P waves, PR interval, QRS Axis, QRS morphology, QT interval, T wave, U wave and RS progression. Paediatric ECG is unique and difficult to interpret, but can be used within certain limits to identify anatomical, metabolic, ionic and hemodynamic abnormalities. Used alone as the basis of a clinical diagnosis the error margin could be quite wide. On the other hand, when used in the proper context, it is a very useful adjunct to cardiac diagnosis.

**Keyword:** Sinoatria node, Electrocardiogram, Paediatric ECG, Unique.

### Introduction

#### *Properties of Cardiac Cells/ Mechanics of Heart Function*

- Automaticity: generates electrical impulse independently, without involving the nervous system.
- Excitability: responds to electrical stimulation.
- Conductivity: passes or propagates electrical impulses from cell to cell.
- Contractility: shortens in response to electrical stimulation.
- Cardiac cycle: sequence of events in one heartbeat. Blood is pumped through the entire cardiovascular system.
- Systole: contraction phase and usually refers to ventricular contraction.
- Diastole: relaxation phase during which the atria and ventricles are filling. This phase lasts longer

than systole.

- Stroke volume (SV): this is the amount of blood ejected from either ventricle in a single contraction. Starling's law of the heart states that degree of cardiac muscle stretch can increase force of ejected blood. More blood filling the ventricles increase the stroke volume.
- Cardiac output (CO): the amount of blood pumped through the cardiovascular system per minute.

$$CO = SV \times \text{heart rate (HR)}$$

- Sinoatrial (SA) node: dominant pacemaker of the heart located in the upper portion of the right atrium. Intrinsic rate is 60-100 beats/min.
- Atrioventricular (AV) node: part of AV junctional tissue. The AV node slows conduction, creating a slight delay before impulses reach ventricles. Intrinsic rate is 40-60 beats/min
- Intermodal pathways: directs electrical impulses

between SA and AV nodes.

- Bundle of His: transmits impulses to bundle branches. It is located below the AV node.
- Left bundle branch: conducts impulses that lead to the left ventricle.
- Right bundle branch: conducts impulses that lead to the right ventricle.
- Purkinje system: network of fibres that spread impulses rapidly throughout the ventricular walls. This is located at terminals of bundle branches and has an intrinsic rate of 20-40 beats/min.

**Definition and Historical Perspective**

An electrocardiogram (ECG) is the recording (“gram”) of the electrical activity (“electro”) generated by the cells of the heart (“cardio”) that reaches the body surface. Material used is the electrocardiograph.

Electrodes are electrical sensor connected to monitor and record. Each ECG recording electrode provides the view of this electrical activity that it “sees” from its particular position on the body surface.

Electrocardiograph is the device used, electrocardiogram is the recording, and electrocardiography is the procedure.

Electrocardiography was first introduced about 100yrs ago by Eithoven. Lead I, II and III form Eithoven triangle of 60°. Golberger added aVR, aVL and aVF to produce hexaxial reference system of 300°. Lead V1- V6 were later added for horizontal view.

**Leads in ECG Recording**

The standard limb leads (leads I, II, III) are bipolar leads which consist of two electrodes of opposite polarity (positive and negative). The third (ground) electrode minimizes electrical activity from other sources.

Augmented limb leads (aVR, aVL, and aVF) are unipolar leads which consist of a single positive electrode and a reference point (with zero electrical Potential) that lies in the center of the heart’s electrical field. The precordial leads (leads V1-V6) are unipolar leads and consist of a single positive electrode with a negative reference point found at the electrical center of the heart.

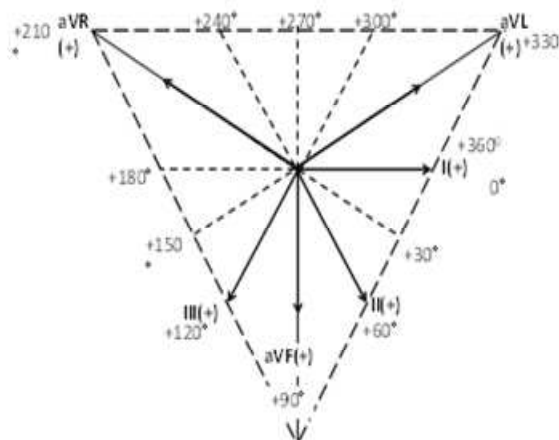
Voltage changes are amplified and visually displayed on an oscilloscope and graph paper.

**Placement of Precordial Leads**

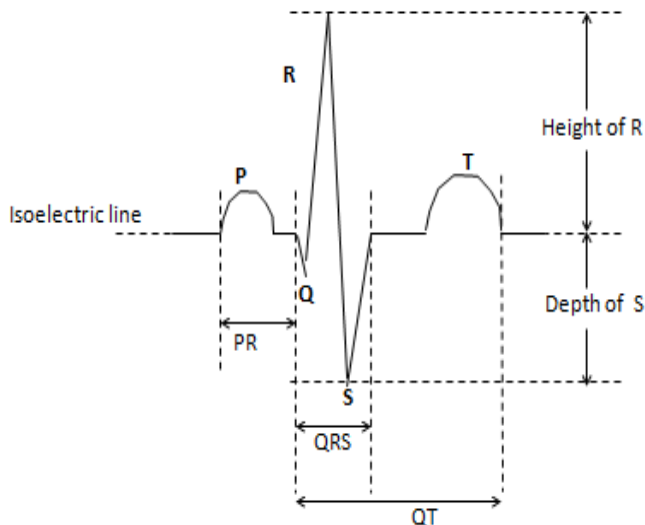
- V1 : 4th R intercostal space, parasternal
- V2 : 4th L intercostal space, parasternal
- V3 : exactly mid way between V2 and V4
- V4 : 5th L intercostal space, MCL
- V5 : same transverse level as V4, AAL
- V6 : same transverse level as V4, MAL
- V3R : corresponds to V3 on the Right side
- V4R : corresponds to V4 on the Right side
- V1, V2, V3R and V4R - R ventricular activity
- V3, V4 (transitional) - septal activity

V5, V6 - L ventricular activity

*Axis Calculation*



**Components of the Standard ECG**



A segment is a straight line connecting two waves, whereas an interval encompasses at least one wave plus the connecting straight line.

- P wave: This is the first wave seen. It is a small rounded upright (positive) wave indicating atrial depolarization (and contraction).
- PR interval: This is the distance between the beginning of P wave and beginning of QRS complex. It measures the time which a depolarization wave travels from the atria to the ventricles.
- QRS interval: Includes three deflections following the P wave and indicates ventricular depolarization and contraction. The Q wave is the first negative deflection, R wave is the first positive deflection and S wave is the first negative deflection after the R wave.

ST segment is the distance between S wave and the beginning of T wave. It measures the time between ven-

tricular depolarization and the beginning of repolarization.

T wave is a rounded upright (positive) wave following QRS, and represents ventricular repolarization.

QT interval is measured from the beginning of QRS to the end of the T wave. It represents total ventricular activity.

U wave is a small rounded, upright wave following T wave. It is most easily seen with a slow heart rate and represents repolarization of Purkinje fibres.

### Paediatric ECG

Proper interpretation of ECG relies on comparisons with standards derived from normal population. While ECG standards for normal adults have been firmly established, few studies are available for children. Many authors have demonstrated that these ECG standards could be influenced by age, sex, nutrition and race. Paediatric ECG is unique and also difficult to interpret in the neonatal period because of the rapid perinatal hemodynamic changes and the wide overlap of normal and abnormal values. Adequate analysis of the tracing requires a well-standardized recording technique (size and position of electrode and calibration). Information is particularly scarce for some of the leads frequently used in the newborn infants and young children (V4R, V3R and V7). In addition, data are often grouped together over relatively wide period of time. Most of the age related changes in paediatric ECG are related to the changes in the ratio of left ventricular (LV) to right ventricular (RV) weight. At birth, the right ventricle is thicker than the left ventricle, thus making a right axis deviation (LAD) a normal finding in the ECG of a term newborn. As the child grows, the normal RV dominance of the newborn period is gradually replaced by the LV dominance of the latter childhood and adult. There is a tremendous variation of the normal ECG at each age group. The ECG can diagnose many conditions and these can be inferred from measurement of various intervals or specific patterns. However, ECG could be normal in a child with a cardiac disease and abnormal in a perfectly normal heart. Therefore, electrocardiogram should be correlated with history, physical examination, radiographs and echocardiograph of the heart and should only be rarely used to diagnose cardiac disease outside this context.

In the standard ECG recording:

Paper speed = 25mm/sec  
 1 small square (horizontal) = 0.04 sec  
 1 large square (horizontal) = 0.2 sec  
 10mm (vertical) = 1 mV

After the recording has been made, each strip of the electrocardiograph should be analyzed for each of the following: Rate, rhythm, P waves, PR Interval, QRS Axis, QRS morphology, QT interval, T wave, U wave, ST Segment, and RS progression

**Rate:** This is age dependent faster at 1/12 than at birth, gradually slowing with increasing age thereafter.

In calculating the rate, either:

- Divide 300 by the number of large squares in between R waves of successive beats OR
- Divide 1500 by the number of small squares in between R waves of successive beats OR
- Multiply the number of R-R cycles in 6 large squares (1.2 sec.) by 50. OR
- Multiply the number of R-R cycles between 2 markers on a rhythm strip (3 sec.) by 20.

### Rhythm: (the pace maker)

- Sinus: normal, tachycardia, bradycardia, arrhythmia.
- Junctional: accelerated, tachycardia, PJC.
- Atrial: flutter, fibrillation, paroxysmal supraventricular tachycardia (PSVT), Parox-A-T, Wolff-Parkinson-White syndrome
- Ventricular: tachycardia, fibrillation, torsade de pointes, premature ventricular contraction (PVC).
- Pace maker rhythm: Atrial or ventricular.

### P waves

- Normal P wave: < 2.5mm in height (at normal standardisation) ie 0.25mv. < 0.10 sec in duration.
- Right atrial hypertrophy: P waves tall and peaked (>2.5mm high)
- Left atrial hypertrophy: P waves broad (>0.10 sec in duration), broad and flat topped, broad and notched (M-shaped) = P mitrale, broad and biphasic.
- COMBINE hypertrophy: there is tall and wide p wave.

### PR interval

- The normal interval is age and heart rate dependent. Usually
  - 0.07 - 0.12 sec in children under 1 year of age
  - 0.08 - 0.16 sec in children over 1 year of age
  - 0.10 - 0.18 sec in adolescents
  - 0.10 - 0.20 sec in adults Shortened in pre excitation syndromes, for example WPW syndrome (short PR interval, widened QRS interval, delta wave preceding the QRS complex)
- Prolonged in heart block
  - 1st degree heart block prolonged PR interval
  - 2nd degree heart block
  - -Mobitz type I (Wenckebach).
  - -Mobitz type II
  - 3rd degree (complete) heart block (Avdissociation)
- Variable in - wandering atrial pacemaker
  - -multi-focal atrial tachycardia

### Electrical axis of the heart

The electrical axis is the sum total of all electrical currents generated by the ventricular myocardium during

depolarization and its direction. It helps to determine the location and extent of cardiac injury, such as ventricular hypertrophy, bundle branch block, or changes in the position of the heart in the chest such as ascites. The direction of the QRS complex in leads I and aVF determines the axis quadrant in relation to the heart.

- Calculation using Leads I and aVF
  - Determine the value of R minus S in lead I - horizontal (x)
  - Determine R minus S in lead aVF - vertical (y)
  - Determine point of intersection (p) of perpendicular line drawn through x and y
  - Join P to centre and determine the value of the angle on standard graph paper.
- Calculation using successive approximation method
  - Use leads I and aVF to locate the quadrant of the axis.

I	aVF	Axis
Dominant R(+ve)	Dominant R (+ve)	00 to + 900
Dominant S (-ve)	Dominant R (+ve)	+900 to + 1800
Dominant S (-ve)	Dominant S (-ve)	+1800 to +2700
Dominant R (+ve)	Dominant S (-ve)	+2700 to + 3600

Determine lead with the most equiphasic RS wave or least voltage.

Axis is perpendicular to this lead within the quadrant located in leads I and aVF.

NB;    Lead I is perpendicular to Lead aVF  
           Lead II is perpendicular to Lead aVL  
           Lead III is perpendicular to Lead aVR.

OR

Determine the lead with the greatest R or S deflection in the quadrant located in (i). The mean QRS axis is close to the +ve or ve limb (respectively) of that lead.

Abnormalities in electrical axis may give an indication as to the presence of structural defects for example:

Right axis deviation- Tetralogy of Fallot, pulmonary atresia, transposition of the great arteries (TGA).  
 Superior axis deviation- Atrioventricular septal defect, tricuspid atresia.

### QRS Complex

The QRS complex represents ventricular depolarization and the normal duration 0.10 seconds or less. It is measured from the beginning of the Q to the end of the S deflection.

*General considerations:*

- R/S ratio large in right precordial leads (RPLs) and small in the left precordial leads (LPLs) in normal infants and small children (tall R in RPLs and deep S in LPLs).
- Normal Q waves are narrow < 5mm in LPLs & aVF (may be up to 8mm in lead III in children aged <3yrs).

- Q waves normally absent in RPLs.
- Deep Q in LPLs in ventricular hypertrophy of volume overload type
- Deep and wide Q in myocardial infarction and myocardial fibrosis
- Q waves in V1 in severe right ventricular hypertrophy (RVH), ventricular inversion (L-TGA) single ventricle, occasionally in newborns.
- Absent Q in V6 may be seen in LBBB & ventricular inversion.

### QRS Morphology

Leads V<sub>1</sub>, V<sub>2</sub>, V<sub>4R</sub> - right ventricle activity

Leads V<sub>3</sub>, V<sub>4</sub> (transitional) - septal activity

Leads V<sub>5</sub>, V<sub>6</sub> - left ventricle activity

### Q wave

Represent septal depolarization wave from left to right. It normally presents in LV leads as a negative wave, and absent in RV leads. The normal duration is 0.08sec. Normal depth should not exceed 5mm in LV leads.

Q wave presence in RV leads can be due to: Left bundle branch block, ischemia, severe RVH, right sided endomyocardial fibrosis (EMF), congenitally corrected TGA in which Q is absent in LV leads, premature ventricular contraction, ventricular tachycardia and ischemia.

### Criteria for RVH

- S in lead I,  $\geq 12\text{mm}$  - R in aVR,  $\geq 8\text{mm}$
- Pure R (no S) in V1 > 10mm - R in V1  $\geq 25\text{mm}$
- A qR pattern in V1 - Upright T in V1 > 3days + upright T in V6 RAD > 1800

### Voltage criteria:

RVH = R in V<sub>4R</sub> >15mm in children aged <3 months  
 >10mm in children aged >3 months

### Criteria for LVH

- LAD for patient's age - R in I, II & III, aVL, aVF, V<sub>5</sub> or V<sub>6</sub> > normal
- S in V1 or V2 > upper limit for age. - Abnormal R/S in favour of LV
- Q in V<sub>5</sub> & V<sub>6</sub> > 5mm with tall symmetric T wave
- Wide QRS-T angle in the presence of LVH inverted T in lead I or aVF.

### Voltage criteria:

LVH = R in V<sub>6</sub> >20mm in children <3 month  
 >25mm in children >3 months

### Combine Ventricular Hypertrophy

- Voltage criteria for RVH and LVH in absence of BBB or WPW syndrome
- Positive voltage criteria for RVH or LVH
- BVH = R + S in V<sub>3</sub> or V<sub>4</sub> >70mm

**RS progression pattern**

RV leads LV leads

- Neonatal pattern (up to 6/52) Dom R Dom S
- Infant pattern (6/52 - 18/12) Dom R Dom R
- Adult pattern (> 18/12) Dom S Dom R

An 'adult' pattern found in a neonate would suggest LVH, whereas an 'infant' pattern found in a child of five years would suggest RVH.

QRS amplitude may be reduced in - pericardial effusion, endomyocardial fibrosis (EMF), hypothyroidism

**T Waves**

- In LV leads, it is normally upright in all ages, but may be flattened in the neonatal period.
- In RV lead, it is upright at birth up to one week of life, become inverted till puberty, then upright for the rest of life.
- Presence of upright T waves in RV leads in a prepubertal patient over the age of one week suggests RVH.

**Normal height of T Waves**

	V5	V6
<1yr:	<11mm	<7mm
>1yr:	<14mm	<9mm

Tall, tented T waves - Causes include hyperkalaemia, LVH, early myocardial infarction, cerebrovascular accident (CVA).

Flattened/inverted T waves - Causes include myocardial disease, pericardial disease, LVH with myocardial strain, hypokalaemia, digitalis effect, hypothyroidism, and neonatal period

**ST Segment**

It is not more than 1-2mm above the isoelectric line.  
ST segment depression: can be caused by myocardial ischemia, left ventricular hypertrophy, intraventricular conduction defect, medications such as digitalis.

ST segment elevation: an elevation of 1 mm in the limb leads and 2 mm in the chest leads indicates an evolving acute myocardial infarction until proven otherwise. Other primary causes of ST segment elevation are early repolarization (normal variant in young adults), pericarditis, ventricular aneurysm, pulmonary embolism, and intracranial hemorrhage.

**QT Interval**

The QT interval varies with heart rate, but not with age (except in infancy) and must therefore be corrected for (QTc) using either a table, or Bazett's formula:

$$QTc = \frac{\text{Measured QT}}{\sqrt{RR \text{ interval}}}$$

QTc should not exceed 0.44 sec. except in infants. Up to 0.49 sec. may be normal in the first 6 months of life.

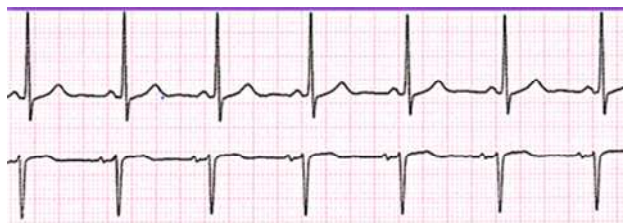**Prolonged** in- hypocalcaemia, myocarditis, myocardial disease, head injury; CVA, quinidine, procainamide or amiodorone therapy, Long QT syndrome such as Jervell and Lange-Nielsen Syndrome and Romano-Ward Syndrome.

**Shortened** in - hypercalcaemia, digitalis effect.0

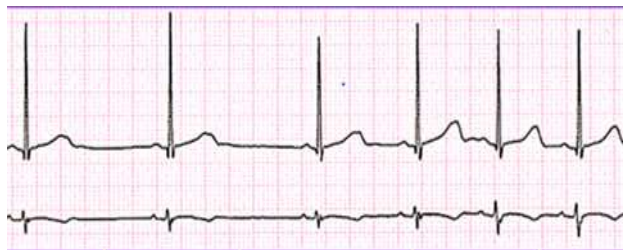Digitalis effect include shortening of QTc, sagging of ST segment, and slowing of heart rate while digoxin toxicity causes prolongation of PR interval, sinus bradycardia/ SA block, 2nd degree heart block, supraventricular arrhythmia, ventricular bigeminy/ trigeminy (rare in children), premature ventricular contractions, and ventricular tachycardia.

**ECG Strips For Practice**

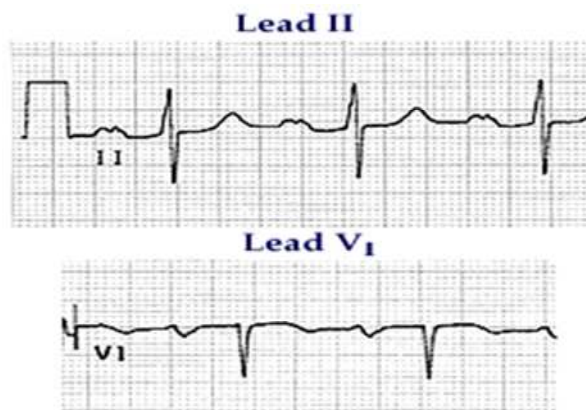
Normal sinus rhythm



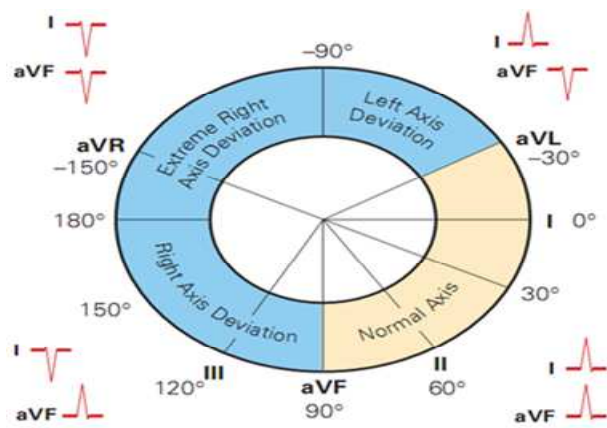
Sinus arrhythmia



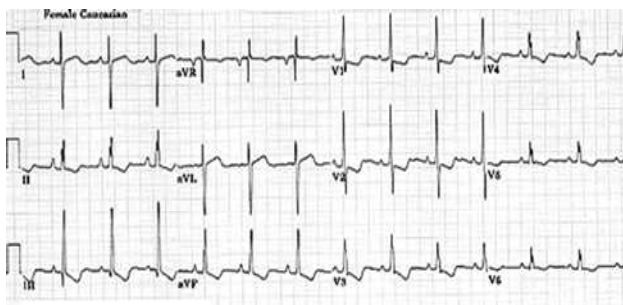
Left atrial hypertrophy



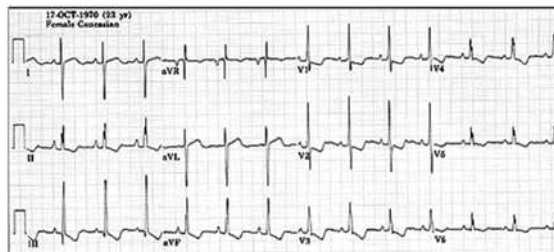## The electrical axis of the heart



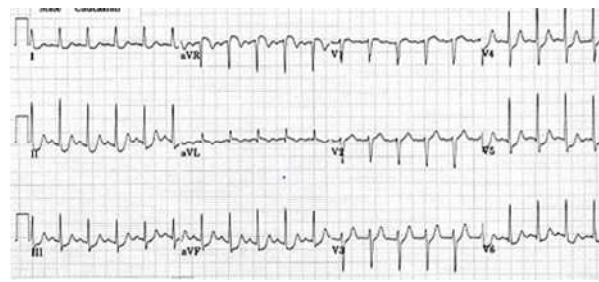
## Right axis deviation



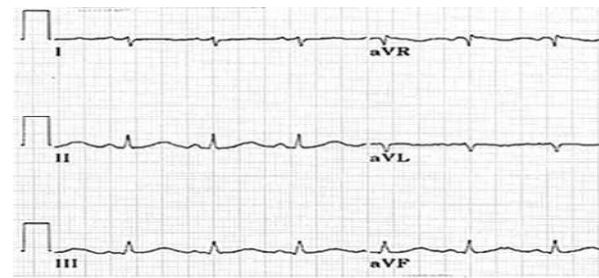
## Right ventricular hypertrophy



## ST depression



## Prolonged QT interval



Conflict of interest: none

Funding : none

## Acknowledgement

Reproduced with kind permission of the department of Paediatrics and Child Health of the University of Ilorin Teaching Hospital, Ilorin Nigeria owners of the Ilorin Paediatric Digest 2010.

## References

1. The Alan E. Lindsay ECG Learning Center in Cyberspace. Yanowitz FG. <http://library.med.utah.edu/kw/ecg/index.html>
2. Shinebourne, EA. Investigations: The Electrocardiogram. In: Shinebourne EA, Anderson RH, eds. Current Paediatric Cardiology. Oxford: Oxford 1980: 49-56.
3. Park MK and Guntheroth WG eds. How to Read Paediatric ECGs, 3rd edition Mosby 1992; 1-55.
4. Paediatric Cardiology for Medical Professionals. [Http://pediatriccardiology.uchicago.edu/MP/pcomedprof.htm](http://pediatriccardiology.uchicago.edu/MP/pcomedprof.htm)
5. Chugh SN. Physiological Mechanisms Governing Electrocardiographic Deflections in textbook of clinical electrocardiography; 2nd edition; Jaypee Brothers, new Delhi 2006; 1-40.