

Chinedu M Dike
Bashir O Oyeyemi

CC-BY



Transient bulging fontanelle following rotavirus vaccination: A case report

DOI:<http://dx.doi.org/10.4314/njp.v48i1.11>

Accepted: 2nd October 2020

Chinedu M Dike (✉)
Department of Medicine,
Niger Foundation Hospital,
5 Presidential close, Independence
Layout, Enugu.
Email: dike.michael@gmail.com

Bashir O Oyeyemi
Department of Paediatrics,
St. Nicholas Hospital, Lagos Island,
Lagos.

Abstract: Transient bulging fontanelle is a self-limiting clinical condition characterized by a bulging fontanelle with or without fever, which resolves without medical intervention. It is a relatively uncommon adverse event following immunization. We report a case of an 11 week old, otherwise healthy male infant who presented with a bulging, non-tense anterior fontanelle without fever, which developed 11 hours after receiving rotavirus vaccine. Transfontanelle ultrasound scan findings were essentially normal. Two days later, the bulging anterior fontanelle resolved spontane-

ously. The child had normal neurological development and achieved corresponding developmental milestones over the subsequent eight months of follow-up. This case report highlights the importance of immunization history in the otherwise healthy infant who presents with bulging fontanelle. We recommend that in an otherwise well recently vaccinated infant that presents with bulging anterior fontanelle, lumbar puncture should be deferred while the infant is closely monitored.

Key Words: bulging fontanelle, rotavirus, vaccine.

Introduction

A bulging anterior fontanelle typically occurs in the setting of raised intracranial pressure. Important differential diagnoses include: hydrocephalus, meningitis, encephalitis and tumour.¹

Transient bulging fontanelle (TBF) refers to a self-limiting clinical condition characterized by a bulging fontanelle with or without fever which resolves without medical intervention. The condition is classified as ‘definite’ if neuroimaging and cerebrospinal fluid (CSF) analysis are normal, in the absence of focal neurologic deficits or altered level of consciousness; and ‘probable’ if neuroimaging or CSF analysis or both were not done, but all other criteria were met. In any case, follow-up data must reveal normal development.²

Adverse events following immunization (AEFI) is a well-known phenomenon, with fever being the most commonly reported.³ TBF following diphtheria-pertussis-tetanus (DPT) vaccinations have been reported from India and the United States.^{2,4-5} Some other researchers have reported TBF following administration of measles vaccine in India.⁶ However, we are not aware of any previous reports of TBF following isolated rotavirus vaccination.

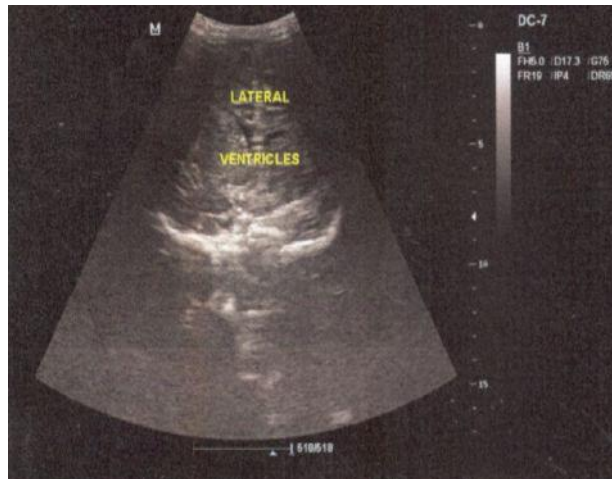
Case Report

An 11- week old male infant presented at the outpatient department of our hospital with a bulging anterior fontanelle without fever, which developed 11 hours after receiving rotavirus vaccine. He had previously received

other vaccines according the Nigerian National Program on Immunization (NPI) schedule,⁷ including an initial dose of rotavirus vaccine at six weeks, without complications. This second dose of rotavirus vaccine which was due at 10 weeks was administered six days later because the vaccine was not available on the appointed date.

Physical examination was normal, except for a bulging anterior fontanelle which was not tense. Anthropometric indices were within normal range for age and sex. Ratio of head circumference to chest circumference was 1:1. We did not see any need to perform invasive investigations such as lumbar puncture, nor expose the child to ionizing radiation of computed tomography scan since the child was otherwise healthy. However, we performed a transfontanelle ultrasound scan and the findings were within normal limits (Figure 1). We reassured the mother and allowed her home with her baby and told her to report back at the hospital if the symptom failed to resolve within three days or if her child developed a fever. Two days later, the bulging anterior fontanelle had resolved spontaneously. We associated the TBF with rotavirus vaccination, diagnosed as ‘probable’ because neither lumbar puncture, nor computed tomography was done.² The child had normal neurological development and achieved corresponding developmental milestones over the subsequent eight months of follow-up.

Fig 1: Transfontanelle sonogram (coronal section) of the patient showing normal findings



Discussion

We are not aware of any previous case report of TBF following isolated vaccination with rotavirus vaccine. Most of the previous reports of TBF have been sequel to isolated DPT vaccination, concomitant administration of DPT with other vaccines (including but not limited to rotavirus vaccine) or isolated measles vaccination.^{2,4-6} Our patient was 2.75 months/ 11 weeks old, and the bulging fontanelle developed 11 hours after rotavirus vaccination, in the absence of fever. In the largest case series to date of patients with TBF after vaccinations, involving eighteen (18) infants, the age at presentation ranged from 2.7 to 6.5 months (median=4.5 months); the time of onset of TBF after vaccination varied from five hours to four days (median= 18 hours), fever was also reported in 83% (15 infants) of the cases.² In a case report of TBF following measles vaccination in India, the 9-month-old female infant presented with fever and three episodes of vomiting 10 hours after vaccination.⁶ Our patient was afebrile with normal neurological evaluation. We did not see any need to perform invasive investigations such as lumbar puncture, or a need to expose the child to ionizing radiation of computed tomography scan. The transfontanelle ultrasound scan was normal. The omission of lumbar puncture for CSF analysis makes ours a 'probable TBF' according to the diagnostic criteria proposed by Freedman *et al.*² Bacterial meningitis was identified to be the cause of bulging fontanelle in only one out of 153 febrile infants with bulging anterior fontanelle included in a study in Israel.⁸ Therefore, the presence of a bulging anterior fontanelle in an afebrile, otherwise normal, fully vaccinated infant may not be considered a sufficient indication for an immediate lumbar puncture.

Lumbar puncture, though invasive, was more readily done than neuroimaging in previous reports.^{2,4,6} This is probably due to the fact that most of the cases presented with fever there by putting meningitis higher up in the

list of differential diagnoses. In addition, neuroimaging is relatively more expensive than lumbar puncture. Nevertheless, in all reported cases of TBF after vaccination, CSF analysis and neuroimaging revealed normal findings.

In the case series referred to earlier, antibiotics were administered to only 22% of the patients in the study group, despite the fact that 83% of them presented with fever.² In another case series involving nine (9) patients with TBF following vaccination, antibiotic treatment was commenced empirically for most of the cases (67%) for a period of three days, while awaiting negative CSF cultures.⁴ We did not initiate antibiotic therapy in our patient because he was afebrile and otherwise healthy. Some studies in developing countries have demonstrated that bulging anterior fontanelle could be due to hypervitaminosis A.^{2,4,6,8-9} Other afebrile conditions that can result in bulging fontanelle include hydrocephalus, intracranial haemorrhage and hypoxic-ischaemic injury.^{8,10} The child had not yet received Vitamin A supplementation, his head circumference has remained normal and he had no adverse perinatal factors to support any of these other conditions as a cause of his TBF.

Time to resolution of signs and symptoms from previous reports varied between 1- 7 days, with majority of the cases resolving in less than 3 days. Follow-up interval after vaccination from previous reports ranged from two months to 5.5 years.^{2,4-6} In our case, the bulging anterior fontanelle resolved spontaneously within two days and remained normal on follow-up after eight months.

Conclusion

TBF following vaccination remains a diagnosis of exclusion and other causes of bulging fontanelle must be considered first. This case report highlights the importance of immunization history in all infants. We recommend that in an afebrile, recently vaccinated, otherwise normal infant that presents with bulging anterior fontanelle, TBF should be considered and lumbar puncture should be delayed while the infant is closely monitored.

Authors' Contribution

Dike CM initiated the case report and both authors wrote and reviewed the manuscript and the literature search.

Conflict of Interest: None

Funding: None

Acknowledgment

We thank the Clinical Director of St. Nicholas Hospital, Lagos, Dr. Egun Bamgboye for his unrelenting support and for sharing pearls of wisdom with us.

References

1. Aliyu I. Transient bulging of the anterior fontanel. *Arch Med Health Sci* 2018;6:265-6.
2. Freedman SB, Reed J, Burwen DR, Wise RP, Weiss A, Ball R. Transient Bulging Fontanelle after Vaccination: Case Report and Review of the Vaccine Adverse Event Reporting System. *J Pediatr* 2005;147:640-4.
3. Ekwueme OC. Adverse events following immunization: Knowledge and experience of mothers in immunization centres in Enugu State, Nigeria. *Int J Med Health Dev* 2009;14:77-83.
4. Gross TP, Milstien JB, Kuritsky JN. Bulging fontanelle after immunization with diphtheria-tetanus-pertussis vaccine and diphtheria-tetanus vaccine. *J Pediatr* 1989;114:423-5.
5. Raju SS, Chacko B. Transient bulging fontanelle after measles vaccination. *Indian Pediatr*. 2014;51:673.
6. Chaturvedi P, Bannerjee KS, Gawdi A. Bulging anterior fontanel after DPT vaccination. *Indian J Pediatr* 1994;61:111-2.
7. Chido-Amajuoyi OG, Wonodi C, Mantey D, Perez A, Mcalister A. Prevalence and correlates of never vaccinated Nigerian children, aged 1–5 years. *Vaccine* 2018;36:6953-6960.
8. Shacham S, Kozer E, Bahat H, Mordish Y, Goldman M. Bulging fontanelle in febrile infants: is lumbar puncture mandatory? *Arch Dis Child* 2009;94:690–2.
9. Baqui AH, de Francisco A, Arifeen SE, Siddique AK, Sack RB. Bulging fontanelle after supplementation with 25,000 IU of vitamin A in infancy using immunization contacts. *Acta Paediatr* 1995;84:863-6.
10. Eze KC, Enukegwu, SU. Transfontanelle ultrasonography of infant brain: analysis of findings in 114 patients in Benin City, Nigeria. *Niger J Clin Pract*. 2010;13:179-182.