

Ahmed P
Wey YO
Uno MG

Alagille syndrome in an eleven year old Nigerian child – A case report

DOI:<http://dx.doi.org/10.4314/njp.v44i1.7>

Accepted: 8th November 2016

Ahmed P (✉)
Wey YO, Uno MG
Department of Paediatrics,
National Hospital Abuja, Nigeria
Email: ahmedpatience@yahoo.com

Abstract: *Background* Alagille syndrome (AGS) is a rare cause of prolonged jaundice. It has an autosomal dominant inheritance pattern expressed variably, with a reported incidence of 1:100,000 live births in the United States. The objective is to highlight the clinical features and diagnostic challenges to this rare cause of cholestatic jaundice.

Case Report: T.O, Female 11 years, had a history of recurrent episodes of yellowness of the eyes, first noticed soon after birth, associated with pale stools, dark urine, and body itching. From age three she was noticed to have progressive loss of sight, recurrent body swellings and irrational talks. She was diagnosed to have a cardiac murmur at age six, when diagnosis of ALS was made due to features of, recurrent jaundice and peculiar facies of broad fore-

head, flat nasal bridge, prognathia and genetic report of no mutation in JAG 1 gene, karyotype 46XX. At the time of current hospital admission she was in addition small for age, had hepatosplenomegy, ascities and talked irrationally. Chest radiograph showed multiple butterfly vertebrae; Echocardiograph aortic and pulmonary stenosis; Liver aminotransferase were marked elevated. Brain MRI showed multiple chronic infarcts. She was diagnosed with Allagille syndrome presenting in hepatic failure with encephalopathy.

Conclusion: Allagille syndrome should be considered early in older children with persistent cholestatic jaundice.

Key words: Allagille, syndrome, cholestatic, jaundice, hepatic encephalopathy and congenital heart disease.

Introduction

Alagille syndrome is a complex hereditary disorder that is associated with cardiac, hepatic, skeletal, ocular, renal and facial abnormalities first reported by Alagille et al. in 1969.¹ Peculiar facie, chronic cholestasis, posterior embryotoxon, butterfly like vertebral arch and peripheral pulmonary artery stenosis are the main features that characterize syndromic paucity of interlobular bile duct.^{2,3,4} Common facial features include broadened forehead, pointed chin, and elongated nose with bulbous tip, which may not be obvious during infancy but may become more apparent as the child ages. The ocular abnormalities⁵ of posterior embryotoxon, an opaque ring present in the cornea, were seen in about 75percent of patients reported in one large series conducted by Emerick et al.⁶ Other ophthalmologic findings reported include retinitis pigmentosa, pupillary abnormalities, and anomalies of the optic disc.

Alagille syndrome is an autosomal dominant disorder with variable expression. Mild-to-moderate mental retardation may also be present. Most cases of Alagille syndrome are caused by a mutation in the *JAGGED1*

(*JAG1*) gene; with less than one percent of cases resulting in a mutation in the notch-2 (*NOTCH2*) gene as the cause.^{7,8,9} The *JAG1* gene provides instructions for making a protein called Jagged-1, which is involved in an important pathway by which cells can signal to each other. The Jagged-1 protein is inserted into the membranes of certain cells, connected with other proteins called Notch receptors, which are bound to the membranes of adjacent cells. These proteins fit together like a lock and it's key. When a connection is made between the Jagged-1 and Notch proteins, it launches a series of signaling reactions (Notch signaling) that affects cell functions.^{8,9} Notch signaling controls how certain types of cells develop in a growing embryo, especially cells destined to be part of the heart, liver, eyes, ears, and spinal column. The Jagged-1 protein continues to play a role throughout life in the development of new blood cells. The *NOTCH2* gene provides instructions for making a protein called Notch2, a member of the Notch family of receptors. The lack of *Notch* signaling causes errors in development that result in missing or narrowed bile ducts in the liver, heart defects, distinctive facial features, and changes in other parts of the body. People with *JAG1* gene mutations may have one or more of

these problems. The syndrome has been mapped to the chromosome 20 (20p12-jagged-1 locus) *JAG1*.^{8,9} A minority (6-7percent) of patients have complete deletion of *JAG1*, and approximately 15-50percent of mutations are spontaneous.^{10,11} In the United State, reported incidence rate is approximately one case in every 100,000 live births.¹² Alagille syndrome is the fourth leading indication for liver transplant.¹³ The first reported case in Nigeria was by Akinyinka et al in 1998.¹⁴

The objective of this case report is therefore to highlight the clinical features and diagnostic challenges of this rare cause of cholestatic jaundice.

Case Report

T.O, a female presented at age of 11 years with a history of recurrent yellowness of the eyes since birth, progressive loss of sight and recurrent body swelling of over 5years, reversal of sleep and irrational talk of a month duration.

Jaundice was noticed on the first day of life and this was present most days with only few days jaundice free in between episodes. It progressively deepened with associated passage of pale stools and dark urine. There was associated body itching and generalized whitish body rash in early childhood. At about age 3, she was noticed to have been bumping into objects from gradual loss of sight. This led to her withdrawal from formal school to a school for the blind. She had a fall about this time and sustained a fracture of her left femur and was subsequently home schooled. The body swelling involved the lower limbs and abdomen mainly. She was seen at various hospitals and treated for the yellow eyes and body swellings with several medications that included ursodil 750mg twice daily to reduce itching. She was reviewed by an ophthalmologist for her poor vision and treated for the pathological fracture by the orthopedic surgeon. Because of heart murmurs she was diagnosed to have ventricular septal defect (VSD) at 8months and at 6years with aortic and pulmonary stenosis following echocardiography evaluation and had surgery in India. With the combinations of clinical features of cholestatic jaundice, visual impairment, cardiac lesions and genetic testing, she was diagnosed to have Allagille syndrome at the age of 6years old. Her karyotype was 46XX, and genetic analysis showed no mutation in *JAG 1* gene.

Her pregnancy and delivery was supervised and mother well except for a history of polyhydramnios in the 3rd trimester. Birth weight was 2.4kg and immunization was completed according to the National programme of immunization guideline. She had delay in walking until 2years old and eruption of teeth. She is the second of four children in a monogamous non-consanguineous marriage; other children alive and well. Father is a 49years old lawyer; mother is a 39years old caterer with tertiary level of education with no family history of a similar illness.

She presented to our health centre at age 11years with deepening jaundice, increasing body swelling, reversal of sleep and irrational talk of one month duration. Pro-

longed bleeding was noticed from puncture site, with epistaxis while on admission. She had a history of poor growth when compared to her other sibs. She was found to be small for age, ill looking and deeply icteric (greenish tinge), with sparse fluffy hair, broad forehead, flat nasal bridge and prognathia (fig 1 and 2). She had poor oral hygiene with a cross bite dentition. She was, pale, acyanosed, afebrile, with digital clubbing of grade 3 and bilateral pitting edema up to the knees. She had neck retraction, thin long limbs, broad wrist and elbow joint with rachitic rosary, genu valgum. She was drowsy with irrational talks had neck stiffness and increased muscle tone. Eye examination showed bilateral optic atrophy. Her precordium was hyperactive with a palpable thrill; normal first and second heart sounds with a grade 4 pansystolic murmur loudest at the left upper sternal border radiating to the axilla and root of the neck. Her abdomen was distended with prominent abdominal veins, tense generalized vague tenderness with moderate ascites. The diagnosis was Alagille syndrome with hepatic failure and encephalopathy.

Her chest radiograph revealed multiple butterfly vertebrae (fig 3) and brain magnetic resonance imaging (MRI) multiple chronic infarcts involving the right parietal lobe and the basal ganglia (fig 4). Laboratory investigations revealed deranged liver function test with an 8-fold increase aspartate aminotransferase (AST), a 2-fold rise alanine aminotransferase (ALT) and Gamma glutamyltranspeptidase (GGT), a 9-fold rise Alkaline phosphatase (AP); prolonged prothrombin time (PT) and partial thromboplastin time (PTT), and abnormal international normalization ration (INR); decreased serum proteins and albumin. Viral serology markers; namely hepatitis B surface antigen (HBsAg) or anti-HBV core (anti-HBC) for hepatitis B infection and Hepatitis C virus (HCV), anti- HCV for hepatitis C infection and HIV screening were negative. Others were hypokalemia, hypocalcemia, hypophosphatemia, and thrombocytopenia. She had intravenous unasyn, oral neomycin and lactulose and other supportive care. Parents were counseled on need for liver transplant. By the second week of admission patient deteriorated and became comatose and was bleeding from the nose and puncture sites and died subsequently.

Fig 1: Showing fluffy hair, deep jaundice, flat nasal bridge, broad nose



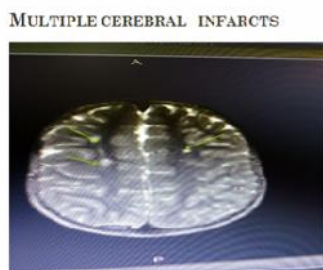
Fig 2: Showing broad forehead and nose, with flat nasal bridge, widely spaced eyes



Fig 3: Showing multiple butterfly vertebrae

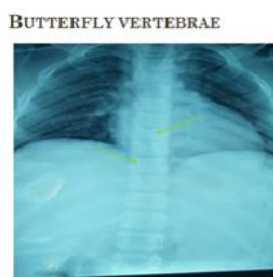

Fig 4: Showing multiple cerebral infarcts



Discussion

The case report was diagnosed Alagille syndrome (ALGS) with hepatic failure and encephalopathy, an autosomal dominant multi-system disorder affecting several body systems based on clinical presentation. The case report did not have JAG1 mutation, hence the possibility of Notch 2 mutation. However, the typical clinically consistent features of the syndrome has mutation in JAG1 in up to 94percent of cases, with a small 2percent having a mutation in NOTCH2.^{8,9} Some reports have shown that over half of individuals with mutations in the gene did not inherit it from either parent, and thus have a de novo mutation.^{8,9,15}

This case report had the constellation of five main symptoms consistent with ALGS,^{2,3,4} namely chronic cholestasis characterized by the paucity of intrahepatic bile ducts, congenital cardiac anomaly involving pulmonary stenosis, butterfly-like vertebral abnormalities, ocular changes of posterior embryotoxon, and peculiar facial abnormalities (broad forehead, deep-set and widely spaced eyes, small pointed chin, and saddle or straight nose). The case report was diagnosed at about 6 years of age after several hospital visits. The diversity of symptoms and lack of routine genetic analysis may have contributed to the delay diagnosis. In the case reported by Akinyinka et al,¹⁴ the characteristic facial features suggestive of Alagille syndrome and the clinical and echocardiological evidence of pulmonary stenosis were first observed when the child was 58 months. Because of the diverse clinical features, diagnosis may be delayed until established by age 4-5, which may explain why our case report was diagnosed at age 6 after several hospital

consultations. Another report showed that affected children were evaluated when younger than 6 months for either neonatal jaundice (70percent), or cardiac murmurs and symptoms (17percent).¹²

The case report had sub optimal growth with smallness for age, fluffy hair changes and body swelling with low proteins and albumin levels as features of chronic liver disease. Sub optimal growth has been documented¹² as a consequence of Alagille syndrome. The history of fall and fractures could have been associated with presence of rickets with other skeletal abnormalities. This case report had rickety rosary chest and ribs cage, hypoplastic enamel teeth, butterfly hemivertebrae and low serum calcium and phosphate. Vitamin D levels could not be determined. Emerick et al⁶ in a large series of patients with Alagille syndrome reported the presence of butterfly hemivertebrae in half of the patients analyzed. Visual loss from optic atrophy seen in this case has been reported as part of a posterior embryotoxon, which was observed in more than 75percent of patients in one large series conducted by Emerick et al.⁶

Treatment is usually supportive and some would require liver transplant. As at 2010 ALGS has been reported as fourth most common cause of liver transplantation in children.⁷ The case report died as a young adolescent after 15 days on admission. The presence of significant co-morbidities, that include cardiac malformation, cholestatic liver disease and vascular brain lesions seen in this case have been reported as some of the leading causes of morbidity in patients with ALGS.^{10,12}

A 20 years predicted life expectancy in 75percent for all ALGS patients, 80percent for those not requiring liver transplantation, and 60percent for those who required liver transplantation was reported by Emerick, *et al.*⁶ The case report lived up to young adolescent age before death with the several morbidities. She did not have the benefit of transplantation. Of the 41 cases in the Korean report, eight patients died after a median period of 2.67 years (range, 0.33-15 years) and those with combined severe liver and heart disease had the poorest survival ($P < 0.001$).¹⁶

ALGS could be differentiated from other rare conditions that present as cholestatic liver disease from its syndrome clinical features, laboratory tests and imaging studies.

Conclusion

Alagille syndrome is a rare syndrome, presenting as cholestatic liver disease, with peculiar features. Multidisciplinary approach in management is required and survival depends on severity of associated morbidities and available transplant facilities care.

Reference

1. Alagille D, Habib EC, Thomassin N. L'atresie des voiesbiliairesintra-hepatiques avec voiesbiliairesex-trahepatiquespermeables chez l'enfant. Paris: Editions medicales-flammarion; 1969. pp. 301–318.
2. Alagille, D., Odievre, M., Gautier, M., Dommergues, J.P. Hepatic ductular hypoplasia associated with characteristic facies, vertebral malformations, retarded physical, mental and sexual development, and cardiac murmur. *J. Pediatr* 1975; 86, 63–71.
3. Watson GH, Miller V. Arterio-hepatic dysplasia: familial pulmonary arterial stenosis with neonatal liver disease. *Arch Dis Child*. 1973; 48:459–466.
4. Kamath BM, Loomes KM, Oakey RJ, Emerick KE, Conversano T, Spinner NB, et al. Facial features in Alagille syndrome: specific or cholestasis facies? *Am J Med Genet*. 2002; 112:163–170.
5. Hingorani M, Nischal KK, Davies A, et al. Ocular abnormalities in Alagille syndrome. *Ophthalmology*. 1999; 106(2):330-7.
6. Emerick KM, Rand EB, Goldmuntz E, Krantz ID, Spinner NB, Piccoli DA. Features of Alagille syndrome in 92 patients: frequency and relation to prognosis. *Hepatology*. 1999;29(3):822-9.
7. Kamath BM, Bauer RC, Loomes KM, Chao G, Gerfen J, Hutchinson A et al. *NOTCH2* mutations in Alagille syndrome. *J Med Genet*. 2012; 49(2):138–144.
8. Mc Daniell R, Warthen DM, Sanchez-Lara PA, Pai A, Krantz ID, Piccoli DA, et al. *NOTCH2* mutations causes Alagille syndrome, a heterogeneous disorder of the notch signaling pathway. *Am J Hum Genet*. 2006; 79(1):169-73.
9. Li L, Krantz ID, Deng Y, Genin A, Banta AB, Collins CC, Qi M, et al. Alagille syndrome is caused by mutations in human *Jagged1*, which encodes a ligand for Notch1. *Nat Genet*. 1997;16 (3):243-51.
10. Turnpenny P.D, Ellard S. Alagille syndrome: Pathogenesis, diagnosis and management. *Eur J Hum Genet* 2012; 20: 251-257.
11. Oda T, Elkahoun AG, Pike BL, Okajima K, Krantz ID, Genin A, Piccoli DA, et al. "Mutations in the human *Jagged1* gene are responsible for Alagille syndrome". *Nat. Genet*. 1997; 16 (3): 235–42.
12. Ann Scheimann: *Alagillesyndrome* : Background, Pathophysiology, Epidemiology. *medscape.com/article/926678-overview.Alagille syndrome (AS)*. Accessed August 8 2016.
13. Vázquez-Martínez ER, Varela-Fascinetto G, García-Delgado C, Rodríguez-Espino BA, Sánchez-Boiso A, Valencia-Mayoral P, et al. Polymorphism analysis and new *JAG1* gene mutations of Alagille syndrome in Mexican population. *Meta Gene* 2014; 2:32-40. Available from: <https://www.researchgate.net/publication/267456490>_ Accessed Feb 8, 2016.
14. Akinyinka OO, Akang EEU, Agbeja-Baiyerolu, Osifo BOA, Thurham D. Syndromatic Hepatic ductular hypoplasia (Alagille syndrome) in a Nigerian child - A case report. *Nig. J. Paed* 1998; 25: (2-4), 68-72.
15. Krantz ID, Colliton RP, Genin A, Rand EB, Li L, Piccoli DA, Spinner NB. "Spectrum and frequency of jagged1 (*JAG1*) mutations in Alagille syndrome patients and their families". *Am. J. Hum. Genet* 1998; 62 (6): 1361–9.
16. Ahn KJ, Yoon Jk, Kim GB, Kwon BS, Go JM, Moon JS, et al. Alagille syndrome and a *JAG1* mutation: 41 cases of experience at a single center. *Korean J Pediatr*. 2015; 58(10): 392–397.