

Eke GK
Omunakwe HE
Echem RC

Hereditary multiple exostoses in a 15-year-old boy: A case report and review of literature

DOI:<http://dx.doi.org/10.4314/njp.v43i4.12>

Accepted: 6th September 2016

Eke GK (✉)
Department of Paediatrics,

Omunakwe HE
Department of Haematology

Echem RC
Department of Orthopaedics,
University of Port Harcourt Teaching
Hospital, Port Harcourt, Rivers State,
Nigeria.
Email: kergracia@yahoo.com

Abstract: *Background:* Hereditary Multiple Exostoses (HME) is a rare bone disease, usually associated with deformity and pressure symptoms. It is an autosomal dominant disorder characterized by the development of benign tumours growing outward from the metaphyses of long bones and can lead to considerable psychosocial problems. This paper aims at reporting a case of HME with some peculiar features.

Methods: A case report of a 15-year-old Nigerian male with Hereditary Multiple Exostoses is presented to highlight the clinical, radiological features and management challenges of the condition.

Results: The patient presented with multiple hard, bony and ridge-like growth along the spine, scapula and para-vertebral region which gradually increased in size.

These swellings were non-tender, not attached to the overlying skin and immobile, had no differential warmth and appeared to be continuous with the underlying bony structures. A striking feature was exostoses that extended from the lumbar spine towards the left scapula. He also had brachymetatarsia of the first ray of both feet. Skeletal survey confirmed the diagnosis. *Conclusion:* Though rare, HME do occur in our environment. The treatment is individualized, with small asymptomatic or minimally symptomatic lesions followed up and only supportive care provided. Larger symptomatic lesions may cause major physical handicap and may be resected.

Key words: Hereditary, Multiple, Exostoses, Deformity

Introduction

Osteochondroma, the most common bone tumour seen in children, is a developmental lesion rather than a true neoplasm and constitutes 20%–50% of all benign bone tumours.¹ It is a cartilage-capped exostosis found primarily at the juxta-epiphyseal region of the most rapidly growing ends of long bones.² Hereditary Multiple Exostosis (HME), also known as diaphyseal aclasia and multiple osteochondromatosis, is characterized by the development of multiple osteochondromas (exostoses) and is frequently associated with characteristic progressive skeletal deformities.^{3–6} The disorder shows an autosomal dominant inheritance pattern with approximately two-thirds of affected individuals having a positive family history.¹ The earliest known description of an afflicted family was reported by Boyer in 1814.^{3,7}

The true prevalence of HME is not known since many patients with asymptomatic lesions are never diagnosed.³ However, its estimated prevalence is 1:50,000 to 1:100,000 in Western populations and may be as high as 1:1,000 in the Chamorros, the indigenous people of Guam and the Mariana Islands.^{1,8} Although previously thought to have a male predominance, HME now appears to affect both sexes similarly.^{3,9}

It manifests more in early childhood to puberty and 40% of the affected children manifest before the age of 10 years. Lesions have been infrequently reported to spontaneously regress during the course of childhood and puberty.^{3,10}

The commonest complications of this condition are deformity, pressure symptoms and malignant degeneration.^{1,3,4,5} Diagnosis is based on clinical examination and radiographic evaluation, while treatment of osteochondroma is individualized, depending on the presentation. In Nigeria, cases of HME have also been reported,^{11,12} affecting the lower and upper limbs while the index patient had in addition massive exostoses which extended from the lumbar spine towards the left scapula. This was not a common feature in cases reported in the literature. The aim of this paper is to report a case of hereditary multiple exostoses with some peculiar features.

Case report

K.V, a 15-year old Nigerian male was referred from a public secondary level health care facility and presented to the Children Out-patient Clinic of the University of Port Harcourt Teaching Hospital (UPTH) in Rivers State, Nigeria because of a 3-year history of multiple

swellings on the back.

These developed over his lower back along the midline and over the lateral and upper aspects of his back as multiple swellings which gradually increased in size and eventually coalesced in certain areas, causing a deformation of his back with difficulty in bending his trunk and inability to freely turn his head to both sides. He had mild pain when lying on his back. There was no preceding history of trauma and no other constitutional symptoms.

He had herbal concoctions with scarifications before presenting at the referral health facility for worsening of limitation of movements of the neck and trunk.

He was said to have developed similar swellings at 10 months of age over his trunk, no x-ray was done for confirmation, which lasted about 6 months and regressed spontaneously. However they re-occurred 3 years prior to presentation, when patient was 12 years old.

An average grade 7 student (JSS1), he had not attended school for the last 1 year because of worsening limitation of his movements. He is the last of 8 children, 5 alive, in a monogamous family setting. His mother was a farmer with no formal education, while his father died of a chronic illness 7 years prior to child's presentation. There was no history of similar illness in the family and they reside in an oil producing area of the Niger Delta region with petroleum exploratory activities and recurrent oil spillages in the community as well as past history of communal clashes with use of explosives and other local war artillery. Their source of drinking water is well water which is not boiled.

Physical examination revealed a withdrawn adolescent, in no obvious respiratory or painful distress. There was asymmetry of the pectoral girdle, marked left-sided scoliosis, neck stiffness with limited rotational movement of the head. Masses along the spine, scapula and paravertebral regions were multiple, hard, bony, rounded and ridge-like, some measuring up to 6x8cm, non-tender, not attached to the overlying skin and immobile, with no differential warmth, appearing to be continuous with the underlying bony structures (Fig1). There were also knob-like hard bony swellings over the lateral aspect of the upper one-third of the left leg with a similar protrusion over the right lateral maleoli. He had brachymetatarsia of the first ray of both feet (Fig1). There was no neurological deficit. His height was 156cm. Skeletal survey (Fig.2,3 and 4) confirmed the diagnosis of HME.

He was admitted for investigations and co-managed with the orthopedic surgeons, physiotherapist and social workers. Counselling was offered, excision of some of the exostoses especially those on the back was advised as well as genetic studies. However, he signed against medical advice, stating financial constraints as main reason, and had since been lost to follow up.

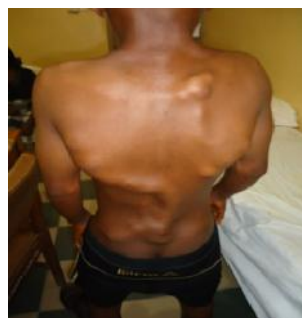

Fig 1a: Photograph of the patient's back

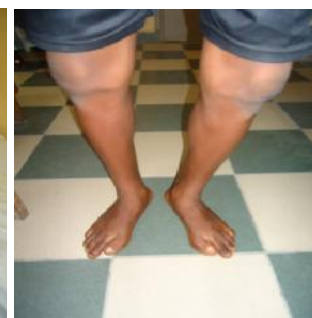

Fig 1b: Photograph of a closer view of the legs and feet

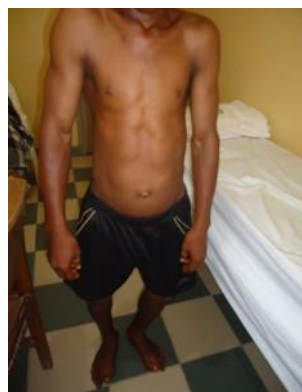

Fig 1c: Photograph of the patient

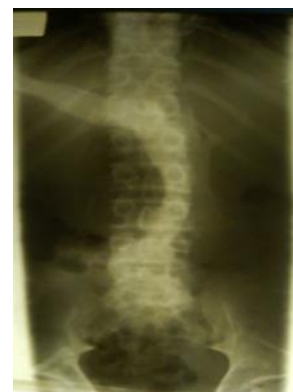

Fig 2: X-ray of thoracolumbar spine from the front

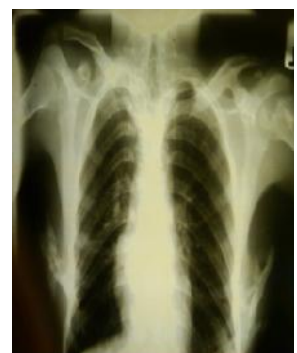

Fig 3: Chest X-ray showing exostoses from rib cage

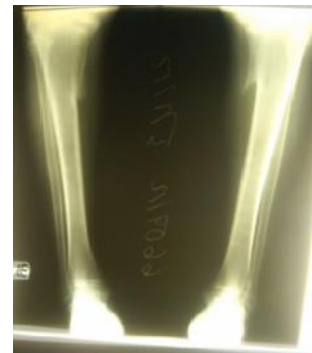


Fig 4: X-ray of both legs showing exostoses at the proximal tibia

Discussion

Hereditary Multiple Exostoses (HME) is a genetically heterogeneous disorder and has been associated with mutations in at least three different genes, termed EXT genes. At least two of these genes are thought to function as tumour suppressor genes.^{3,4,6} These mutations may disrupt normal cartilage growth, resulting in the formation of an osteochondroma.³ The three described EXT loci have been recently mapped: EXT1 on chromosome 8q23-q24, EXT2 on 11p11-p12, and EXT3 on chromosome 19p. According to linkage analysis, the EXT1 and EXT2 loci appear to be altered in the majority of families while, EXT3, which has not been fully isolated and characterized, is probably less frequently affected.^{3,4,6} Epidemiologic analysis of linkage and mu-

tation data indicate that mutations of EXT1 and EXT2 are likely to be responsible respectively for one half and one third of MHE cases. Genetic studies were however not conducted for the index patient.

Hereditary Multiple Exostoses is characterized by formation of ectopic, cartilage-capped, growth plate-like exostoses next to growing long bones and other skeletal elements. The exostoses usually originate proximal to an active growth plate, may occur at or after birth and throughout puberty, and may continue to grow slowly during adulthood.^{3,9,13} They form predominantly on the physes of long bones, pelvis, ribs, scapula, and vertebrae and begin to appear as early as 2 years of age.^{9,11,14} Most patients are diagnosed by age 5 years, and virtually all are diagnosed by age 12 years. In families with the genetic predisposition, members who do not demonstrate lesions by age 12 years will not manifest the disease. After adolescence and skeletal maturity, osteochondromas usually exhibit no further growth.¹

There is scarcity of reported cases of MHE in Nigeria. This may be because of under-reporting rather than non occurrence seeing that two reports of this rare autosomal dominant disorder were found. Yinusa *et al* reported 2 cases, a 13-year-old girl and a 9-year-old boy, who presented at an orthopaedic hospital within a six months period,¹¹ whilst Adelowo and Adebayo reported the disease in two siblings, both of whom are children of an achondroplastic father.¹²

Whereas all cases reported in Nigeria presented with clinical and radiological features of HME affecting the lower and upper limbs, the index case had in addition massive exostoses on the spine, scapulae and ribs (Fig. 1, Fig 2, Fig 3 and Fig 4). One of the peculiar features with this patient was the exostoses which extended from the lumbar spine towards the left scapula, an unusual feature in cases reported in the literature. We wonder if there could be any factors responsible for the elongation. This is a subject that will require further research.

Central exostoses involving the skull base, spine, or rib heads are seen in 1%–9% of patients with HME, and may cause cranial nerve deficits, radiculopathy, spinal stenosis, cauda equina syndrome, myelomalacia and spinal cord compression.^{1,15,16} Interestingly, in patients with HME, spinal lesions are usually solitary. The cervical spine is most frequently affected (50% of lesions), followed by the thoracic and the lumbar spine. Lesions that protrude dorsally from the posterior vertebral elements (lamina or spinous process) are typically large and manifest at an earlier age with cosmetic deformity and palpable mass but lack neurologic symptoms. In contradistinction, osteochondromas that extend into the spinal canal are often small but are associated with neurologic symptoms.¹ It is therefore not surprising that despite the considerable size of the spinal lesions causing limitation of range of flexion and extension of the trunk and significant deformity, the index patient had no neurological deficit. The fact that the deformity was on the back, usually covered with cloths, could account for

the late presentation. Osteochondromas that extend anteriorly from the vertebral body may produce symptoms of dysphagia, hoarseness, and vascular compromise.

Affected individuals may also show disturbance of growth with short stature, wrist and ankle deformity and mental handicap as had been reported by other workers^{9,17} but these features are variable and were not seen in the index case.

The index patient had a history of similar swellings around the trunk at the age of 10 months, which regressed spontaneously after about 6 months. Earliest lesions may even be present at birth as had been reported by Solomon.⁹ On the other hand, though uncommon phenomena, the pattern of spontaneous resolution, or appearance of new lesions years after excision of primary osteochondromas have been previously documented, but the literature is limited.^{10,18} Brachymetatarsia of the first ray of both feet were present in the index patient. The feet can be involved in HME as had been reported by other workers.^{8,9}

Complications commonly associated with these exophytic masses include cosmetic and osseous deformity, pressure symptoms, fracture, vascular compromise, neurologic sequelae, overlying bursa formation, and malignant transformation. Of these, outstanding complications in the index patient were cosmetic deformity, restricted joint movements affecting the vertebral joints, the upper and lower limbs and pain. This is of great concern as the patient was already out of school because of these complications, possibly facing physical, psychological and social distress which have a negative impact on his quality of life.

Malignant transformation has been reported, with documented risk of 1-6% in patients with HME in adulthood, with chondrosarcoma developing more frequently than osteosarcoma.^{1,3-5,8,9,17,19} Higher estimates of 10-25% have been cited but they have been a function of bias and incomplete detection of affected individuals who did not have a sarcoma but were members of a family that had exostoses.^{8,9} Lesions that grow or cause pain after skeletal maturity should be suspected of malignant transformation which is distinctly unusual before the age of 20. The index patient should therefore be kept under regular review both clinically and radiologically to evaluate progression of deformities and development of complications.

The diagnosis depends largely upon X-rays while the radiographic appearance of a lesion composed of bone demonstrating cortical and medullary continuity with the underlying parent bone is often pathognomonic.¹ Lesions that involve complex areas of anatomy (spine or pelvis) are frequently better assessed with CT or MR imaging to detect the characteristic marrow and cortical continuity.^{16,20} Bone scintigraphy has been demonstrated to be useful in the periodic surveillance of adult patients with HME.²¹ A biopsy should be done in doubtful cases and to help assessing malignant degeneration.¹⁹ Differential diagnosis include Dysplasia Epiphysealis Hemimelica (DEH) or Trevor's disease, which is

described as a type of over growth at one or more epiphyses, and metachondromatosis, a rare disorder that exhibit symptoms of both multiple osteochondromas and enchondromas in children and is also inherited in autosomal dominant mode.⁴

Treatment of HME is individualized and much more problematic and complex than that of patients with solitary osteochondromas. Small asymptomatic or minimally symptomatic lesions are followed up and only supportive care provided while larger symptomatic lesions may be resected. Thus, depending on the deformity, the surgical intervention may involve corrective osteotomy, epiphysiodesis, excision or limb lengthening.¹¹ Surgical treatment is often directed at correcting the associated deformities rather than restricted to the exostoses alone.¹ The surgeries may be multiple thus, the psychological effect on the patient should be considered. Genetic counselling is an important aspect of the management of HME as each individual is at 50% risk of

transmitting the disorder to his offspring.^{4,7,22}

Conclusion

Though rare, HME do occur in our environment. The treatment is individualized, with small asymptomatic or minimally symptomatic lesions followed up and only supportive care provided. Larger symptomatic lesions may cause major physical handicap and may be resected.

Introduction of palliative care and health insurance coverage for rare disorders of childhood are recommended to improve outcome.

Conflict of interest: None

Funding: None

References

- Murphey MD, Choi JJ, Kransdorf MJ, Flemming DJ, Gannon FH. Imaging of osteochondroma: variants and complications with radiologic-pathologic correlation. *Radiographics* 2000; 20 : 1407-1434.
- Peterson HA. Multiple hereditary osteochondromata. *Clin Orthop Relat Res* 1989; (239): 222-30.
- Stieber JR, Pierz KA, Dormans JP. Hereditary multiple exostoses: a current understanding of clinical and genetic advances. *University Pennsylvania Orthopaedic J* 2001; 14: 39-48.
- Bovee JV. Multiple osteochondromas. *Orphanet J Rare Dis* 2008; 3 :3.
- Richardson RR. Variants of exostosis of the bone in children. *Semin Roentgenol* 2005; 40:380-390.
- Pannier S, Legeai-Mallet L. Hereditary multiple exostoses and enchondromatosis. *Best Pract Res Clin Rheumatol* 2008; 22: 45-54.
- Hennekam RC. Hereditary multiple exostoses. *J Med Genet* 1991; 28: 262-266.
- Schmale GA, Conrad EU 3rd, Raskind WH. The natural history of hereditary multiple exostoses. *J Bone Joint Surg Am* 1994; 76: 986-992.
- Solomon L. Hereditary multiple exostosis. *J Bone Joint Surg Br* 1963; 45:292-304.
- Stitzman-Wengrowicz M, Pretell-Mazzini J, Dormans J, Davidson R. Regression of a sessile osteochondroma: A case study and review of the literature. *University Pennsylvania Orthopedic J* 2011; 21: 73-76
- Yinusa W, Owoola AM, Esin IA. Hereditary multiple exostosis: case report. *Niger J Clin Pract* 2010; 13: 218-222.
- Adelowo O, Adebayo S. Hereditary multiple exostoses in two Nigeria siblings. *BMJ Case Rep* 2009; 2009.pii:bcr09.2008.0901.
- Zak BM, Schuksz M, Koyama E, Mundy C, Wells DE, Yamaguchi Y. *et al.* Compound heterozygous loss of EXT1 and EXT2 is sufficient for formation of multiple exostoses in mouse ribs and long bones. *Bone* 2011; 48: 979-987.
- Roehl HH, Pacifici M. Shop talks: Sugars, bones, and a disease called multiple hereditary exostoses. *Dev Dyn* 2010; 239: 1901-1904.
- Labram E, Mohan J. Diaphyseal aclasis with spinal cord compression. Report of two cases and review of the literature. *J Neurosurg* 1996; 84: 518-521.
- Bess RS, Robbin MR, Bohlman HH. Spinal exostoses: analysis of twelve cases and review of the literature. *Spine* 1976 2005; 30: 774-780.
- Welsh GA, MacLeod I. Diaphyseal aclasis affecting the temporomandibular joint. *Dento maxilla fac Radiol* 1999; 28: 320- 323.
- Morton KS. On the question of recurrence of osteochondroma. *J Bone Joint Surg* 1964; 46: 723-725.
- Human L. Diaphyseal aclasis: Review of literature and report of an unusual case. *S Afr Med J* 1965; 39: 27-29.
- Vanhoenacker FM, Van Hul W, Wuyts W, Willems PJ, De Schepper AM. Hereditary multiple exostoses : from genetics to clinical syndrome and complications. *Eur J Radiol* 2001; 40: 208-217.
- Epstein DA, Levin EJ. Bone scintigraphy in hereditary multiple exostoses. *AJR Am J Roentgenol* 1978; 130: 331-333.
- Crandall BF, Field LL, Sparkes RS, Spence MA. Hereditary multiple exostoses. Report of a family. *Clin Orthop Relat Res* 1984; (190): 217-219.