

Mukhtar-yola M
Audu LI
Otuneye AT
Mairami AB
Otubelu EC
Kefas JG
Hamza N

Hypomelanosis of Ito: Case report of a rare neurocutaneous syndrome in a neonate and review of the literature.

DOI:<http://dx.doi.org/10.4314/njp.v42i3.12>

Accepted: 26th March 2015

Mukhtar-yola M (✉)
 Audu LI, Otuneye AT
 Mairami AB, Otubelu EC
 Kefas JG, Hamza N
 Department of Paediatrics,
 National Hospital Abuja,
 Nigeria.
 Email: mariyamukhtar@yahoo.com

Abstract: Hypomelanosis of Ito (HI) though said to be the third-most common neurocutaneous disorder, is rarely reported in paediatric practice in Africa. A high index of suspicion must be maintained in children with cutaneous lesions as a seizure may be the first symptom that may bring the

child to attention. A case of HI in a neonate is hereby reported to sensitize clinicians about this relatively uncommon disorder

Introduction

Case description

Hypomelanosis of Ito is characterized by presence of unilateral or bilateral whorls, streaks and patches of hypopigmented skin lesions and often associated with neurological and musculoskeletal manifestations. Ito first described it in 1951.¹ Its pathogenesis is strongly linked to genetics, as up to 52% may have some chromosomal abnormalities and familial cases have been reported.² It is a neurocutaneous disorder that occurs in 1 in 10,000 clinic visits.³ This report is meant to sensitize clinicians about this relatively uncommon syndrome since there is paucity of data in Nigeria.

Case presentation

Baby M. presented at the age of 20 hours with a history of seizures from the first hour of life and fever for 14 hours prior to presentation which was high grade and intermittent. Convulsions were initially focal involving the left side of the body with secondary generalization for 3-5 minutes. The infant remained conscious and alert during most episodes of convulsions. Baby had been on glucose water prior to transfer. She did not have any other constitutional symptoms.

She was delivered in a private hospital in Abuja to a Fulani mother who had a supervised pregnancy from 24 weeks of gestation. The Pregnancy was uneventful, mother's serological tests for HIV, HBsAg, VDRL and HCV were all negative though she was positive for cytomegalovirus and Herpes simplex IgG. She had no history of exposure to irradiation; no consumption of un-prescribed medications both orthodox and herbal. There

was no history of abnormal vaginal discharge, body rash, or fever. Mother is not a known hypertensive or diabetic and did not have gestational diabetes mellitus. Obstetric ultrasound scan done at 32 weeks gestation showed features of hydrocephalus.

Labour started spontaneous at 40/52 and was prolonged, necessitating an emergency caesarean delivery. Apgar scores were not documented in the referral notes. Father is a 44-year-old civil servant with secondary level of education; mother is a 35 year old housewife with tertiary level of education. Patient is the 6th of parents 6 children. The 3rd child, male, now aged 7years had a febrile seizures at 3years of age for which he was placed on carbamazepine for 2yrs with complete control of seizures and has been off anticonvulsant for 2 years now. He did not have any skin changes and there was no history of a similar disorder in other family members. The marriage is non consanguinous and they all reside in a two-bedroom apartment in the outskirts of Abuja.

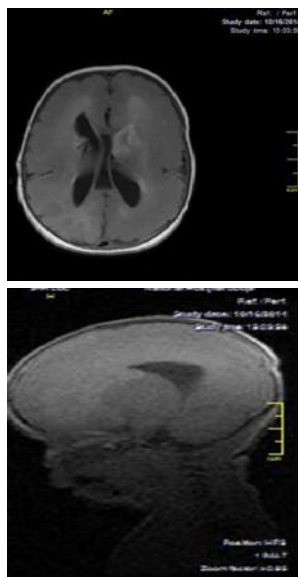
The baby was found to be floppy, in respiratory distress, and had a meconium stained cord and nasal secretions. The birth weight was 4.5kg, she was macrocephalic (OFC 41cm i.e 97TH centile), and left sided frontal bossing with wide anterior fontanelle measuring 8x 6cm. she also had right-sided hemihypertrophy and extra digits on her hands. The skin showed bilateral hypopigmentation with irregular borders occurring in whorls over the trunk and buttocks and as streaks over the limbs following the lines of Blaschko mostly on the right side of the body. (Fig. 1) The face, palm and soles of feet were spared. She convulsed more than 20 times a day. Systemic examination was essentially normal and there

were no eye changes as reported by the ophthalmologist. A diagnosis of Hypomelanosis of Ito with meconium aspiration syndrome was made. Her blood sugar remained normal throughout admission. The serum calcium was initially 1.76mmol/L and was corrected within 48hours. All other electrolytes were normal. Full blood count showed leukocytosis of $19.9 \times 10^9/L$, with neutrophils of 67%. The blood culture yielded no growth. An MRI of the brain revealed absence of sulci and gyri and absence of the frontal lobe of the right ventricle in place of which was a hamartoma that extended into the ventricle causing mild dilatation of the lateral ventricles. (See fig. 2) Chest x-ray and abdomino-pelvic ultrasound scan were essentially normal. For further evaluation, we planned a skin biopsy, EEG, Echocardiography and chromosomal studies but the parents did not consent. Patient was managed by a multidisciplinary team (paediatricians, dermatologist, ophthalmologist and cardiologist) and treated with supplemental Oxygen, intravenous fluids and intravenous antibiotics. For seizure control she was placed on titrated doses of phenobarbitone and eventually carbamazepine. Seizure control however remained poor, she is currently having regular neurologic and neurosurgical consults.

Fig 1: Skin showing hypopigmented streaks and whorls

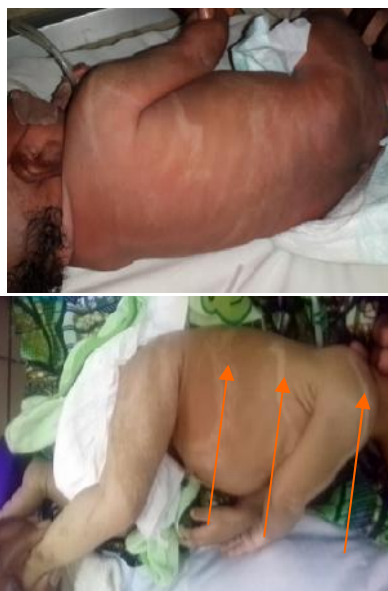

Fig 2: MRI Brain: showing absence of sulci and gyri, hamartoma in the frontal lobe



Discussion

Hypomelanosis of Ito (HI) is a sporadic neurocutaneous disorder characterized cutaneously by hypopigmented skin lesions arranged in whorls or streaks along the lines of Blaschko¹. The lines of Blaschko are relatively consistent and distinct from dermatomal lines. They represent lines of orderly migration of mesodermal and ectodermal precursors during embryogenesis¹. Though multisystem involvement is common, it is heterogenous in presentation and commonly manifests with involvement of the neurologic and musculoskeletal systems. Our patient had cutaneous, neurologic and musculoskeletal manifestations.

Minor Ito first described the syndrome in a 22yr old Japanese young lady in 1951¹. She presented with depigmented lesions on half of her body with no other extracutaneous manifestation except for asymmetry of the breast. Ito coined the name *nevus depigmentosus systematicus bilateralis* to refer to this condition. The occurrence of extra cutaneous manifestations of HI have been reported with varying frequencies; 30% by Nehal et al⁴ and nearly 100% by Ruiz- Maldonado et al². In 1967, Hamada et al confirmed the association between the skin lesions and systemic abnormalities, including mental retardation⁵. Pascal-Castroviejo et al delineated the full spectrum of associated neurological abnormalities in a systematic study of the largest series published³. Some diagnostic criteria for hypomelanosis of Ito syndrome were established in 1992². These criteria link the diagnosis to the presence of systemic non-dermatological (eg, CNS, skeletal) or chromosomal abnormalities. These criteria however excluded patients with only dermatological manifestations. Some researchers believe that hypomelanosis of Ito does not represent a distinct disorder but rather a symptom common to a group of disorders involving genetic mosaicism.

Epidemiological data on this syndrome is limited, It has an incidence of 1:10000 to 1:8000. In a pediatric neurology service in Spain, 1 in 600-700 patients referred was diagnosed with hypomelanosis of Ito syndrome. It is diagnosed in 1 of every 7,805 general pediatric outpatient visits, 1 of every 790 pediatric dermatology clinic visits, and 1 of every 2,983 children in a general pediatric service³. Approximately three quarters of the patients with typical skin lesions have systemic manifestations especially affecting the central nervous system⁵. Unlike *incontinentia pigmentata* that has a clear sex preponderance, HI is only slightly more common in females than males⁵ but the severity of systemic manifestations appears to be similar in both sexes. The incidence in Nigeria has not been reported from the best of our knowledge. Data in relation to age of diagnosis are usually reported in regard to the skin manifestations of HI syndrome. Typical skin lesions are initially demonstrated during the first year of life in as many as 70% of patients; they are noticeable at birth in 54% of patients and rarely, lesions are not visible until mid childhood⁶.

Patients with skin manifestations suggestive of hypomelanosis of Ito with and without systemic alterations have been described in the same family, demonstrating that hypomelanosis of Ito syndrome's systemic involvement can vary. Although hypomelanosis of Ito syndrome is most commonly a de novo occurrence, familial cases appear to be transmitted as an autosomal dominant trait. Approximately 10% of the patients report a family history of seizures or epilepsy, but the phenotypic expression varies; therefore, pigmentary changes may be the only clue to the genetic basis⁶. A sibling of our patient had seizures but did not have the classic skin changes associated with HI.

The pathogenesis of hypomelanosis of Ito syndrome is strongly linked to its genetics. A karyotype analysis survey performed on 115 patients revealed chromosomal anomalies in 60 (52%)⁷. Many patients have a chromosomal mosaic pattern, often leading to the generation of two cell lineages, which produce patterns of hypopigmented and hyperpigmented skin. Alterations in X-chromosomes such as inactivation, activation, and mosaicism are the main causes of different patterns of cell behavior in the skin⁷. Perhaps this can also be found in other tissues, such as the fundus (tessellated or radial pigmentation of the fundi), iris (hypopigmentation), and the brain (areas with abnormal cell morphology and neuroblast migration side by side with normal patterns)⁷. Our patient did not have any eye changes, but had a dysplasia in the brain resulting in a hamartoma.

Musculoskeletal signs are common in HI; our patient had right-sided hemihypertrophy, and polydactyly. Musculoskeletal signs are observed in more severe phenotypes and include short stature, pectus carinatum, scoliosis and asymmetry with hemihypertrophy usually along the hypopigmented areas. Bilateral hypertrophy is seen in some cases with generalized hypomelanotic skin^{8,9,10}. These patients show coarse facies and macrocephaly. Abnormalities of the digits may also present as syndactyly, clinodactyly, polydactyly or bifid thumbs^{8,9,10}.

Neurological abnormalities represent the most severe complications of HI and there is great discrepancy between reported prevalence figures ranging from 30%

to 100%^{3,4,5}. One half to two thirds of patients have mental retardation with autism spectrum disorders occurring in 11%^{3,4,5}. Up to 50% have seizures, which are mainly generalized tonic clonic⁵. A significant portion of those with partial seizures have cerebral dysplasias occurring contralateral to the side of the hypomelanotic skin lesions, our patient had a hamartoma and ventriculomegaly on the contralateral side with resultant obvious macrocephaly. Of those with seizures, 40-70% may be controlled while the remainders have intractable seizures like this reported case. Hemimegalencephaly is an occasional finding. Hypotonia with motor developmental delays are common. Brain tumours, both benign and malignant are also associations.

Ocular manifestations are present in one fifth of patients. They include unilateral heterochromic iris with hypopigmentation of the cornea, strabismus, megalocornea, symblepharon, optic atrophy, macrophthalmia, microphthalmia, scleral melanosis and nystagmus. Our patient however did not have any ocular manifestation. Cardiac anomalies may also be present in a few cases such as ventricular or atrial septal defects, tetralogy of fallot, pulmonary stenosis, right bundle branch block or cardiomegaly have all been reported. Genitourinary abnormalities include hypospadias, micropenis, cryptorchidism, single or ectopic kidneys, urethral duplication, gynaecomastia, nephritis and precocious puberty^{8,9,10}. Other abnormalities affecting the hair, fingernails and dentition have also been reported. Hepatomegaly, segmental dilatation of the colon and hernias (inguinal, diaphragmatic and umbilical) are seen in some patients^{8,9,10}.

Hypomelanosis of Ito is the third most common neurocutaneous disorder however there is a paucity of data on reported cases in Nigeria. It is a challenging diagnosis for both the physician and the parents especially in those patients with neurologic involvement and poor seizure control. Our patient had intractable seizures that could not be controlled despite several medications. The high frequency of seizures resulted in fever, poor weight gain and parental anxiety. Early diagnosis is important so that appropriate measures can be taken and parental counseling will be done.

References

- Ito M. A singular case of naevus depigmentosus systematicus bilateralis. *Jpn J Dermatol.* 1951;61:31-2.
- Ruiz-Maldonado R, Toussaint S, Tamayo L, Laterza A, del Castillo V. Hypomelanosis of Ito: diagnostic criteria and report of 41 cases. *Pediatr Dermatol.* 1992;9(1):1-10
- Pascual-Castroviejo I, Lopez-Rodriguez L, de la Cruz Medina M, Salamanca-Maesso C, Roche Herrero C. Hypomelanosis of Ito. Neurological complications in 34 cases. *Can J Neurol Sci.* 1988;15(2):124-9.
- Nehal KS, PeBenito R, Orlov SJ. Analysis of 54 cases of hypopigmentation and hyperpigmentation along the lines of Blaschko. *Arch Dermatol.* 1996;132(10):1167-70.
- Hamada T, Saito T, Sugai T, Morita Y. "Incontinentia pigmenti achromians (Ito)". *Arch Dermatol.* 1967;96(6):673-6
- CamilaK Janninger, Dirk M Eston. Pediatric hypomelanosis of ito. Medscape 2013.
- Sybert VP. Hypomelanosis of Ito: a description, not a diagnosis. *J Invest Dermatol.* 1994;103(5 Suppl):141S-143S.
- Esquivel EE, Pitt MC, Boyd SG. Hypomelanosis of ito- a case report. *Neuropediatrics* 1991;22:216-219
- Glover M.T, Brett E.M, Atherton DJ. Hypomelanosis of Ito: spectrum of disease. *J Pediatr* 115: 75-80
- Ruggieri M, Pavone L. Hypomelanosis of Ito: clinical syndrome or just phenotype. *J Child Neurol* 2000, 15: 635-644