

Adisa AK
Adamu H
Asani MO
Aliyu I

Systemic lupus erythematosus in a 7-year-old girl: A first case report from northern Nigeria

DOI:<http://dx.doi.org/10.4314/njp.v42i2.18>

Accepted: 7th January 2015

Adisa AK (✉)
Adamu H, Asani MO, Aliyu I
Department of Paediatrics,
Aminu Kano Teaching Hospital, Kano
Nigeria
Email: adisakolly@yahoo.com

Abstract: Systemic lupus erythematosus is an autoimmune multi-systemic inflammatory disease that is rare in children. Though a disease of the black race it is rarely diagnosed in black African children. Only few cases have been report in Nigeria and these were in the south. We report a case of a 7-year-old girl who presented with recurrent body swellings, an unusual rash, pericardial effusion and gastro-intestinal disturbances. The diagnosis was made after serology was found to be positive for Anti-nuclear antibody (ANA). She later developed stroke which was characterized by

a convulsive episode, loss of consciousness and subsequent right-sided hemiplegia. She gradually regained consciousness after three days with residual weakness of the right side of her body. She has commenced prednisolone and is currently on follow-up at our clinic. SLE though rare should be considered in any child with multi-organ disease, nephritis or stroke, especially after common conditions in our environment have been excluded.

Key words; Systemic lupus erythematosus, serositis, stroke, nephritis, rashes.

Introduction

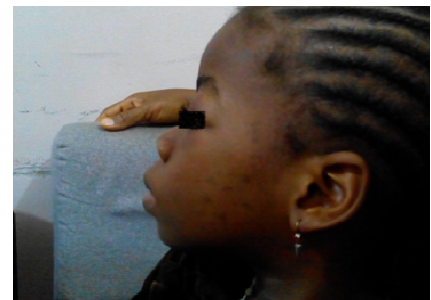Systemic Lupus Erythematosus (SLE) is a chronic multi-systemic autoimmune connective tissue disease¹. It was first described by Rogenius in the 13th century when he coined the word “*lupus*” meaning “wolf bite”². It is characterized by periods of increased disease activity (flares) and then remission¹. Its incidence increases with age and it has a remarkable predilection for the females, especially after puberty^{1,3}. SLE is prevalent among black children resident in Europe and America but rare among blacks in Africa¹⁻³. It is very uncommon in the first decade of life and only 20% of all cases occur in the second decade¹ therefore many paediatricians miss the diagnosis at first presentation.

Case report

A 7-year-old girl was first seen at the Paediatric Out-Patient Department (POPD) of the Aminu Kano Teaching Hospital (AKTH) 5 weeks prior to her admission. She presented with recurrent facial and abdominal swellings (Fig.1) for the past one year. The facial swelling would improve as the day went by. The abdominal swelling was associated with easy satiety. There was no swelling of her feet and she had no urinary symptoms. She had no abdominal pain or difficulty with breathing. She had no history of jaundice, sore throat, joint pain or swelling. There was no history of blood transfusion,

cough or changes in her behavior or school performance. An initial abdominal ultrasound showed bilaterally enlarged kidneys and urine culture had a positive growth for *Escherichia coli* sensitive to cefixime. Cefixime was given at 100mg twice daily and she was also given furosemide at 20mg twice daily. Thereafter, she developed facial rash which later progressed to involve the trunk, extremities and lower lip. The rashes were itchy and more on the sun-exposed parts of her body.

Fig 1: Peri-orbital edema and fading facial rashes



The urinalysis showed proteinuria (2+) and hematuria (1+) and her electrolytes, blood urea nitrogen, creatinine, lipid profile, liver enzymes were essentially normal (Tab. 1.0).

One week later, she was rushed into our Emergency Paediatric Unit (EPU) with complaints of recurrent vomiting and abdominal pain which started two days prior. She had two episodes of similar complaints twice in the preceding month but not severe enough to warrant

admission. At presentation, she had multiple bouts of copious coffee-ground vomitus and was weak, sweaty and cold. The rashes had worsened, despite withdrawal of her medications (cefixime and furosemide). She had a normal height of 115cm (above the 3rd centile for age) and weight of 25kg (above the 3rd centile). There were widespread doughnut-shaped, target-like maculopapular rashes with erythematous border on the face, upper trunk and upper and lower limbs with relative sparing of the extensor aspect of the upper limbs and flexor aspect of the lower limbs, pulses were feeble and regular, blood pressure on the right arm in sitting position was 80/50mmHg (<50th centile for gender, age and height), jugular venous pressure was not elevated, apex was diffuse and she had muffled first and second heart sounds, no added sounds. Abdomen was distended with as cites demonstrable by shifting dullness. There was hepatomegaly with liver span of 14cm, firm and non-tender, no ballotable kidneys. While on admission she developed fever, worsening of abdominal pain, therefore spontaneous bacterial peritonitis was considered.

An urgent abdominal ultrasound confirmed marked ascites, chest radiograph showed enlargement and globular appearance of the cardiac silhouette (CTR=0.72) with apparently clear lung field. Electrocardiography showed low-voltage waves with no rhythm abnormality and echocardiography revealed moderate pericardial effusion with normal systolic function (Fig. 2). A repeat dipstick analysis showed moderate proteinuria (2+), hematuria (1+) with no other abnormality.

Fig 2a: Parasternal long axis/M-mode Echo-cardiography showing anterior and posterior effusions

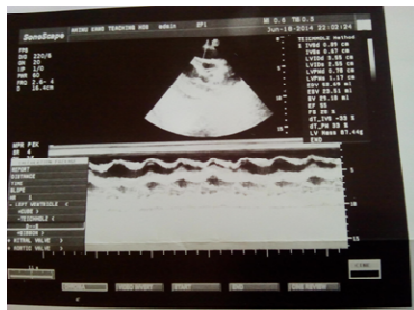
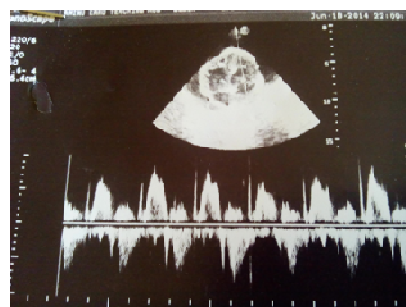


Fig 2b: Dimensional apical 4-chamber view



Full Blood Count (FBC) showed relative lymphocytosis, and platelet count was normal (Tab. 1.0), mantoux test was non-reactive, erythrocyte sedimentation rate was slightly elevated (35mm/hr), sputum for Acid fast bacilli was negative and ascitic tap yielded no organism with normal cell count and glucose, Serum-Ascites Albumin Gradient (SAAG) was 2.5g/dl (transudative). Serologic investigations for hepatitis and HIV were negative and Anti-Nuclear Antibodies (ANA) assay was requested.

While awaiting the result she was placed on 1g of ceftriaxone twice daily, intravenous furosemide (2mg/kg/day in two divided doses) and spironolactone (12.5mg twice daily) and intravenous fluid for the persistent vomiting, intravenous cimetidine (200mg twice daily) was also added and pentazocine (1.5mg/kg thrice daily) given for abdominal pain. Review of ANA result (6.5 which is above lab reference of 1.2) led us to a diagnosis of Systemic Lupus Erythematosus when combined with three other criteria that she had fulfilled viz; serositis, rashes and nephritis. She was commenced on high dose prednisolone at 1mg/kg/day, aspirin and sunscreen lotion while awaiting renal biopsy and ophthalmologic examination prior to commencing hydroxychloroquine. She improved and was discharged to clinic for follow up. A week later, she developed another episode of vomiting, abdominal pain and subsequently had an episode of generalized convulsion associated with loss of consciousness and right-sided body weakness which was worst at onset. Computerized Tomograph (CT) of the brain showed a large left hemispheric infarct. Subsequently, she improved regained of consciousness but had residual aphasia and right-sided hemiparesis. She is still on prednisolone and has commenced physiotherapy

Summary of some essential investigations

Parameter	Result	Normal Range
<i>Complete blood count</i>		
Packed cell volume(%)	30.6	35-50
<i>White cell count</i>		
Total /mm ³	7000	4000-11,000
Neutrophils/mm ³	2300	1500-7000
Lymphocytes/mm ³	4000	1000-3700
Platelet count/mm ³	403 x 10 ³	150-450x10 ³
<i>Ascitic fluid</i>		
Protein (g/l)	43	
Glucose (g/dl)	0.5	
WCC (/mm ³)	50	
<i>Liver Function tests(U/L)</i>		
<i>Enzymes</i>		
ALP	10	42-110
ALT	3	4-34
AST	2	7-45
Bilirubin-Total (µmol/L)	10	4-18
Direct (µmol/L)	3	0-7
<i>Serum Protein(g/l)</i>		
Total	68	59-86
Albumin	36	32-51
Globulin	32	20-43
<i>Clotting Profile</i>		
PT	13s	13-16s
PTTK	36s	35-43s
<i>Blood chemistry</i>		
Urea (mmol/L)	6.7	2.1-6.9
Sodium(mmol/L)	137	130-146
Potassium (mmol/L)	3.6	3.0-5.6
Bicarbonate (mmol/L)	25	20-28
Chloride (mmol/L)	97	94-108
Creatinine (µmol/L)	85	30-111
<i>Lipid Profile(mmol/L)</i>		
Total chol.	2.8	2.5-6.4
HDL	0.8	0.8-2.6
LDL	1.54	0.8-4.3
TRIG	0.8	0.5-2.8
<i>Urine Microscopy</i>		
Pus cells	2	
Epithelial cells	Scanty	
RBC	0	

Discussion

Systemic Lupus Erythematosus is uncommon in children and rarer in African black children with only few case reports⁴. Less than 10% of SLE cases worldwide are diagnosed in the first decade¹. Our patient presented at the age of 7 years which is comparable to the median age (9.2years) at diagnosis among Indian children². However, Olowu⁵ in Ile-Ife (Southwest Nigeria) studied 11 children and found the median age to be 11.2 years. The youngest among his patients was 6 years at diagnosis. The median age at diagnosis in Ile-Ife was similar to the global average of 12years.^{1,6}

Recognised trigger factors in SLE include infections, medications (antihypertensives and anticonvulsants) and hormonal changes^{1,3}. Our patient had culture-positive urinary tract infection which was a possible trigger. Furthermore, it was possible that sun exposure contributed as a trigger in this instance considering the time of the year in the northern part of the country. Generally, the disease is thought to result from a combination of humoral and environmental factors in genetically predisposed individuals. Human Leucocyte Antigen (HLA) class II alleles DR2 and DR3 contribute to disease susceptibility in some patients as inherited complement deficiencies¹.

The most frequent presenting symptoms of SLE are prolonged fever, malaise weight loss and lymphadenopathy¹⁻³. This was not the case with our patient who first presented with features of nephritis. Renal disease is the greatest contributor to morbidity and mortality in paediatric SLE occurring in 60-80% within the first year of disease onset¹. According to Odetunde et al⁷, nephritis with skin rashes was the first manifestation in a 9-year-old boy reported to have SLE in Enugu. Likewise in Ile-Ife⁵, the mean time of onset of renal disease was 1.22 ± 0.93 years after onset of systemic illness.

Our patient had skin rash which was more of vasculitic lesions that are not as common as the malar (butterfly) rash. The use of cefixime around the time of appearance of the rash suggested the possibility of a drug reaction but these rash got worse after the withdrawal of the drug. Moreso, cephalosporins are not recognized trigger factor. Olowu⁵ had noted that only 3 out of the 11 cases had the typical malar rash but none of them had the vasculitic rash. It may be that rash (regardless of morphology) is not common manifestations in Nigerian children with SLE.

Virtually all (10/11) of Olowu's patients presented with arthritis involving one or more site(s), which was not the case with our patient who had no evidence of joint involvement. Our patient had echocardiography-confirmed moderate pericardial effusion. Pericarditis was the first presentation in an 11-year-old girl reported by Elusiyan and Olowu in Ile-Ife⁸. Pericardial effusion is the commonest cardiac presentation and is often a cause of recurrent chest pain^{1,6}.

The recurrent vomiting and abdominal pain as well as

ascites (peritoneal serositis) seen in our patient are common gastro-intestinal manifestations in the disease. Gastrointestinal involvement occurs in one-third of patients manifesting as serositis, vasculitis, pancreatitis or enteritis and abdominal pain¹. Most patients respond to diuretics and steroids and a few may require chloroquine to achieve complete resolution of the ascites. Our patient improved without the need for chloroquine. Similarly, our patient had a stroke which is seen in 8-22% of all cases of SLE⁹. Cerebrovascular event in SLE is due to one or combination of accelerated atherosclerosis, vasculitis, coagulopathy in those that are positive anti-phospholipid antibodies and or thromboembolism from endocarditis^{1,3,9}. The most likely mechanisms in our patient is vasculitis in view of her vasculitic rash, normal coagulation profile (Tab. 1) and the brain CT that showed an extensive area of ischemic infarct on the left cerebral hemisphere. However, the inability to do lupus anticoagulant was a limitation in our evaluation of this patient. Other neuropsychiatric symptoms seen in SLE include seizures, headache and behavioural abnormalities and may be seen in as many as 90% of SLE cases^{1-3,9}.

SLE may presents with pancytopenia or isolated cell line depletion,¹ erythrocyte sedimentation rate (ESR) is usually elevated depending on disease activity but C-reactive protein (CRP) is usually normal except in the presence of infection^{1,3}. Our patient had a slightly elevated ESR but her blood count parameter appeared normal even during the febrile episode. The presence of fever or absence of white cell abnormalities, as in our patient, does not confirm or exclude respectively the presence of infection.

The American College of Rheumatology (ACR) criteria¹⁰ for the diagnosis of SLE revised in 1992 require that at least 4 out of the 11 criteria should be present either serially or simultaneously². Our patient fulfilled the following five of the ACR criteria; serositis, nephritis, skin rash, positive ANA and neurologic disorder.

Conclusion

SLE is a rare disease of the black race with very diverse manifestations. Nephritis is the most important manifestation that often leads to its diagnosis in most Nigerian series. However, stroke of an unidentified aetiology should also make a paediatrician consider SLE like our patient clearly demonstrated.

Limitations

Our patient would have benefitted from renal biopsy, ophthalmologic examination and some more specific serologic tests which were not done due to logistic challenges that are peculiar to our setting.

Acknowledgement

We sincerely appreciate the efforts of Dr R. Hashim and Dr A. Yahaya in the evaluation of this patient.

Authors' contributions

Adisa Abdulhafeez conceptualized the report and manuscript writing. Adamu Halima was involved in manuscript writing. Asani Mustafa carried out the echocardi-

ography, reviewed and edited the manuscript and Aliyu Ibrahim also reviewed and edited the manuscript.

Conflict of interest: None

Funding: None

References

1. Weiss JE. Pediatric Systemic Lupus Erythematosus - More than a positive Antinuclear Antibody. *Pediatrics in Review* 2012; 33 (2):62-74.
2. Narayanan N. Systemic Lupus Erythematosus. In: Parthasarathy A, Menon PS, Gupta P, Nair MK, Agrawal R, Sukumaran TU editors. IAP Textbook of Pediatrics. 5th ed. New Delhi (India): Jaypee Brothers Publishers Ltd, 2013:871-3.
3. Ardoin SP, Laura ES. Systemic Lupus Erythematosus. In: Kliegman RM, Stanton BF, St. Geme III JW, Schor NF, Behran RE editors. Nelson Textbook of Pediatrics. 19th ed. Philadelphia: Elsevier Saunders;2011.p.841-5
4. Coovadia HM, Hussain A, Mwelase LHZ. Systemic Lupus Erythematosus in a South African Child-First documented case report. *S. Afri Med J* 1991;79:101-3.
5. Olowu W. Childhood-onset Systemic Lupus Erythematosus. *J. Natl Med. Assoc.* 2007; 99(7):777-84.
6. Klein-Gitelman MS, Jung LK. Pediatric Systemic Lupus Erythematosus. Medscape [Internet] 2013; [updated 2013 May]. Available from <http://emedicine.medscape.com/article/1008066-overview>. Accessed on 9 Jul. 2014
7. Odetunde OI, Uzoma EB, Uche OH, Nkachukwu US, Daberchi AK, Charles DO. Lupus Nephritis in a Nigerian Child: A first documented case in South-East Nigeria. *Ann Trop Med Pub Hlth* 2013;6 (3):335-8
8. Elusiyan JB, Olowu WA. Pericarditis as initial clinical manifestation of systemic lupus erythematosus in a girl. *S. Afri J. Child Hlth* 2011; 5(4)123-5
9. Dietz-Tegeedor E, Fuentes B. Stroke related to systemic illness and complicated surgery. In: Fisher M. editor. Handbook of Clinical Neurology. Philadelphia: Elsevier; 2009: 93(3).
10. Hochberg MC. Updating the American College of Rheumatology revised criteria for the classification of systemic lupus erythematosus [Letter]. *Arthritis Rheum.* 1997;40:1725