

Ejike O
Eleweke N

Amoebic liver abscess: Drained by ultrasound guided percutaneous aspiration

DOI:<http://dx.doi.org/10.4314/njp.v42i1.16>

Accepted: 27th August 2014

Ejike O (✉)
Department of Paediatrics

Eleweke N
Department of Surgery
Abia State University Teaching
Hospital, Aba Nigeria.
Email: obuoha@yahoo.com

Abstract Summary: Amoebic Liver Abscess in a 20-month-old child: A case of amoebic liver abscess in a Nigerian child is presented. Management consisted of 10days course of Metronidazole and 5days course of Tinidazole without improvement. This was followed by four sessions of ultra-

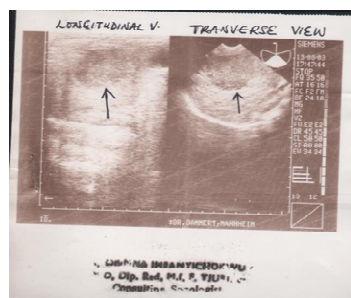
sound guided percutaneous needle aspirations over a period of 4 weeks with subsequent resolution and recovery. This high lights another method of dealing with difficult cases of amoebic liver abscess that may be employed when necessary.

Introduction

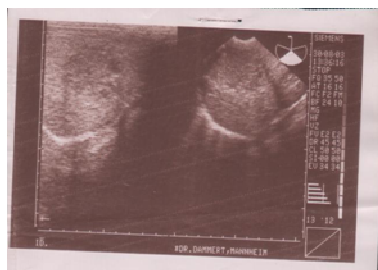
Amoebiasis is a parasitic infection of the lumen of the gastrointestinal tract caused by *Entamoebahistolytica*. It is probably the most widely distributed of the protozoal diseases¹. The clinical manifestations are varied and influenced by the nutritional status of the patient². Asymptomatic infection is common in many infected subjects. However symptoms may include fever, colicky abdominal pain, and diarrhoea with tenesmus and occasional bloody stools. In a small proportion of infected subjects the organism invade the intestinal mucosa and cause severe symptoms such as high grade fever, features of acute abdomen, bloody diarrhoea and dehydration or may disseminate to distant organs especially the liver and lungs^{1,2,3}. Many amoebas invade the portal vein, but it is the liver with reduced resistance from malnutrition, toxic agents and alcoholism that is commonly affected. Other extra-intestinal sites include pleura, pericardium and rarely the brain. Chronic infection may lead to granulomatous lesions called amoeboma^{1,2,3}. Prevalence of amoebic infections is worldwide, varies from 5 - 81%. Prevalence increases with poor personal hygiene, low socio-economic and sanitary standards. Intestinal mucosal invasion is found in approximately 1-17% of infected subjects. Extra intestinal disseminations to internal organs such as the liver occur in an even smaller fraction of infected individuals <1% and much less common in children than adults⁴. Liver abscess may occur in people who have not been to endemic areas⁵. There are few reports of amoebic liver abscess in children and this is the first ever from Abia State University Teaching Hospital Aba, reporting successful ultrasound guided percutaneous drainage of amoebic liver abscess. This case was unresponsive to commonly used tissue amoebicides.

Case report

A 20-monthold child was admitted into the Paediatrics ward of Abia State University Teaching Hospital, Aba, in February 2003 on account of fever, frequent mucoid stools and cough of two weeks duration. He had attended other private clinics in town and had received oral rehydration solutions, antimalaria drugs; Amoxicillin and Metronidazole but symptoms had persisted. On examination he was ill-looking and irritable, temperature of 38.2° C and was moderately dehydrated. He weighed 10.0kg. There was a palpable soft to firm, acutely tender mass over the right lobe of the liver measuring 8 by 10cm. The liver and spleen were 8cm and 3cm enlarged below the costal margins respectively. The chest was clinically clear. Malaria parasite test was negative, haemoglobin level was 9.5gm/dl. Total WBC was 6.3×10^3 /uLwith adifferential of neutrophil 60%, lymphocyte38%, monocytes 2%, ESR was 23mm/1st hr westergren. Liver Function tests were within normal limits as were urinalysis and urine microscopy. Stool microscopy show cysts of *Entamoebahistolytica*. The Liver ultrasound shows a large solitary cyst in the right lobe of the liver measuring 10 to 12cm (Figure 1). The patient received intravenous Ampiclox, oral Tinidazole and Oral rehydration solution. Over the following 10 days the fever persisted and the hepatic mass became progressively bigger and tender (Figure 1, before aspiration). After failed amoebicidal treatment with drugs, ultrasound guided percutaneous aspiration with a 14G cannula at four different sessions over a period of four weeks successfully evacuated the liver abscess (Figure , after aspiration) with complete recovery of the child. At the first session 160 ml of chocolate-coloured fluid was aspirated and the cavity injected with 0.9% saline solution. Microscopic examination of the aspirate did not reveal cyst of *Entamoebahistolytica* nor did culture yield bacterial growth.



Pre-Aspiration



Post Aspiration

and shorten hospital stay^{6,7,8,9}. It may be accomplished percutaneously by a large bore needle, a pigtail catheter, and sump catheter or by peritoneoscopic or laproscopic routes⁷. Repeated sessions of aspiration may risk haemorrhage or secondary infection^{8,9,10}. None of these were encountered in this case. Demonstration of *E. histolytica* in stool remains the only incontrovertible proof of intestinal amoebiasis, the examination takes time and is often difficult. In addition, prior treatment with agents like Tetracycline and Sulfonamides causes amoebas to disappear from stool. In the contrary, stool from most patients with amoebic liver abscess are negative for amoebas in 50% of cases. Serological test as indirect hemagglutination, indirect immunofluorescence, counterimmunoelectrophoresis and agar gel diffusion and ELISA are all most useful for diagnosis of extra intestinal amoebiasis (92-98% positive)^{2,4,10,11}. None of these methods were applied in this case.

Discussion

Hepatic amoebiasis is a disease of the tropics and subtropics¹. Extra-intestinal dissemination is uncommon in children but when it occurs they tend to have a rapidly progressive course/illness with complications and high mortality rates³. Amoebic liver abscess may rupture into the peritoneum or thorax, or through the skin when diagnosis and effective treatment are delayed. Extra intestinal disease in children when it occurs is responsive to amoebicidal treatment but resistant cases have been encountered⁴.

Percutaneous drainage of liver abscess is a useful adjunct to drug therapy and is known to hasten recovery

Conclusion

A case of amoebic liver abscess that failed to respond to commonly used tissue amoebicides presented and usually becomes complicated if prompt actions such as aspiration or drainage are not instituted. This case illustrates successful treatment through ultrasound guide percutaneous needle aspirations. Employment of this technic should not be delayed, it is life saving as well as reducing hospital costs.

Conflict of interest: None
Funding: None

References

1. Sherlock S, Dooley J. The liver in infections. In: Diseases of the liver and biliary system. Oxford: Blackwell Science 2002: 498 - 501
2. Stamm W P. Amoebiasis: *J Clin Pathol* 1976; 29: 83
3. Badue E. A, Archampong E. O and Rocha-Apodu J. T: Surgical problems in amoebiasis; In Principles and Practice of surgery. 3rd ed. Ghana Publishing Corp. 2000: 636 - 637
4. Nelson textbook of Pediatrics, 15th ed. W. B. Sanders Company 1996; 964-966
5. Lamont N M and Pooler N R. Hepatic amoebiasis: a study of 250 cases. *Quart J Med.* 1958; 27: 389 - 412
6. Hanna R. M., Dahniya M. H, Badr S S, El-Betagy A. Percutaneous catheter drainage in drug-resistant amoebic liver abscess. *Trop Med Int. Health* 2000; 5: 578 - 81
7. Djossou S, Malv D, Tamboura M, et al Amoebic liver abscess. A study of twenty cases with literature review. *Rev Med Interne.* 2003Feb;24(2):97-106
8. Singh R B, Bakshi N, Nevil M P. Drainage of deep-seated amoebic liver abscess by Supra catheter. *Trop Doctor* 2003; 33: 247 - 248
9. Jha AK, Das G, Maitra S, Sen-gupta TK, Sen S. Management of large amoebic liver abscess- a comparative study of needle aspiration and catheter drainage. *J Indian Med Assoc* 2012; 110 (1):13-5
10. Harrison R H, Crowe P C, and Fulginiti V A. Amoebic liver abscess in children. *Pediatrics* 1979; 64: 923
11. Krostad D J. Amoebiasis. *N Engl J Med* 1978; 298:262