

Atimati AO
Abiodun PO
Obaseki DE
Olubor OO

Hepatoblastoma in an adolescent girl: A case report

DOI:<http://dx.doi.org/10.4314/njp.v41i4.18>

Accepted: 24th July 2014

Atimati AO (✉)
 Abiodun PO
 Department of Child Health

Obaseki DE
 Department of Pathology
 College of Medical Sciences,
 University of Benin,
 PMB 1154,
 Benin City, Nigeria
 Email: tonyatimati@yahoo.com

Olubor OO
 Department of Child Health,
 University of Benin Teaching Hospital,
 Benin City,
 Nigeria.

Abstract Hepatoblastoma is the most common primary malignant hepatic tumour in children, occurring between the ages of 6months to 3years. It most often presents with a painless abdominal mass discovered accidentally in young children. Occurrence in adolescents and adults is rare and is usually associated with non-specific symptoms which often result in delayed diagnosis and commencement of treatment. Abdominal pain preceding a rapidly progressive abdominal mass is a common pattern observed in adolescents and adults. The histologic type commonly seen in adults is

associated with a poor prognosis. We report the case of a sixteen year old girl who presented with abdominal pain and distension and jaundice of a short duration. She was well-nourished with marked hepatomegaly and ascites. Hepatic transaminases were highly elevated with deranged clotting profile. She developed features of hepatic encephalopathy and died on the seventh day of admission. A Post-mortem histologic diagnosis of hepatoblastoma was made.

Key words: Hepatoblastoma, adolescent, poor prognosis

Introduction

Hepatoblastoma is a rare malignant tumour originating in the cells of the liver¹. It is the most common primary malignant tumour of the liver in children accounting for about 79% of liver cancer in children in the United States². Hepatoblastoma has an annual global incidence of 0.5 – 1.5 per million in the paediatric population³. A review of 274 children with primary malignant hepatic tumours in South Africa from 1988 – 2006 showed a 48% prevalence of hepatoblastoma, 27% hepatocellular carcinoma while vascular tumours, liver sarcomas and endodermal sinus tumours constituted 25%⁴. The incidence of hepatoblastoma is highest in infants and falls off rapidly, with most cases occurring prior to five years². There is a higher male to female ratio and white children are often more affected than Negroed children.¹ The aetiology of hepatoblastoma is not quite known, but cytogenetic abnormalities which include gain of chromosome 2, 8, 20, decreased expression of the adenomatous polyposis coli gene and increased expression of β -catenin have been described in hepatoblastoma². Increased incidence has been reported in Beckwith-Weidemann syndrome, hemi-hypertrophy, familial adenomatous polyposis and in children with low birth weight². Infants and younger children with hepatoblastoma typically present with an asymptomatic abdominal mass, and diagnosis is often made late, when the disease is metastatic³. The tumour is mainly unifocal, affecting the right lobe more commonly than the left, and occasionally affects both lobes. Less common features of hepatoblastoma are weight loss, anorexia and pain².

There is paucity of literature on hepatoblastoma in Nigeria. A report of primary malignant tumours of the liver in Enugu from 1999 – 2005 showed no case of hepatoblastoma out of 424 patients reviewed⁵. Hepatoblastoma is rare in adolescents and adults and when it occurs, the symptoms are usually non-specific⁶. Symptoms associated with adult hepatoblastoma in a review of literature by Zheng et al⁶ include failure to thrive, rapidly expanding upper abdominal mass, abdominal pain, vomiting and fever. In two other case reports abdominal pain which preceded a rapidly expanding upper abdominal mass was the main presentation^{7,8}.

We present a case of a sixteen year old girl who presented with a short history of abdominal pain and swelling and died a week later.

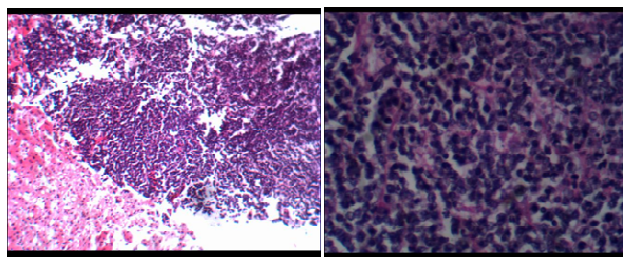
Case

GL was a sixteen year old girl referred to our hospital with complaints of abdominal pain of 9days and abdominal swelling of 8days duration. The pain was dull aching, located in the right hypochondrium, severe and associated with backache. Pain was present most of the time. A day after the onset of abdominal pain, she noticed a swelling in the right hypochondrium which was small initially, but progressively increased in size, extending to the epigastric and right lumbar regions. There was associated early satiety. There was no fever or vomiting. Patient's father and mother died 16years and 3years earlier, respectively, from an unknown cause. Examination revealed a well-nourished (weight 59kg, height 1.52m) female adolescent, who was slightly

jaundiced, conscious and well-oriented. The abdomen was distended with an abdominal girth of 77cm. The liver was palpable 16cm below the right costal margin with a span of 26cm. The liver was tender, firm, with a smooth surface and well-defined edge. There was moderate ascites demonstrable by shifting dullness. She was tachycardic and dyspnoeic with normal percussion notes and breath sounds.

Investigations done included: HBsAg (positive), HCV (negative), prolonged Prothrombin time and Activated partial thromboplastin time; Total Serum bilirubin 3.5mg/dl, conjugated 1.6mg/dl; normal chest radiograph; abdominal ultra-sonogram which showed markedly enlarged liver with heterogeneous parenchymal echotexture, smooth outline without a focal mass lesion. LFT revealed markedly elevated ALP (689IU/L), AST (856IU/L), and ALT (294IU/L).

Fig 1a: (H&E X4) and 1b (H&E X40) shows sheets and ribbons of small 'embryonal' type cells with high nucleocytoplasmic ratio, nuclear hyperchromasia and small amount of basophilic cytoplasm.



A diagnosis of Fulminant hepatic failure with a differential of Hepatocellular Carcinoma was made. She was commenced on vitamins A, D, E and K, Neomycin, lactulose and Dextrose infusion. She also received fresh frozen plasma with a view to doing a liver biopsy. Patient continued to deteriorate becoming more dyspnoeic and restless, with increasing abdominal girth, progression of pedal oedema, deterioration of her mental state and worsening clotting profile. She died on the seventh day on admission. A post-mortem needle biopsy was done since relatives did not consent to an autopsy. Histologic sections of the liver revealed a malignant neoplastic lesion composed of dis-cohesive sheets of fairly uniform small cells with scant cytoplasm. The cells have oval hyperchromatic nuclei with prominent nucleoli with presence of pseudorosettes which are consistent with embryonal histologic type of hepatoblastoma.

Discussion

Hepatoblastoma usually occurs between the ages of 6months to 3years and the median age at diagnosis is 1 year.⁹ Most cases of hepatoblastoma occur before the age of 5years². Therefore, the occurrence of hepatoblastoma in this 16year old girl is a very rare occurrence. Hepatoblastoma has been diagnosed only in a few adults as shown by a review of all published data and library search^{3,6}.

Infants and younger children may be asymptomatic³,

with accidental palpation of the liver by caregiver or during routine medical examination. Abdominal pain, which is a prominent symptom in adolescents and adults, usually precedes a rapidly expanding abdominal mass^{7,8,10}. Other symptoms include abdominal distension, weight loss, anorexia, vomiting and fever. Our patient presented with abdominal pain which was followed shortly by abdominal distension which progressively increased in size.

The diagnosis of hepatoblastoma is usually made by histology of liver biopsy. Supportive investigations include assay for α -fetoprotein, abdominal ultrasonography, computerized tomography and magnetic resonance imaging. We did not assay for α -fetoprotein and the diagnosis was missed by abdominal ultrasonography as has been similarly reported by Al-jiffry⁶ in Saudi Arabia where the diagnosis was missed both with Ultrasound and Computerized Tomography. The tumour is seen as a hyperechoic, solid, intra-hepatic mass on abdominal ultrasound¹¹. There is no uniform report on the levels of hepatic transaminases in patients with hepatoblastoma. The markedly elevated hepatic transaminases in this patient are at variant with the case reported by Al-Jiffry with normal levels. This difference might be due to the stage of the disease which is usually done at the time of surgery. We, however, did not have the benefit of staging this patient's disease since the relatives objected to autopsy. Inagaki et al similarly reported slightly elevated hepatic transaminases in an eighteen year old male adult in Japan¹⁰.

A positive Hepatitis B surface antigen test in this patient is an unusual finding in Hepatoblastoma. Hepatoblastoma as often seen in children occurs almost always in patients with no underlying liver pathology¹². This is, however, different in cases reported in adults where there could be co-infection with Hepatitis B as in this patient^{3,10}. Similarly, fibrosis or cirrhosis has been observed in adult cases of hepatoblastoma^{3,6}. This has led to the consideration that hepatoblastoma may have a different pathogenetic pathway in adults compared to children⁶.

The diagnosis of hepatoblastoma was not a strong consideration in this patient until demise. In almost all of the cases reviewed by Zheng et al,⁴ the diagnosis of hepatoblastoma was not made until histology of the liver biopsy was received. This is usually due to the older age of the patients in which hepatoblastoma is uncommon and the unusual mode of presentation. In this patient, the tender hepatomegaly, jaundice, ascites, markedly deranged liver enzymes, prolonged prothrombin and partial thromboplastin time, positive HBsAg, short duration of symptoms in a well-nourished adolescent led to the consideration of fulminant hepatic failure from hepatitis B virus infection as our initial diagnosis.

Hepatoblastoma is classified by histology as epithelial (56%) or mixed epithelial/mesenchymal (44%). Epithelial hepatoblastoma is further divided into pure fetal, embryonal, macrotrabecular and small cell undifferentiated types². The embryonal histologic type of

hepatoblastoma found in this patient is usually associated with a poor prognosis¹⁵. The purely fetal type which has a favourable prognosis is rarely found in adult who commonly have the mixed histologic type of hepatoblastoma^{3,6}. Other prognostic factors outside the histologic type include multiple lobes involvement, decreased p27 gene expression, multi-focal dissemination, AFP(α -fetoprotein) less than 100 or more than 100,000ng/ml¹⁴, in addition to late presentation and mis-diagnosis which might lead to late institution of appropriate treatment. These parameters could not be evaluated in this patient which, could have contributed in addition to the poor histologic type to the poor prognosis. Complete surgical resection is the mainstay of treatment of patients with hepatoblastoma. Administration of chemotherapy enhances complete excision of unresectable hepatic tumours¹⁵ which would have been offered to our patient had the diagnosis been made.

Conclusion

Hepatoblastoma is a rare hepatic tumour in adolescents and adults. It often presents with asymptomatic abdominal mass in younger children. Abdominal pain is a prominent feature in adults and usually precedes a rapidly progressive abdominal mass which often has a poor outcome. A high index of suspicion is, therefore, required to make the diagnosis and institute early treatment.

Conflict of interest: None

Funding: None

References

1. Attiveh EF. Hepatoblastoma in children. www.chop.edu/service/oncology/cancers-explained/diagnosing-and-treating-pediatric-hepatoblastoma.html.
2. Herzog CE, Andrassy RJ, Eftekhari F. Childhood Cancers: Hepatoblastoma. *The Oncologist* 2000; 5:445-53.
3. Rougemont A, McLin VA, Toso C, Wildhaber BE. Adult hepatoblastoma: Learning from children. *J Hepatol* 2012; 56(6): 1392 – 1403.
4. Moore SW, Davidson A, Hadley GP, et al. Malignant liver tumours in South African children: a national audit. *World J Surg.* 2008;32(7): 1389 – 95.
5. Nwokediuko S, Ijoma U, Obienu O. Liver cancer in Enugu, South East Nigeria. *Insight Bioinformatics* 2011;1(1):1 – 5.
6. Zheng MH, Zhang L, Gu DN, Shi HQ, Zeng QQ, Chen YP. Hepatoblastoma in adults: a review of literature. *J Clin Med Res* 2009; 1 (1):13 – 16.
7. Bortolasi L, Marchiori L, Dal Dossi I, Colombari R, Nicoli N. Hepatoblastoma in adult age: a report of two cases. *Hepatogastroenterology* 1996;43(10):1073 – 8.
8. Al-Jiffry BO. Adult hepatoblastoma: A case report and literature review. *Intl J Surgery Case Reports.* 2013; 4(2): 204 – 207.
9. Schnater JM, Kohler SE, Lamers WH, von Schweinitz D, Aronson DC. Where do we stand with hepatoblastoma? A review. *Cancer* 2003; 98: 668 – 78.
10. Inagaki M, Yagi T, Urushihara N, Shima Y, Sadamori H, Takakura N, Tanaka N, Oda M. Successfully resected hepatoblastoma in a young adult with chronic hepatitis B: report of a case. *Eur J Gastroenterol Hepatol* 2001; 13(8):981 – 4.
11. De Campo M, de Campo JF. Ultrasound of primary hepatic tumours in Childhood. *Paediatr Radiol.* 1988; 19(1): 19 – 24.
12. Richter A, Grabhorn E, Schulz A, Schaefer HJ, Burdelski M, Ganschow R. Hepatoblastoma in a child with progressive familial intrahepatic cholestasis. *Paediatr Transplant,* 2005;9: 805 – 808.
13. Haas JE, Muczynski KA, Krailo M, Ablin A, Land V, Vietti TJ. Histopathology and prognosis in childhood hepatoblastoma and hepatocarcinoma. *Cancer* 1989;64: 1082 – 1085.
14. Brotto M, Finegold MJ. Distinct pattern of p27/KIP I gene expression in hepatoblastoma and prognostic implications with correlation before and after chemotherapy. *Hum Pathol* 2002;33:198 – 205.
15. Pinpalwar AP, Sharif K, Ramani P, Stevens M, Grundy R, Morland B, Lloyd C, et al. Strategy for hepatoblastoma management: Transplant versus non-transplant surgery. *J Pediatr Surg* 2002; 37: 240 – 245.