

**Eyong KI**  
**Philip-Ephraim EE**  
**Inah G**  
**Ikobah JM**  
**Ekanem EE**  
**Asindi AA**

## Cranial nerve palsies in Nigerian children

DOI:<http://dx.doi.org/10.4314/njp.v41i2.11>

Accepted: 8th January 2014

Ekanem EE (✉)  
 Eyong KI, Ikobah JM, Asindi AA  
 Department of Paediatrics,

Philip-Ephraim EE  
 Department of Internal Medicine,

Inah G  
 Department of Radiology,  
 University of Calabar, Teaching  
 Hospital Calabar,  
 Nigeria.  
 Email: profekanem@gmail.com

**Abstract:** *Background:* Cranial nerve palsies are common clinical problem routinely encountered in neurological practice; the dysfunction can occur at any point in the course of the nerve and may point to serious pathology. The aim of this study was to determine the pattern and underlying aetiology of cranial nerve palsies in Nigerian children.

*Method:* Children in the Children's Emergency Unit and the Children's Ward of the University of Calabar Teaching Hospital, Calabar, Nigeria, with neurological problems over a 12-month period (January through December 2012), were recruited into the study. Each child was admitted and evaluated by the Paediatric Neurology Unit. Those with cranial nerve palsies were selected for detailed analysis. The biodata, clinical features and relevant laboratory results were documented.

*Results:* Of the 285 with neurological problems 23 (8.1%) had cranial nerve palsies. Fifteen (65.2%) of the children had single cranial nerve palsies while eight (34.8%) had multiple cranial nerves involvement. Of the 43 nerves involved, the facial nerve was the commonest (38.3%) followed by the oculomotor (23.5%) and abducens (20.6%). Intracranial infections such as meningitis, viral encephalitis and brain abscess were incriminated in 60.8% of the patients and 70.6% of the nerves involved.

*Conclusion:* Cranial nerve palsies cause handicap and cosmetic problems. It is recommended that every child with cranial neuropathy should be evaluated for intracranial infections among other differentials. Prompt diagnosis, treatment and immunisation against related infections is paramount.

### Introduction

Cranial nerve palsy is a common clinical problem routinely encountered in neurology practice.<sup>1</sup> Dysfunction of a cranial nerve can occur from intrinsic brainstem dysfunction to its peripheral course.<sup>2</sup> Cranial nerves palsies may be the earliest indication of an on-going intracranial and extracranial pathology and may assist in the diagnosis of such.<sup>1</sup>

Anatomical patterns of cranial nerves involvement can facilitate the determination of the primary lesion. Various infections, malignant neoplasms and autoimmune vasculitis are common disorders leading to cranial nerve palsies.<sup>1</sup> A large number of diffuse neurological disorders (e.g. Guillain-Barre' syndrome, myopathies) may present with multiple cranial nerve palsies.

In a study on cranial palsies in American adults, Keane JR<sup>3</sup> found that the most commonly involved nerves were the sixth, second, fourth and seventh. In that series the

underlying causes were largely trauma, intracranial infections and tumours.

The pattern of cranial nerve palsy is likely to differ with age and may have a geographical variation. This prospective study was therefore undertaken to determine the pattern and the underlying aetiology of cranial nerve palsies in Nigerian children. The study was conducted in the University of Calabar Teaching Hospital (UCTH), Calabar, in South-eastern Nigeria. The rationale was to provide the reader with an overview of the diseases which have a predilection for afflicting cranial nerves. We hope that the result will help improve clinical diagnostic acumen and management in the region.

### Methodology

This prospective survey was conducted within a 12-month period, January through December 2012. Ethical

approval was obtained from the Research Ethics Committee of the University of Calabar Teaching Hospital. As a Departmental policy, every child admitted in the Children Emergency Room (CHER) and the Children's ward of the UCTH with significant neurological deficit was referred to the Paediatric Neurology Unit for further evaluation or admission. Inpatients of other paediatric subspecialties so referred had a thorough and detailed review of their nervous system. All the patients whose clinical features involved cranial nerve(s) were noted. When indicated, and considered safe, a spinal tap was undertaken and the CSF analysed. For the purpose of this survey, the demographic data, clinical features, diagnosis, and relevant laboratory results were filled in a proforma form. Due to financial constraints, only one child with sickle cell stroke was able to afford neuroimaging scan (CT and MRI each). There were no facilities for nerve conduction test. The diagnosis of viral encephalitis was made on clinical grounds as the hospital has no facility for viral studies. Viral encephalopathy was therefore diagnosed in children with fever accompanied by acute neurological signs such as irritability, convulsions with altered level of consciousness whose cerebrospinal fluid was clear and sterile on routine culture technique. All the children were treated as appropriate, based on the diagnosis made. On discharge, patients were followed up weekly and then fortnightly at the paediatric Neurology Clinic. Data obtained was analysed using tables and simple proportions.

## Results

During the period of the survey, 2199 children were admitted into the Ward and CHER. Of these, 285 (13%) had neurologically related problems. Of the 285, 23 (8.1%) had cranial nerve palsies. Thirteen of the children were males while 10 were females; one child was aged less than one year, 13 were 1-5 years and nine were above five years. The oldest child in the series was 12 years old and the youngest, eight months.

A total of 34 nerves were affected in the 23 children; the most susceptible nerve was the facial (38.3% of the 34 nerves) followed by oculomotor (23.5%) and abducens nerve (20.6%) (Table 1). Others were the optic and cochlear (3 each). Fifteen (65.2%) of the children had single cranial nerve palsies while 8 (34.8%) had multiple cranial nerve involvement( 2 nerves in 6, 3 nerves in 2). Three children had bilateral oculomotor palsy each. The two cases with three-nerve involvement were related to viral encephalitis and cerebral contusion from automobile accident respectively.

**Table 1:** Distribution of 34 cranial nerves\* involved in 23 children

Nerve	no.	percentage
Facial	13	38.3
Oculomotor	8	23.5
Abducens	7	20.6
Optic nerve	3	8.8
Auditory	3	8.8

Meningitis (2 of them, tuberculous)) was the commonest underlying cause of the nerve palsy 15 (44.2% of nerves) followed by suspected viral encephalitis 8 (23.5%). In 14(60.8%) of the 23 children, the palsy was causally associated with infections (Table2). Infection (meningitis, encephalitis and brain abscess) was also associated with 76.5%of the nerve damage (26 of 34 nerves).

**Table 2:** No. of nerves involved related to presumed aetiology in 23 children

Aetiology	number	percentage
Meningitis	15	44.2
Viral encephalitis	8	23.5
Cerebral abscess	3	8.8
Bell's palsy	3	8.8
Sickle cell disease	2	5.9
Leukaemia	2	5.9
Cerebral contusion(RTA)	1	2.9
Total	34	100

RTA = road traffic accident

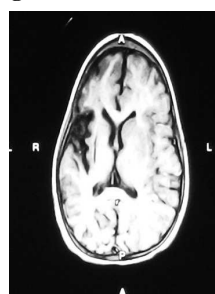
Cranial nerves VI and VII were largely associated with meningitis. The two cases of sickle cell stroke had facial nerve palsy. Two children had leukaemia received vincristine as part of their chemotherapy regimen. (Table 3).

**Table 3:** Distribution of nerve palsy related to aetiology

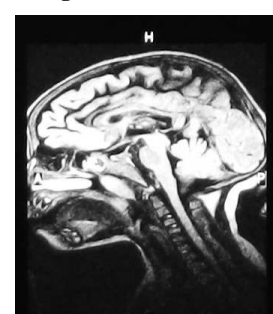
Aetiology	Type of cranial nerve					Total
	Optic	Oculomotor	Abducens	Facial	Auditory	
Meningitis	1	2	5	4	1	13
Viral encephalitis	2	3	2	-	1	8
TB meningitis	-	-	-	1	1	2
Bell's palsy	-	-	-	3	-	3
Cerebral abscess	-	2	-	1	-	3
Sickle cell stroke	-	-	-	2	-	2
Leukaemia	-	-	-	2	-	1
Contusion injury (RTA)	-	1	-	-	-	1
Total	3	8	7	13	3	34

Figure 1a and 1b are MRI of a 4-year old female with sickle cell stroke with facial nerve palsy showing a right parietal lobe infarct and atrophy.

**Fig 1a**



**Fig 1b**



MRI of brain of sickle cell patients

## Discussion

To our knowledge, no large series of cranial neuropathies on Nigerian children is available. This study is limited due to the small number of subjects and investigative handicap but the findings appear to offer some reasonable and helpful clues as to the pattern of cranial palsy and the aetiopathologies in Nigerian children. We regard this as a preliminary study which is to lay a foundation for more elaborate, and hopefully, a multicentre survey. Being preliminary, we do not intend to relate the result to other available studies but just discuss the findings as they are.

The study has identified intracranial infections as the most probable cause of cranial nerve palsy in Nigerian children. In contrast, cranial palsies are frequently seen as post-traumatic and ischaemic syndromes in adult population.<sup>3</sup> In this series intracranial infection alone constituted 76.5% nerve damage. A majority of the children (60.8%) derived their neuropathy from infection. The aetiology of Bell's palsy may not be completely understood; however, a reactivation of herpes simplex virus type 1 (HSV-1) infection has been postulated to cause the disease.<sup>4,5</sup> Also, multiple case reports have described Bell's palsy following immunization with influenza and hepatitis B virus (HBV) vaccines.<sup>6</sup> Probably, these attenuated live-vaccines can convert to become neurovirulent. Considering these postulations, the three cases with Bell's palsy may additionally be regarded as being infective in origin. This association between infections and cranial neuropathy underscores the importance of prompt diagnosis and therapeutic intervention in children with these conditions. But more importantly is the relevance of routine immunisation against common bacterial and viral agents causing meningitis and encephalitis in the environment.

The study has shown that the most susceptible cranial nerve is the facial (38.3%), with the affection of the oculomotor (8%) and abducens (7%) to a less extent. In the present study, a majority of the underlying disease entities have involved nerve VII. This is in contrast to

studies in adult populations which identified the abducens nerve as the most vulnerable in various pathologies.<sup>3,7</sup> This may be related to the aetiology. Comparatively, meningitis and viral infections such as rhinovirus and Herpes Simplex are more common events in children. The inflammatory swelling with compression and subsequent paralysis of the VII nerve in its long course within the facial canal may be an additional reason why the facial nerve is most vulnerable in children.<sup>8,9</sup> Vincristine, a component of chemotherapy in childhood leukaemia, can cause neuropathy as a side effect.<sup>10</sup>

Interestingly, despite the high prevalence paediatric HIV/AIDS in Nigerian children, the study did not capture any case; we are unable to explain this. It is also interesting that intracranial tumour did not feature in this survey. Solid intracranial tumours are known to be rare in Nigerian paediatric population.

## Conclusion

In conclusion, Cranial nerve palsies may be a common clinical problem encountered in neurological practice and their presence is an indication of an underlying intracranial pathology. The incapacitation and the cosmetic disfigurement they create can be a cause of great concern to the physician, patients and parents. That intracranial infections constitute the commonest cause places a premium on prompt diagnosis and therapeutic intervention in children with these underlying disease conditions. But more importantly is the relevance of routine immunisation against common bacterial and viral agents causing meningitides and encephalitis in the environment. Sometimes, despite extensive biochemical and radiological work-up, the accurate diagnosis may not be established. Few such patients represent "idiopathic" variety of cranial nerve involvement and show good response to corticosteroids.<sup>1</sup>

## References

- Garg RK, Karak B. Multiple cranial neuropathy: a common diagnostic problem. *J Assoc Physicians India*. 1999; 47: 1003-7.
- Carroll CG, Campbell WW. Multiple cranial neuropathies. *Semin Neurol* 2009; 29: 53-65.
- Keane JR. Bilateral involvement of a single cranial nerve: analysis of 578 cases. *Neurology*. 2005; 65 (6): 950-2.
- Hato N, Yamada H, Kohno M, et al. Valacyclovir and prednisolone treatment for Bell's palsy: a multicentre, randomised placebo-controlled study. *Otol Neurotol* 2007; 28: 408-413.
- Thaera GM, Wellik KE, Barrs DM, et al. Are corticosteroid and antiviral treatments effective for Bell's palsy: a critically appraised topic. *Neurologist*. 2010; 16: 138-140.
- Rath B, Linder T, Cornblath D, et al. All that palsies is not Bell's palsy- the need to define Bell's palsy as an adverse event following immunization. *Vaccine* 2007; 26: 1-14.
- Rowe F. Prevalence of ocular motor cranial nerve palsy and associations following stroke. *Eye*. 2011; 25: 881-7. <http://www.physiotherapy-treatment.com/7th-cranial-nerve.html>
- Martin JH. *Neuroanatomy Text and Atlas*, 3rd ed. McGraw-Hill, New York 2003.
- Guarav D, Atul D, Diksha K. vincristine induced neuropathy. *JAPI* 2012;60:56-60
- Suprlya S, Asit R D, Kaushik S, Chandra D. Simultaneous isolated bilateral facial nerve palsy: A rare vincristine –associated toxicity. *Ind J Med Sc*. 2009;63(8):355-8.