

# Eyelid Sarcoidosis Lesion in Abuja, Nigeria

Adaora C. Okudo<sup>1</sup>, Olufemi E. Babalola<sup>1</sup>, Emanso O. Umobong<sup>2</sup>, Hilda A. Titiloye<sup>3</sup>

<sup>1</sup>Rachel Eye Center, Garki, Abuja, Nigeria, <sup>2</sup>Histoconsult Laboratory Limited, Garki, Abuja, Nigeria, <sup>3</sup>SKIN101Clinic Limited, Skin 101 Center, Maitama, FCT Abuja, Nigeria

## Abstract

We report a case of sarcoidosis involving the eyelid in a Nigerian setting. Lid masses are sometimes overlooked by patients and attending physicians. This report is on a 47-year-old Ghanaian male who presented to private eye clinic in Abuja, Nigeria. He had multiple eyelid lesions, skin lesions on his scalp, back of his ear and neck. He had a history of coughing and wheezing. Histopathology of skin biopsy confirmed that they were sarcoid lesion. Chest X-ray showed hilar lymphadenopathy. He was placed on tablets prednisolone 20 mg daily for 8 weeks. The symptoms abated and have not reoccurred 3 years posttreatment. In conclusion, atypical eyelid lesions with pulmonary involvement should be biopsied and sent for histopathology. Systemic steroids are effective in treating lid involvement of sarcoidosis. The management of sarcoidosis requires a multidisciplinary approach between the physician, dermatologist, and ophthalmologist.

**Keywords:** Biopsy, coughing, ear, eyelid, hilar lymphadenopathy, neck sarcoid lesions, prednisolone, scalp, wheezing

## INTRODUCTION

Sarcoidosis is a chronic noncaseating granulomatous inflammation that affects multiple systems. It mainly affects young adults between 20 and 40 years and is commoner in females. The commonest system that is affected is the pulmonary, skin, and eyes.<sup>[1]</sup> Ocular manifestation of sarcoidosis has been reported in 12.9% to 79.2%<sup>[2-6]</sup> of cases. Within the eye, it commonly presents as uveitis<sup>[5,7-10]</sup> and lid manifestations is a rare form of presentations.<sup>[11]</sup> Within the lid, it can present as millet-seed nodules, nodules, ulcerated nodules, plaques, swollen eyelids,<sup>[12]</sup> lid retraction,<sup>[13]</sup> orbital involvement with lid mass,<sup>[14]</sup> and destructive eyelid lesions.<sup>[11]</sup> Ogunlesi and Rankin reported the first case of sarcoidosis in Nigeria as far back as 1961.<sup>[15]</sup> This was in a male with pulmonary, ocular, and mandibular involvement.<sup>[15]</sup> Despite a thorough literature search, we did not come across a reported case of lid involvement of sarcoidosis in Nigeria.

## CASE HISTORY

A male presented to our hospital with a 2-month history of abnormal growths in the lid, lip, and back of his neck. The lesions started around the left eye, then the right, and progressively involved the lips and upper neck, were not

increasing in size but were spreading to involve new sites. There was a positive history of cough productive of sputum of 2 months duration with wheezing, although no difficulty in breathing or chest pain and no other systemic symptoms. He had used several antibiotics for the cough but the cough did not abate. He is allergic to pollens and had used prednisolone for a week after the onset of symptoms. He discontinued the prednisolone after the lesions initially abated, but the lesions re-emerged. He was subsequently observed by a dermatologist who advised him to apply clobetasol cream to the nonocular body lesions. He responded well to clobetasol and skin lesions significantly regressed after 3 days. He was then referred to the ophthalmologist to manage the eyelid lesions.

We examined a healthy looking 47-year-old Ghanaian with dome-shaped papules [Figures 1 and 2] on the lid near the lashes in both eyes. Some of the lesions coalesced into

**Address for correspondence:** Adaora Chinwendu Okudo, Rachel Eye Center, 23 Onitsha Crescent, Off Gimbya Street, Garki Area 11, PO Box 4108 Garki, Abuja, Nigeria.  
E-mail: [adaoraokudo@gmail.com](mailto:adaoraokudo@gmail.com)

**Received:** 24 April 2021 **Revised:** 16 November 2021  
**Accepted:** 20 December 2021 **Published:** 29 August 2022

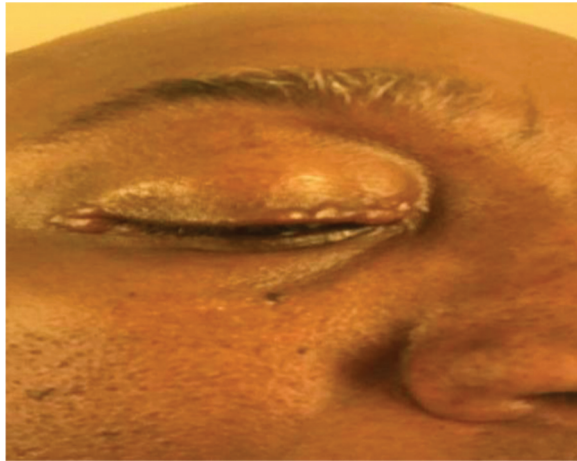This is an open access journal, and articles are distributed under the terms of the Creative Commons Attribution-NonCommercial-ShareAlike 4.0 License, which allows others to remix, tweak, and build upon the work non-commercially, as long as appropriate credit is given and the new creations are licensed under the identical terms.

**For reprints contact:** [reprints@medknow.com](mailto:reprints@medknow.com)

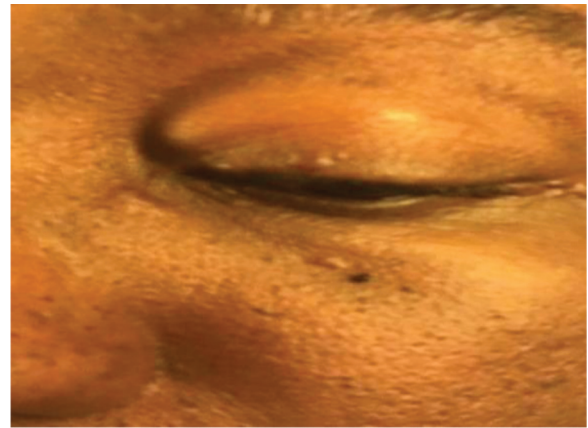**How to cite this article:** Okudo AC, Babalola OE, Umobong EO, Titiloye HA. Eyelid Sarcoidosis Lesion in Abuja, Nigeria. *Niger J Ophthalmol* 2022;30:79-82.

plaques, others remained discrete, round, and smooth. Similar lesions were found behind his ear, on the scalp, and neck, although these other lesions were very faint at time of presentation to the eye clinic. The eye was otherwise normal. Visual acuity was 6/6 to both eyes, with intraocular pressures 14 mmHg bilaterally. Both anterior and posterior segments were normal. Full blood count, electrolyte urea, and creatinine were normal.

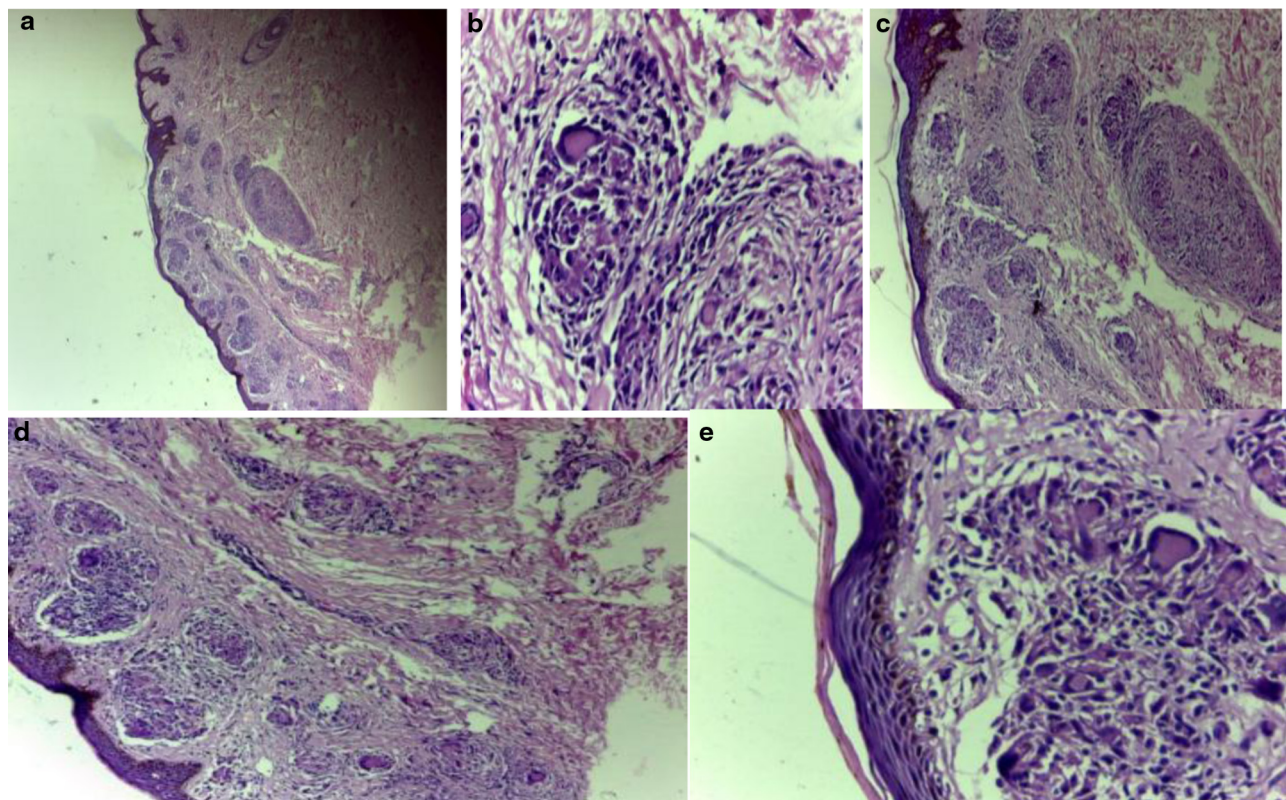
A skin biopsy was taken. Histopathology reports showed a chronic inflammatory lesion, characterized by numerous confluent granulomas in the superficial and deep dermis composed of aggregates of epithelioid macrophages occasionally sprinkled with sparse infiltrates of lymphocytes and giant cells with dermal fibrosis. No caseation or cellular atypia reported [Figure 3a–e]. These features are characteristic of sarcoidosis. QuantiFERON TB Gold test was negative for tuberculosis. Chest X-ray report



**Figure 1:** Right Eye Sarcoidosis Lesion Pre-Treatment

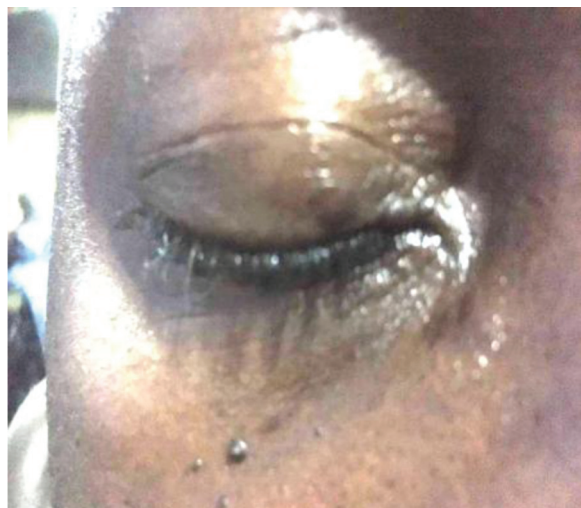


**Figure 2:** Left Eye Sarcoidosis Lesion Pre-Treatment

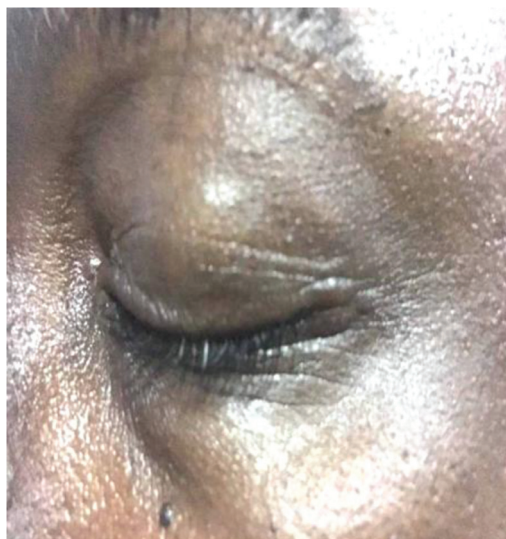

**Figure 3:** (a) Histo-micrograph:  $\times 4$ . stretched epidermis overlying edematous dermis. (b) Histo-micrograph:  $\times 40$ . Giant cell within the granuloma. (c) Histo-micrograph:  $\times 10$ . Granuloma within the giant cells. Stretched epidermis with numerous intradermal granulomas composed of aggregates of epithelioid cells with lymphocytes and giant cells. (d) Histo-micrograph:  $\times 10$ . Picture shows the epidermis. In the dermis are numerous granulomas composed of aggregates of epithelioid cells with lymphocytes and giant cells. (e) Histo-micrograph  $\times 40$ . Numerous giant cells within a granuloma Haematoxylin and Eosin stain (H&E)





**Figure 4:** Right eye 1 month Post Treatment



**Figure 5:** Left eye 1 month Post Treatment

showed matted nodular dense masses at the hilar areas and the lung fields were clear.

He was then placed on tablets prednisolone 20 mg daily. A week later, lesions started regressing and all symptoms had abated after 1 month of steroids [Figures 4 and 5]. He was on steroids including the tailing off period for a total 8 weeks. It has been 3 years since his treatment was stopped and the cough and lid masses have not recurred.

## DISCUSSION

Lid presentation of sarcoidosis is very rare and we did not come across a lid presentation in Nigeria or Ghana so we assume this is the first reported case.

Sarcoidosis affects a myriad of systems as in the reported case. He had pulmonary, skin, and ocular involvement. The commonest ocular involvement is uveitis<sup>[5,7-10]</sup> but lid presentation is very rare.<sup>[11]</sup> Although this might be because the lid presentations are being underreported, the lid lesions might occasionally be overlooked by the patients and physicians might not be considering sarcoidosis when these lesions are observed. It is necessary to take biopsies of atypical lid lesions especially when there is a pulmonary involvement. The pulmonary symptoms again can range from mild to severe. Mild cases can be overlooked. Occasionally patients just take antibiotics and cough syrup when they have this cough, similar to what was observed in our patient. We placed the patient on prednisolone tablets as against a steroid-based cream because of the multisystemic involvement especially the pulmonary system. Once the steroids were commenced, the patients cough and wheezing stopped. In addition, steroid-based cream can cause chemical injury to the eyes as they are made for skin preparation and the compositions are not ideal for ocular use. The lid lesions are very close to the eye and so these preparations cannot be safely used. The steroids need to be used for a considerable

duration until all symptoms and signs abate before it is tailed off to prevent recurrence.

All cases of sarcoidosis observed require a multidisciplinary approach by the physician, dermatologist, and ophthalmologist. The ophthalmic evaluation is very important as sarcoidosis can present with sight-threatening complications.

In conclusion, to our knowledge this is the first lid manifestation of sarcoidosis reported in Nigeria. There is a possibility these cases exist and are underreported. Atypical eyelid lesions with pulmonary involvement should be biopsied and sent for histopathology. Systemic steroids are effective in treating lid involvement of sarcoidosis. The management of sarcoidosis requires a multidisciplinary approach between the physician, dermatologist, and ophthalmologist.

## Financial support and sponsorship

Nil.

## Conflicts of interest

There are no conflicts of interest.

## REFERENCES

1. Baughman RP, Lower EE, Du Bois RM. Sarcoidosis. *Lancet* 2003;361:1111-8.
2. Atmaca LS, Atmaca-Sönmez P, İdil A, Kumbasar OO, Celik G. Ocular involvement in sarcoidosis. *Ocul Immunol Inflamm* 2009;17:91-4.
3. Judson MA, Boan AD, Lackland DT. The clinical course of sarcoidosis: presentation, diagnosis, and treatment in a large white and black cohort in the United States. *Sarcoidosis Vasc Diffuse Lung Dis* 2012;29:119-27.
4. Jabs DA, Johns CJ. Ocular involvement in chronic sarcoidosis. *Am J Ophthalmol* 1986;102:297-301.
5. Dammacco R, Biswas J, Kivelä TT, *et al.* Ocular sarcoidosis: clinical experience and recent pathogenetic and therapeutic advancements. *Int Ophthalmol* 2020;40:3453-67.

Okudo, *et al.*: Eyelid sarcoidosis lesion in Abuja

6. Ohara K, Okubo A, Sasaki H, Kamata K. Intraocular manifestations of systemic sarcoidosis. *Jpn J Ophthalmol* 1992;36:452-7.
7. Obenauf CD, Shaw HE, Sydnor CF, Klintworth GK. Sarcoidosis and its ophthalmic manifestations. *Am J Ophthalmol* 1978;86:648-55.
8. Pasadhika S, Rosenbaum JT. Ocular sarcoidosis. *Clin Chest Med* 2015;36:669-83.
9. Yang SJ, Salek S, Rosenbaum JT. Ocular sarcoidosis: new diagnostic modalities and treatment. *Curr Opin Pulm Med* 2017;23:458-67.
10. Matsou A, Tsaousis KT. Management of chronic ocular sarcoidosis: challenges and solutions. *Clin Ophthalmol* 2018;12:519-32.
11. Collins ME, Vesna Petronic-Rosic V, Sweiss NJ, Marcet MM. Full-thickness eyelid lesions in sarcoidosis. *Case Rep Ophthalmol Med* 2013;2013:3.
12. Brownstein S, Lyszauer AD, Carey WD, Nicolle DA. Sarcoidosis of the eyelid skin. *Canad J Ophthalmol* 1990;25:256-9.
13. Behbehani R, Nipper KS, Eagle RC, Bilyk JR. Systemic sarcoidosis manifested as unilateral eyelid retraction. *Arch Ophthalmol* 2006;124:599-600.
14. Gaspar BL, Gupta K, Singh U. A rare case of eyelid sarcoidosis presenting as an orbital mass. *Indian J Ophthalmol* 2016;64:244-5.
15. Ogunlesi TO, Rankin TB. Sarcoidosis in West Africa. *J Trop Med Hyg* 1961;64:318-20.