

# Acute Acquired Comitant Esotropia after Amniotic Membrane Transplantation in a Case of Vernal Keratoconjunctivitis

Sowmya Raveendra Murthy, Niveditha Nikhil, Khushboo Gupta

Department of Pediatric Ophthalmology and Strabismus, Sankara Eye Hospital, Bangalore, Karnataka, India

## Abstract

Acute acquired comitant esotropia (AACE) is an uncommon form of strabismus in older children and adults. It is characterized by acute onset concomitant esotropia and diplopia. It can occur as a result of monocular occlusion, vision loss, physical stress, or high myopia. We describe a child with chronic vernal keratoconjunctivitis with nonhealing shield ulcer who presented with AACE due to disruption of fusion following amniotic membrane transplantation. To the best of our knowledge, AACE following amniotic membrane transplantation has not been reported till date.

**Keywords:** Acquired comitant esotropia, acute esotropia, amniotic membrane

## INTRODUCTION

Acute acquired concomitant esotropia (AACE) represents a relatively uncommon distinct subtype of esotropia, which occurs in older children, adults, and even the elderly.<sup>[1-3]</sup> It is characterized by acute onset concomitant esotropia and diplopia. Various types of esotropia have been described, such as type I or Swan type, type II or Franceschetti type, and type III or Bielschowsky type.

*Type I or Swan type:* It results from temporary or permanent monocular occlusion or vision loss. The duration of interruption of fusion required to develop acute concomitant esotropia is not clear though.<sup>[2,3]</sup>

*Type II or Franceschetti type:* It is associated with physical or psychologic stress, low hyperopia, and minimal accommodative component with large-angle esotropia.

*Type III or Bielschowsky type:* It is associated with varying degrees of myopia and shows equal deviation at distance and near.<sup>[2,3]</sup>

Vernal keratoconjunctivitis (VKC) is a bilateral, usually seasonal, recurrent, allergic inflammation of the conjunctiva occurring in children and young adults. Treatment of VKC requires a multipronged approach that includes topical or systemic therapy and surgical treatment in the form of corneal plaque removal and

amniotic membrane transplantation (AMT) for severe shield ulcer. AMT is known to be progressively absorbed by 2 weeks.<sup>[4]</sup>

We present a case of VKC with nonhealing shield ulcer, which was treated with AMT. Follow-up after 2 weeks showed development of esotropia in our case.

Occurrence of type I AACE after AMT and patching of the operated eye is rare and hence being reported.

## CASE HISTORY

A 9-year-old boy diagnosed with chronic VKC presented to us with a history of diplopia and convergent squint in left eye. The child had undergone AMT in the left eye 2 weeks earlier for nonhealing shield ulcer. No history of trauma or symptoms of raised intracranial tension were noted. There was no history of squint previously.

**Address for correspondence:** Dr Sowmya Raveendra Murthy, Department of Pediatric Ophthalmology and Strabismus, Sankara Eye Hospital, Bangalore, Karnataka, India.  
E-mail: [drsowmyamurthy@gmail.com](mailto:drsowmyamurthy@gmail.com)

**Received:** 13 January 2021 **Accepted:** 30 September 2021

**Published:** 20 May 2022

This is an open access journal, and articles are distributed under the terms of the Creative Commons Attribution-NonCommercial-ShareAlike 4.0 License, which allows others to remix, tweak, and build upon the work non-commercially, as long as appropriate credit is given and the new creations are licensed under the identical terms.

**For reprints contact:** [reprints@medknow.com](mailto:reprints@medknow.com)

**How to cite this article:** Murthy SR, Nikhil N, Gupta K. Acute Acquired Comitant Esotropia after Amniotic Membrane Transplantation in a Case of Vernal Keratoconjunctivitis. *Niger J Ophthalmol* 2022;30:24-7.

Quick Response Code:

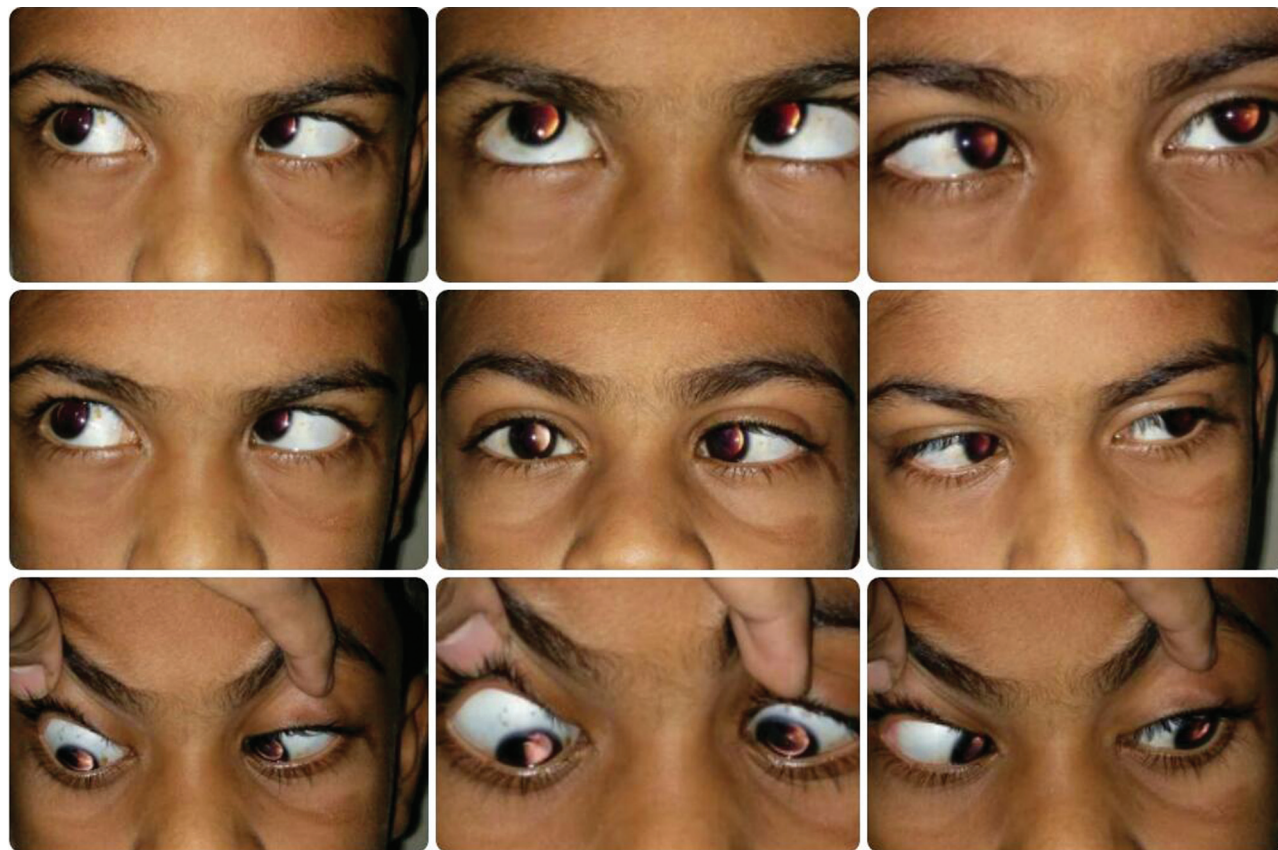


Website:

[www.nigerianjournalofophthalmology.com](http://www.nigerianjournalofophthalmology.com)

DOI:

10.4103/njo.njo\_4\_21



**Figure 1:** Nine-gaze photograph showing left esotropia with normal ocular movements.

On examination, visual acuity was found to be 20/20 N6 in the right eye and 20/40 N6 in the left eye. No abnormal head posture was noted. Alternate prism cover test (APCT) showed 35 prism diopters (PD) of esotropia at distance and 35 to 40 PD of esotropia at near. APCT showed 30-PD esotropia in all gazes, with no A or V pattern. Ocular motility examination showed normal range of movements [Figure 1].

Examination of the anterior segment showed papillae in upper tarsal conjunctiva in both eyes, with healing shield ulcer in the left eye. Results of the posterior segment examination were found to be within normal limits. Cycloplegic refraction (cyclopentolate 0.05% eye drops twice and tropicamide eye drops once were used 10 minutes apart and retinoscopy was performed after last drop) showed (OD) +2.0/-0.50 at 40° and (OS) +2.0/- 0.5 DC at 60°.

Magnetic resonance imaging (MRI) of the brain was advised, which showed cystic lesion of 2.3×1.3 cm in the right cerebellopontine angle suggestive of arachnoid cyst. No aberrant vascular loops or neurovascular conflict was observed. Type I AACE was diagnosed.

The child was prescribed glasses and alternate patching for 2 hours/day. Child was compliant with glasses. At 1-month follow-up, APCT with spectacles showed 35-PD esotropia at distance and 35- to 40-PD esotropia at near. Lateral gaze measurements were 30-PD esotropia. Worth four-dot test (W4DT) showed alternate suppression.

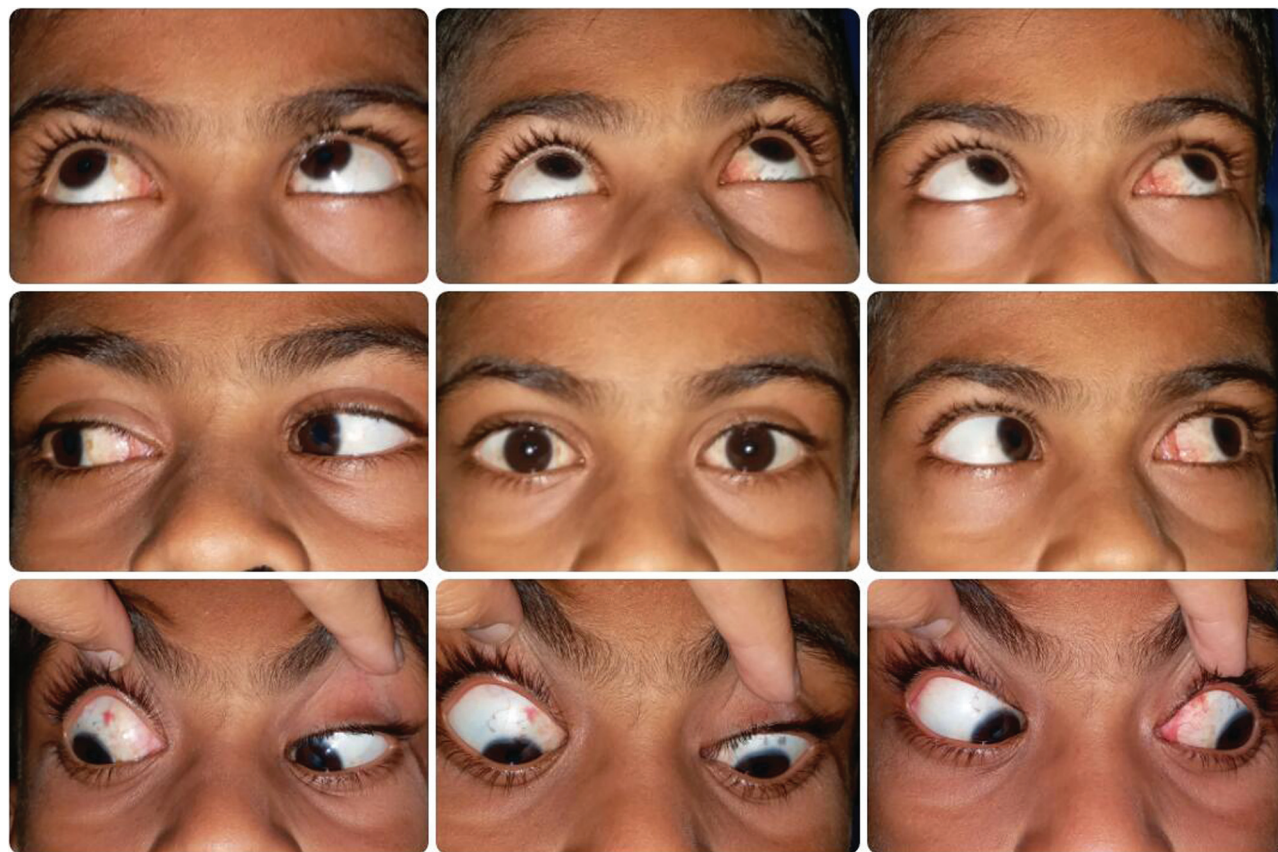
Repeat MRI of the brain performed 4 months later showed persistent right cerebellopontine angle cyst of no significant interval change in size, morphology, or mass effect. After taking neurologist opinion, squint surgery was advised under general anesthesia.

Child was wearing glasses for 5 months before surgery. Bimedial recession of 11 mm from the limbus was performed. The immediate postoperative day cover test revealed orthophoria at distance and near. One month after operation, the child revealed orthophoria at distance and near [Figure 2]. At last follow-up, stereopsis was observed to be 100 seconds of arc.

## DISCUSSION

The AACE is an uncommon form of strabismus occurring in children or young adults.<sup>[5]</sup> Burian and Miller<sup>[1-3]</sup> classified acute onset concomitant esotropia into three distinct categories – types I, II, and III. All have common features of being acute in onset, concomitant, with a relatively large angle of deviation, good binocular potential, and no underlying neurologic disease.

Type I AACE occurs after patching for therapeutic reasons or as a result of monocular or asymmetric visual loss. The resulting strabismus in children and young adults is usually in the form of an esotropia, whereas in adults exotropia predominates.<sup>[5,6]</sup>



**Figure 2:** Nine-gaze photograph showing orthotropia in primary gaze.

Although most children who develop comitant esotropia after occlusion or asymmetric visual loss have hyperopia, several reports emphasize that this may occur in the absence of significant refractive error. Patients with type I AACE will invariably have a history of monocular occlusion or visual loss.

Various intracranial lesions have been reported to be associated with AACE, such as hydrocephalus, Chiari type I malformation, and tumors of cerebellum, brainstem, or sellar region. The presence of A or V pattern and nystagmus should suggest underlying neurologic process.<sup>[6,7]</sup>

A number of treatment options are suggested for AACE including prisms, botox, and surgical correction.

Symptoms of sudden onset of diplopia and esotropia in our patient following patching of the operated eye with AMT suggest type I or Swan type of AACE.

In this case described, AMT (which broke the liable fusion) served as an artificial interruption of fusion. This represents a peripheral obstacle to binocular vision. This is similar to three cases of AACE related to occlusion described by Buch and Vinding<sup>[8]</sup> in a series of 48 cases (same as type I).

As intracranial tumors are also known to be associated with AACE,<sup>[7]</sup> neuroimaging was performed, which in this particular case showed insignificant right

cerebellopontine angle arachnoid cyst. The tumors of the brainstem, cerebellum, and corpus callosum and pituitary region have all been reported to be associated with acute onset esotropia. In our case, the small cyst was not associated with compressive effects that could have caused esotropia.

The angle of strabismus remained almost the same with hyperopic correction; thus, surgery was the choice of correction. Other options such as prisms were not considered because of the large angle of esotropia and botox owing to it being a temporary measure. Fusion was restored successfully by performing strabismus surgery with good stereopsis. The child had orthophoria in the postoperative period, with fusion response on WFDT.

According to most studies in nonneurologic cases of AACE (Swan and Franceschetti types), binocular vision is so good that patients retain good stereoscopic vision, which comes as a clue to diagnose retrospectively.

In conclusion, cases of acute acquired esotropia demand carefully obtaining history and careful examination to look for neurologic causes before planning treatment. Correction of strabismus by surgery as opted in our case is usually successful in restoring fusion and stereopsis.

#### **Financial support and sponsorship**

Nil.

## Conflicts of interest

There are no conflicts of interest.

## REFERENCES

1. Clark AC, Nelson LB, Simon JW, Wagner R, Rubin SE. Acute acquired comitant esotropia. *Br J Ophthalmol* 1989;73:636-8.
2. Burian HM, Miller JE. Comitant convergent strabismus with acute onset. *Am J Ophthalmol* 1958;45:55-64.
3. Sturm V, Menke MN, Knecht PB, Schoffer C. Long-term follow-up of children with acute acquired concomitant esotropia. *J AAPOS* 2011;15:317-20.
4. Malhotra C, Jain AK. Human amniotic membrane transplantation: different modalities of its use in ophthalmology. *World J Transplant* 2014;4:111-21.
5. Chen J, Deng D, Sun Y, *et al.* Acute acquired concomitant esotropia: clinical features, classification, and etiology. *Medicine (Baltimore)* 2015;94:e2273.
6. Hoyt CS, Good WV. Acute onset concomitant esotropia: when is it a sign of serious neurological disease? *Br J Ophthalmol* 1995;79:498-501.
7. Musazadeh M, Hartmann K, Simon F. Late onset esotropia as first symptom of a cerebellar tumor. *Strabismus* 2004;12:119-23.
8. Buch H, Vinding T. Acute acquired comitant esotropia of childhood: a classification based on 48 children. *Acta Ophthalmol* 2015;93:568-74.