

# Pattern of Ocular Pathologies Diagnosed with B-scan Ultrasonography in a Hospital in Rural India

Surekha V. Bangal, Akshay J. Bhandari, Fuzail Siddhiqui

Department of Ophthalmology, Pravara Institute of Medical Sciences and Rural Medical College, Loni, Maharashtra, India

## Abstract

**Context:** B-scan ultrasonography (USG) plays a key role as a valuable diagnostic imaging device in the field of ophthalmology. **Aim:** To study the pattern of ocular pathologies defined by B-scan USG in rural hospital. **Settings and Design:** Hospital-based prospective observational study. **Materials and Methods:** Hospital-based prospective observational study conducted over a period of 2 years. A total of 100 patients were included. **Statistical Analysis Used:** Chi-square test. **Results:** In this study of 100 cases, majority of the cases (57%) were above 40 years of age. There were 54 (54%) male patients and 46 (46%) female patients. The most commonly observed indication for ophthalmic B-scan USG was ocular trauma leading to cataract formation in 45 cases. **Conclusion:** B-scan USG stands as an excellent, reliable, and cost-effective noninvasive radiological diagnostic modality for proper evaluation of a variety of ocular disorders in both clear and opaque media.

**Keywords:** B-scan ultrasonography, ocular pathology, ocular trauma

## INTRODUCTION

B-scan ultrasonography (USG) has played a key role as a valuable diagnostic imaging device in the field of ophthalmology. It gives instantaneous information of lesion in eyes with opaque ocular media. It is an important adjunct in the differentiation of intraocular tumors, even when the media are clear.<sup>[1]</sup> The orbit and the eyeball can be involved in variety of pathologies. Many times, it is difficult to judge the exact nature of the ocular and orbital lesions merely on clinical examination. B-scan USG has increased our ability to detect and differentiate many intraocular and intraorbital disorders. The superficial location of eye with its fluid composition and the advent of high frequency ultrasound make USG ideal for imaging the eye. Imaging provides information about the presence, location, configuration, and their extent.<sup>[2]</sup> Ocular USG uses high frequency sound waves, routinely 7.5–10 MHz, which is transmitted from the probe into the eye.<sup>[3]</sup> The B-scan presents echoes as dots rather than spikes. Intensity of dots relates to the intensity of reflection. It produces a two-dimensional cross-sectional display of the globe and the orbit.<sup>[4]</sup> The present study evaluates characteristic USG features of ophthalmic lesions, defines the anatomical location, and classifies them according to location and etiology. Ocular USG, being a relatively inexpensive, quick, painless, and noninvasive imaging

modality, helps in accurate diagnosis leading to a better visual assurance to the patients, especially in rural area where the study is being conducted. Use of ultrasound in the investigation of the ocular and orbital diseases dated back to 1950s.<sup>[5]</sup> Presence of opaque media prevents adequate ophthalmoscopic visualization of the posterior portion of the globe. Direct visualization of the retro bulbar pathologic lesions with ophthalmoscope is also not possible even with clear media. It is therefore imperative to use alternative imaging modalities for better definition of anatomy and characterization of lesions in these areas. Radiography, USG, computed tomography, and magnetic resonance imaging have been used in this respect. Of these, USG has the advantage of being easily available and affordable, devoid of ionizing radiation and has a good spatial resolution. It could also be performed at the patient's bedside; dynamic study is also possible with real time ultrasound system. In addition ocular biometry for calculation of optical power of artificial lens implants is another advantage of ocular ultrasound.<sup>[5]</sup>

**Address for correspondence:** Dr. Akshay Jawahirlal Bhandari, Assistant Professor, Department of Ophthalmology, Pravara Institute of Medical Sciences and Rural Medical College, Loni - 413736, Ahmednagar, Maharashtra, India.  
E-mail: [kiwis143@gmail.com](mailto:kiwis143@gmail.com)

### Access this article online

#### Quick Response Code:



#### Website:

[www.nigerianjournalofophthalmology.com](http://www.nigerianjournalofophthalmology.com)

#### DOI:

10.4103/0189-9171.195199

This is an open access article distributed under the terms of the Creative Commons Attribution-NonCommercial-ShareAlike 3.0 License, which allows others to remix, tweak, and build upon the work noncommercially, as long as the author is credited and the new creations are licensed under the identical terms.

**For reprints contact:** [reprints@medknow.com](mailto:reprints@medknow.com)

**How to cite this article:** Bangal SV, Bhandari AJ, Siddhiqui F. Pattern of ocular pathologies diagnosed with b-scan ultrasonography in a hospital in rural India. *Niger J Ophthalmol* 2016;24:71-5.

## MATERIALS AND METHODS

A prospective observational study was conducted at the Department of Ophthalmology of a tertiary care teaching hospital located in rural area of western Maharashtra. The study was conducted from September 2012 to July 2014. The patients attending ophthalmology outpatient department (OPD) during the study period and fulfilling the selection criteria mentioned below were included in the study. Ethical clearance was obtained from institutional review board.

### Inclusion criteria

- (1) The patients with suspected posterior segment pathology having an opaque ocular media.
- (2) The patients with clear ocular media in whom the extent of posterior segment pathology needed to be assessed.

### Exclusion criteria

The patients with badly ruptured globe and having active bleeding were excluded.

After a thorough clinical examination, those requiring ophthalmic B-scan as an ancillary investigation were selected for the study purpose. The patients having opaque media in the form of corneal, lenticular, or vitreous opacity were subjected for B-scan evaluation of the clinically suspected pathology lying behind the opaque media. The patients having clear ocular media but having posterior segment pathologies involving retina, optic nerve, choroid, or sclera were also subjected for ophthalmic B-scan evaluation to know the extent and nature of the lesions precisely.

**Procedure:** Information was obtained from all the selected patients using a structured proforma that included name, age, sex, occupation, and relevant history. Ocular examination with slit lamp was performed to make provisional clinical diagnosis. Siemens Sonoline G 60 ultrasound machine with probe frequency of 10 MHz was used for B-scan examination. The patients were subjected to B-scan USG after obtaining informed written consent. The patients were asked to lie down in supine position. They were then instructed to close both eyes. A coupling gel was applied upon the closed eyelids on which the linear array ultrasound probe was placed. After instructing the patient to keep the eye still as if he is staring at the ceiling, and the scanning was commenced. Gain settings were adjusted as per the requirement. Some lesions like vitreous hemorrhage and posterior vitreous detachment were well appreciated when the gain settings were low and some lesions like retinal detachment and intraocular foreign bodies (IOFBs) were better appreciated with higher gain settings. Both eyes were scanned; first, the normal eye was scanned and then the abnormal eye was scanned.

## RESULTS

In this study of 100 cases, majority of the cases (57%) requiring ophthalmic B-scan USG as an important diagnostic tool were above 40 years of age. Of these, 23% cases were between 61 and 70 years of age. Forty-three percentage cases in young age

group of <40 years required B-scan USG for better evaluation of posterior segment and for diagnostic purpose. Mean age was 41.40 years [Figure 1].

Among the 100 cases in this study, 54 (54%) were male patients and 46 (46%) were female patients.

The commonest indication for B-scan ultrasound was ocular trauma with opaque media. Posterior vitreous detachment was observed in 40 cases, followed by retinal detachments in 31 cases. Presence of vitreous hemorrhage was seen in 15 cases, thereby forming an important group requiring B-scan evaluation [Figure 2].

Among the 100 cases enrolled in the study in 85 cases, the ocular media was opaque while in 15 cases, the ocular media was clear. This shows that B-scan is most important for diagnoses when the media is opaque; however, it can also be used to correlate clinical diagnoses with characteristic ultrasonographic features of various ophthalmic disorders when the media is clear. Diminution of vision was the commonest symptom with which the patients presented and it was found in 77 cases [Table 1].

In our study, 15 cases had clear ocular media [Table 2]. Of these, there was a partial retinal detachment in 10 cases. There were 2 cases with pathological myopia while there was 1 case each of thyroid ophthalmopathy and optic nerve head drusen.

In the present study of 100 cases, history of ocular trauma was present in 46 cases. Among these cases, 45 cases had traumatic cataract. Vitreous hemorrhage was present in 14 cases. Posterior vitreous detachment was seen in 15 cases, retinal detachments in 13 cases, dislocated lens in 7 cases, and phthisis bulbi was present in 2 cases. IOFB was found in 3 cases [Table 3].

By applying Z test of difference between two proportions, traumatic cataract is significantly higher than other pathology ( $P < 0.05$ ).

Out of 46 cases with ocular trauma, IOFBs were found in 3 cases, out of which 2 foreign bodies were lodged in the posterior segment in the anterior vitreous.

## DISCUSSION

This observational study was conducted in a teaching hospital based in rural area having tertiary eye care facilities. One hundred

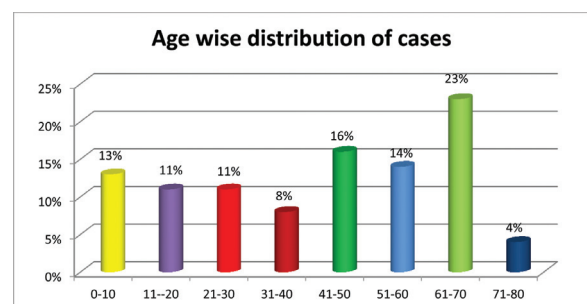


Figure 1: Age-wise distribution of cases

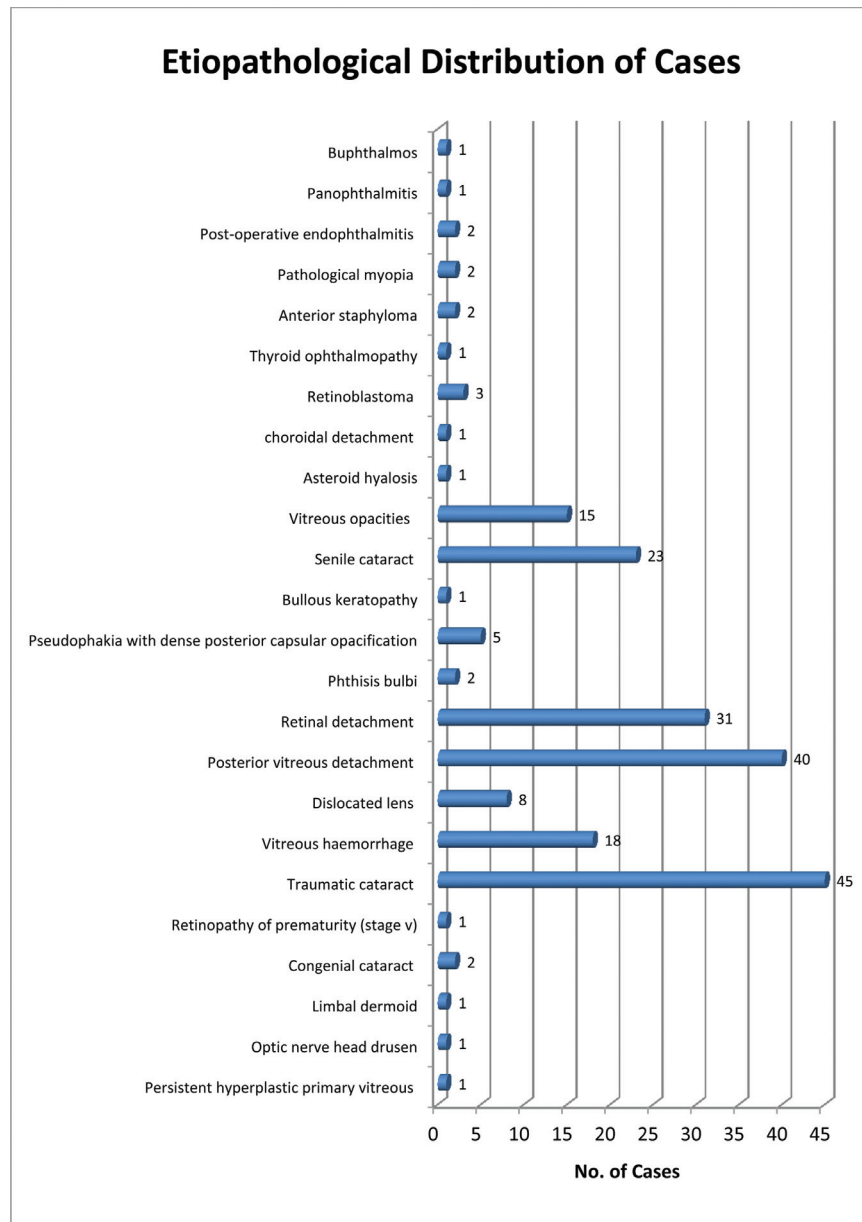


Figure 2: Etiopathological distribution of cases

Table 1: Distribution of cases according to chief ocular symptom at presentation

Symptoms	No. of cases (N = 100)	Percentage (%)
Diminution of vision	77	77
White reflex	6	6
Curtain falling	4	4
Blurring of vision	2	2
Loss of vision	8	8
Photopsia	3	3

consecutive patients presenting for B-scan ultrasound were included in this study. During this study, a number of pathologies, which were not possible to detect on ophthalmoscopy, were diagnosed by USG.

In this study of 100 cases, requiring B-scan as an important diagnostic tool, 57% of cases were above 40 years of age. Sharma<sup>[5]</sup> in his study of 100 cases with intraocular pathologies found 44% cases above 40 years of age. Thus, in our study, more cases were found in the age group of more than 40 years of age as compared to Sharma.<sup>[5]</sup>

In our study, 54 (54%) were male patients and 46 (46%) were female patients. Similarly, in the study conducted by Sharma,<sup>[5]</sup> there were more number (76) (62.29%) of males. This is because males are prone to ocular injuries as they are involved in outdoor occupational activities.

Diminution of vision was the most common chief ocular complaint with which the patients presented and it was found in 77% of the cases in the present study. Similar

**Table 2: Distribution of cases with clear ocular media**

Clinical diagnosis	Ultrasonographic features	No. of cases (%), N = 15
Optic nerve head drusen	High reflective nodule at the optic nerve head with posterior acoustic shadowing persisting at high gain when all other echoes disappear	1 (6.66%)
Limbal dermoid	Hypoechoic lesion in the cornea arising in the infero-temporal corneo-scleral junction	1 (6.66%)
Thyroid ophthalmopathy	Bilateral, asymmetric muscle thickening with medium to high internal reflectivity involving middle and posterior portion of muscle belly	1 (6.66%)
Pathological myopia	Increased axial length with thinning of sclera and angulation of the globe at the posterior pole	2 (13.33%)
Partial retinal detachment	A flat, hyper-echoic, retinal band, which has a narrow acoustically empty space between detached retina and globe wall with tethered, restricted after-movements appreciated even on low gain	10 (66.66%)

**Table 3: Distribution of cases with ocular trauma**

Pathology	Number of cases (N = 46)	Percentage (%)
Traumatic cataract	45	97.83
Vitreous hemorrhage	14	30.43
Dislocated lens	7	15.21
Posterior vitreous detachment	15	32.61
Retinal detachment	13	28.56
Phthisis bulbi	2	4.35
Intraocular foreign body	3	6.52

**Table 4: Comparison of cases with ocular trauma with another study**

Ultrasonography (USG) findings	Rai <i>et al.</i> <sup>[6]</sup> N = 72	Present study N = 46
Traumatic cataract	38.88%	97%
Vitreous hemorrhage	29.16%	30.43%
Posterior vitreous detachment	4.16%	32.61%
Retinal detachments	22.22%	28.56%
Dislocated lens	6.94%	15.21%
Phthisis bulbi	–	4.35%
Intraocular foreign body	13.8%	6.52%

results were found in the study done by Sharma<sup>[5]</sup> where diminution of vision was present in maximum (49.18%) of cases.

B-scan was mainly required for cases with opaque media for diagnosis of posterior segment pathology. Among the 100 cases enrolled in the study in 85% of the cases, the ocular media was opaque while in 15% of the cases, the ocular media was clear. The study conducted by Sharma<sup>[5]</sup> also showed similar results with more (73.77%) cases having an opaque ocular media.

Following is the comparison between the pathologies in cases with ocular trauma found in our study with that done by Rai *et al.*<sup>[6]</sup> [Table 4].

Of the 46 cases with ocular trauma, traumatic cataract was seen in 45 (97.83%) cases, which was significantly higher

than other pathology ( $P < 0.05$ ). In the study conducted by Sharma,<sup>[5]</sup> there were 34 cases with ocular trauma in which there was a dislocation of lens in 5 cases. Similarly, in our study, we found dislocated lens in 8 cases.

B-scan was also useful to locate IOFB and know its size, shape, and nature. In our study, IOFBs were found in 3 (3%) cases, out of which 2 metallic foreign bodies were lodged in the anterior vitreous of size 1.2 mm × 1 mm and 2.1 mm × 2 mm, while one stone particle was found in the anterior chamber of size 1.3 mm × 1.4 mm. In the study conducted by Rai *et al.*<sup>[6]</sup> on ocular trauma, IOFB was present in 13.8% of cases. In the study conducted by Sharma,<sup>[5]</sup> IOFBs were present in 3.27% cases, which is comparable to the present study.

B-scan is particularly useful for examination of posterior segment in cases of opaque ocular media where there is a suspected pathology, which is not evident on clinical examination. In the presence of clear ocular media, B-scan USG provides additional information regarding the extent, size, and nature of the lesion, thus complimenting and confirming the clinical diagnosis.

## CONCLUSION

B-scan USG stands as an excellent, reliable, and cost-effective noninvasive radiological diagnostic modality for proper evaluation of a variety of ocular disorders in both clear and opaque media.

## Financial support and sponsorship

Nil.

## Conflicts of interest

There are no conflicts of interest.

## REFERENCES

- Green RL, Byrne SF. Diagnostic ophthalmic ultrasound [Chapter 14]. Basic Science, Inherited Retinal Disease and Tumors. Retina, vol I. 4th ed. Mosby (Elsevier); 2006. p. 265.
- Bedi DG, Gombus DS, Chaan SN, Singh S. Sonography of the eye. Am J Roentgenol 2006;187:1061-72.

Bangal, *et al.*: Pattern of ocular pathologies diagnosed with B-scan ultrasonography

3. Javed EA, Ali A, Ahmad I, Hussain M. Diagnostic applications of B-scan. *Pak J Ophthalmol* 2007;23:80-3.
4. Ossoinig KS. Quantitative echography. The basis of tissue differentiation. *J Clin Ultrasound* 1974;2:33.
5. Sharma OP. Orbital sonography with its clinico-surgical correlation. *Indian J Radiol Imaging* 2005;15:537-54.
6. Rai P, Shah SI, Cheema AM, Niazi JH, Siddiqui SJ. Usefulness of B-scan ultrasonography in ocular trauma. *Pak J Ophthalmol* 2007;23:136-43.

