

# Pattern and Outcome of Conjunctival Surgeries in Jos University Teaching Hospital, Jos, Nigeria

Ojo Perpetua Odugbo, Patricia Delsat Wade, George Amechi Obikili, Joel James Alada, Caleb Damilep Mpyet

Department of Ophthalmology, Faculty of Medical Sciences, University of Jos, Jos, Nigeria

## ABSTRACT

**Objective:** To assess the output, pattern, and outcome of conjunctival surgeries in Jos University Teaching Hospital over a 7-year period. **Methodology:** The minor ophthalmic surgical records of the hospital were retrospectively reviewed to obtain information on patients who had conjunctival surgery. These included patients' demographics, diagnosis, indications and types of surgery, type of anesthesia, histology report, and outcome. The data were analyzed using Epi Info statistical software version 3.4, Atlanta, Georgia, USA. **Results:** A total of 155 patients and 187 eyes were operated upon; 73 (47.1%) males and a mean age of 39.9 years (standard deviation: 15). Pterygium excision accounting for 104 (55.6%), excisional biopsy 58 (31.0%), and conjunctival flap in 14 eyes (7.5%) were the most common procedures. There was an increase in the proportion of patients who had pterygium surgery with increasing age ( $\chi^2 = 19.6$ ,  $P < 0.001$ ). Pterygium excision also remained the most common conjunctival surgery over the 7-year period with an annual average of 55.1% ( $\chi^2 = 8.4$ ,  $P < 0.001$ ). Most pterygium excision 91 (87.5%) were performed using the bare sclera technique with a 31.6% recurrence rate. The most common conjunctival neoplasia was squamous cell carcinoma 7 (58.3%) and squamous cell papilloma 3 (25%). **Conclusion:** Over half of conjunctival surgeries were pterygium excisions mostly performed using the bare sclera method with a significant recurrent rate; hence, the need for modifications which includes the use of antimetabolites and conjunctival autograft.

**Keywords:** Conjunctiva, outcome, surgery

## INTRODUCTION

The conjunctiva is an ocular adnexal structure and forms a part of the protective anatomical structures of the eye. Conjunctival growths which may be benign or malignant are common indications for surgery. Benign lesions include pterygium, pinguecula, nevus, cysts, teratoma, and squamous cell papillomas among others while invasive squamous cell carcinoma (SCC) of the conjunctiva is a common example of malignant conjunctival growth.

### Address for correspondence

Dr. Ojo Perpetua Odugbo, Department of Ophthalmology, Faculty of Medical Sciences, University of Jos, P.M.B. 2084, Jos, Nigeria.  
E-mail: odugp@yahoo.com

Pterygium, a wing-shaped degenerative fibrovascular growth of conjunctiva which encroaches onto the surface of the cornea, is common in the tropics.<sup>[1]</sup> It may be stable or grow progressively across the cornea to cover the visual axis. Pinguecula is also a degenerative growth occurring at the limbus but does not invade the cornea. Both pterygia and pingueculae occur in the interpalpebral fissure, more often nasally, occasionally temporally and less often, simultaneously nasal and temporal.<sup>[1]</sup> Actinic degeneration of the conjunctiva and cornea related to exposure to ultraviolet light and exacerbated by environmental factors such as wind and dust have been implicated in the pathogenesis

This is an open access article distributed under the terms of the Creative Commons Attribution-NonCommercial-ShareAlike 3.0 License, which allows others to remix, tweak, and build upon the work non-commercially, as long as the author is credited and the new creations are licensed under the identical terms.

**For reprints contact:** reprints@medknow.com

**How to cite this article:** \*\*\*

### Access this article online

Quick Response Code	Website: www.nigerianjournalofophthalmology.com
	DOI: ***

of pterygium. Prolonged exposure to these risk factors also causes corneal and conjunctival drying by disruption of the tear film.<sup>[2]</sup> Chronic irritation leads to a chronic inflammatory cell infiltration with edema, attempt at repair, and cell-induced angiogenesis. These processes are responsible for the fibrovascular reaction characteristic of a pterygium.<sup>[3]</sup> Other risk factors for pterygium include the use of traditional eye drops, exposure to chemical irritants, and a family history of pterygium.<sup>[4-6]</sup> Pterygium causes visual impairment by inducing significant corneal astigmatism or by actually invading the visual axis.<sup>[1]</sup> In Nigeria, 1% of moderate visual impairment and 0.5% of blindness are attributed to pterygium.<sup>[7]</sup> Various community-based studies among adults revealed a prevalence of pterygium between 2.7% and 8.3%.<sup>[4,5,8-13]</sup> Hospital-based studies in South Western Nigeria revealed that pterygium accounted for 0.8% of cause of blindness among new patients<sup>[14]</sup> and was a cause of ocular morbidity in 6.4% of elderly patients in a primary eye care clinic<sup>[15]</sup> while in Northern Nigeria, pterygium accounted for 11% of cases of red eye in a tertiary eye care facility.<sup>[16]</sup> Akinsola *et al.* reported pterygium as the leading conjunctival mass presenting to their facility.<sup>[17]</sup> A survey of pediatric ophthalmic diagnosis in an eye care facility in Southern Nigeria showed that pterygium accounted for 1.06% of cases.<sup>[18]</sup>

The management of pterygium depends on the patient's symptoms and the pterygium's rate of progression. The primary indication for surgical removal of pterygia is a threat of or actual visual loss. Other indications for surgical removal include Chronic inflammation that is not responding to medical therapy and cosmetic blemish.<sup>[1]</sup> Potential complications of pterygium excision include recurrence which occasionally could be worse than the original disease.

Ocular surface squamous neoplasia (OSSN) is a broad term encompassing conjunctival intraepithelial neoplastic (CIN) lesions and invasive SCC of conjunctiva and cornea. The former (CIN) includes varying grades of dysplasia, ranging from mild, moderate, severe dysplasia to carcinoma *in situ*.<sup>[19]</sup> Factors that have been implicated in the development of OSSN include advanced age, male gender, exposure to solar ultraviolet radiation, infection with human papillomavirus, immunosuppression, and infection with human immunodeficiency virus (HIV).<sup>[19]</sup> Other oncogenic viruses like Kaposi sarcoma-associated herpes virus and Epstein-Barr virus have been found in OSSN.<sup>[20]</sup> The disease entity "OSSN," also known as an indolent disease of adult males, presents more commonly in the interpalpebral area of the perilimbal conjunctiva and can encroach on the cornea; OSSN

can also show isolated corneal involvement.<sup>[21]</sup> It has shown changing trends in its clinical presentation and progression with an upsurge of HIV infection which led to an increase in the incidence of OSSN. Thus, OSSN has been recognized to be strongly associated with HIV infection;<sup>[21]</sup> furthermore, HIV infection is now established as a risk factor for the development of squamous cell neoplasia of the conjunctiva based on studies from Rwanda, Malawi, and Uganda.<sup>[22,23]</sup> OSSN runs a more aggressive and invasive course in HIV patients requiring enucleation or even exenteration.<sup>[24]</sup> Conjunctival growth may also be a manifestation of systemic infections or malignancies such as Kaposi sarcoma and lymphomas.

This study examines the various conjunctival pathologies presenting to our unit over the past 7 years, their management and outcome with the aim of evaluating the outcome of management and the need to modify management modalities or otherwise.

## METHODOLOGY

The minor ophthalmic surgical database was retrospectively reviewed to obtain information on all patients who had conjunctival surgery from January 1, 2008 to December 31, 2014. The information obtained included patients' demographics, clinical features, preoperative diagnosis, associated ocular co-morbidity, indications for surgery, type and date of surgery, type of anesthesia administered, and the outcome of management. The total number of minor ophthalmic surgeries within the study period was also computed. The data obtained were entered into Epi Info statistical software, version 3.4 (Epi Info™, Atlanta, Georgia, USA) and analyzed after the data entry was validated by double entry. Descriptive statistics was used to yield frequencies, percentages, and proportions. Analytical statistics was by Chi-square test, and a  $P < 0.05$  was considered statistically significant. The demographics of patients, the output and types of conjunctival surgeries performed were assessed. Ethical approval was obtained from the Institutional Medical Research Ethics Committee.

## RESULTS

A total of 155 persons comprising 73 (47.1%) males and 82 (52.9%) females had conjunctival surgery within the study period [Figure 1], with an average age of 39.9 years (standard deviation [SD]: 15); age range (mean  $\pm$  2 SD) was 9.9–69.9 years, and the age group 31–40 years had the largest proportion of patients 49 (31.6%). Furthermore, 32 persons (20.6%) had conjunctival surgeries in both eyes with a total of 187 eyes.

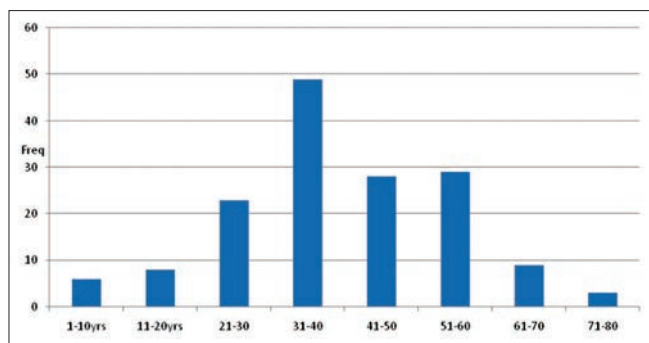


Figure 1: Age distribution of study population

There were eight primary conjunctival morbidities [Table 1] and three other types of morbidity which were not primarily a conjunctival morbidity. The most common indication for surgery included pterygium in 104 (55.6%) eyes and conjunctival mass in 51 (27.3%) eyes. However, 18 (9.6%) eyes had either an anterior segment or orbital morbidity that required conjunctival surgery.

A total of 584 minor ophthalmic surgeries were performed within the study period. Of these, 187 (32%) were conjunctival surgeries. Nine types of conjunctival surgeries were performed [Table 2]; pterygium excision 104 (55.6%), excisional biopsy of other conjunctival growth 58 (31.0%), and conjunctival flap 14 (7.5%) were the most common conjunctival surgeries, 95.6% of these were performed under local anesthesia.

Eighty persons comprised of 36 (45%) males and 44 (55%) females had pterygium excision. Their age was bimodally distributed with one peak at 31–40 years and another peak at 51–60 years [Figure 2]. Their mean age was 45.6 years (SD: 17); 86.2% of patients were aged >30 years while only 12.5% were aged >60 years. No patient was aged ≤20 years. There was an increase in the proportion of patients who had pterygium surgery with increasing age ( $\chi^2 = 19.6, P < 0.001$ ). Pterygium excision was the most common conjunctival surgery within the study period with an annual average of 55.1% ( $\chi^2 = 8.4, P < 0.001$ ). Of 104 eyes that had pterygium excision, only 2 (1.9%) had the lesion on the temporal conjunctiva, the location was nasal in 102 (99.1%) eyes; 4 (3.8%) eyes had recurrent pterygia. Most pterygium excisions 91 (87.5%) were performed using the bare sclera technique, 8 (7.7%) were combined with primary conjunctival autologous grafting, and 5 (4.8%) were performed with intraoperative application of mitomycin-C to the sclera bed. Up to 31.6% of eyes (all operated by bare sclera technique) had recurrent pterygium.

Fourteen patients who had a biopsy of conjunctival mass had their case files reviewed, of these 12 patients had

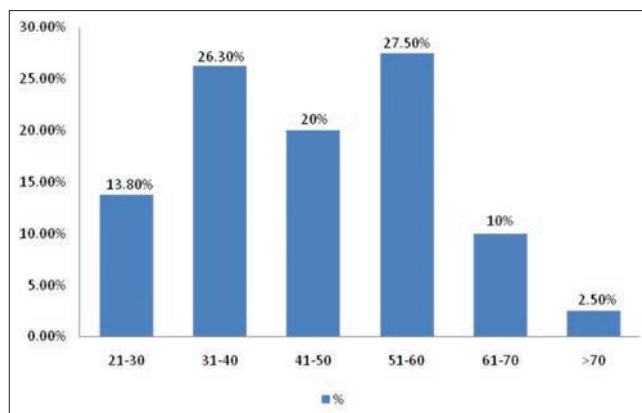


Figure 2: Age distribution of patients who had pterygium

Table 1: Types and distribution of preoperative conjunctival morbidities

Conjunctival morbidity	n (%)
Pterygium	104 (55.6)
Conjunctival mass	51 (27.3)
Conjunctival cyst	4 (2.1)
Pinguecula	2 (1.1)
Limbal dermoid cyst	2 (1.1)
Conjunctival nevus	2 (1.1)
Pseudopterygium	1 (0.5)
Conjunctival laceration	1 (0.5)
Conjunctival suture	1 (0.5)
Subconjunctival hemorrhage	1 (0.5)
Other (anterior segment and orbital diseases that required conjunctival surgery)	18 (9.6)
Total	187 (100)

Table 2: Types and distribution of conjunctival surgical procedures

Conjunctival surgical procedure	n (%)
Pterygium excision	104 (55.6)
Excision biopsy	57 (31.0)
Conjunctival flap	15 (7.5)
Conjunctivectomy	5 (2.1)
Pinguecula excision	2 (1.1)
Conjunctival exploration and repair	1 (1.1)
Incision biopsy	1 (0.5)
Pseudopterygium excision	1 (0.5)
Conjunctival suture removal	1 (0.5)
Total	187 (100)

their histopathology reports ready. All had morbidity in one eye. Of these 12 eyes, SCC was the definitive diagnosis in 7 (58.3%) eyes, squamous cell papilloma in 3 (25%) eyes, and junctional nevus and dermoid cysts in 1 (8.3%) eye each. The mean age of patients with SCC and squamous cell papilloma were 42.6 and 39 years, respectively. OSSN accounted for 83.3% of histological diagnosis of conjunctival neoplasia. No case of recurrence was observed among these eyes within the study period.

Of 18 eyes that had conjunctival surgeries as a result of a nonconjunctival pathology, 14 (77.8%) were conjunctival flap surgeries, while 4 (22.2%) were conjunctivectomy for Mooren's ulcer. Figure 3 shows the indications for conjunctival flap surgery in 14 eyes. Corneal ulcer/descemetocoele and Mooren's ulcer were the main indications for conjunctival flap surgeries observed in 5 (45.5%) and 3 (27.3%) eyes, respectively.

## DISCUSSION

Conjunctival surgeries constituted about one-third of minor ophthalmic surgical procedures within the study period. The observed mean age (39.9 years) of the study group is comparable to 42.9 years observed by Akinsola *et al.* in Lagos.<sup>[17]</sup>

Over half of conjunctival surgical morbidities were pterygia. This is not surprising as pterygium is common in tropical Africa. Proximity to the equator is a known risk factor. Our facility is located within latitude 8°22' N and 100°24' N and longitude 8°32' E and 100°24' E and has a near temperate climate with an average temperature between 18.7°C and 31.7°C. It serves as a referral center for the host state and five neighboring states with climatic conditions which favor the incidence of pterygia. Furthermore, farming (an outdoor occupation) is a major occupation in the region. The proportion of patients with pterygia (55.6%) observed in this study is comparable to 42% observed by Pola *et al.* in Zimbabwe<sup>[25]</sup> but contrasts to 89.5% reported by Akinsola *et al.* in Lagos.<sup>[17]</sup> This may be due to the fact that the Lagos study assessed preoperative conjunctival growth while our study assessed mainly surgical patients. Not all patients with pterygium had surgery. The mean age of patients who had pterygium excision (45.6 years) is comparable to 51.8 years and 40 years observed by Fadamiro *et al.* in Ado-Ekiti, South Western Nigeria and Moukoury *et al.* in Cameroun, respectively.<sup>[26,27]</sup> We also observed that majority of these patients (86.2%) were aged over 30 years which

is also comparable to findings in Cameroun where it was observed that 92% of the patients with pterygium were older than 30 years.<sup>[27]</sup> This is likely due to the effect of prolonged exposure to the established risk factors. However, in contrast to report by Adio *et al.* in Southern Nigeria,<sup>[18]</sup> there was no patient in the pediatric age group who had pterygium surgery in our study. Even though studies have shown that more males have a higher incidence and prevalence of pterygium compared to females,<sup>[28,29]</sup> we observed that more females (55%) had pterygium excision comparable to 66.5% observed by Fadamiro *et al.* in South Western Nigeria.<sup>[26]</sup> This may be due to the fact that females are more conscious of cosmetic blemishes than their male counterparts, pterygium surgical services is also relatively affordable in the study center.

Only 1.9% of pterygia were located on the temporal conjunctiva, similar to 2.4% observed among Arabian patients with pterygia.<sup>[30]</sup> Surgery aims at removing the pterygium, restoring the conjunctival anatomy, and leaving the corneal surface as smooth and clear as possible. Numerous techniques are being used to achieve this goal. In this study, most (87.5%) pterygium surgeries were performed using the bare sclera technique. This technique is still in use by many surgeons worldwide in spite of the attendant high recurrence rate. The recurrence rate of 31.6% following excision by bare sclera technique observed in our study is close to 40% observed by Ashaye in Ibadan.<sup>[31]</sup> Conjunctival graft performed as a primary procedure with pterygium excision reduces the recurrence rate from upward of 70–80% to 5–15%.<sup>[1,27,32]</sup> Conjunctival autograft was introduced in our center in 2008 due to a high recurrence rate from the bare sclera technique. Intraoperative mitomycin-C application to the bare sclera bed after pterygium excision gives good results;<sup>[33]</sup> however, it has been associated with devastating ocular complications which include scleromalacia.<sup>[1]</sup> In the Lagos study, only 4.3% of eyes had pterygium excision with bare sclera technique while 95.7% had either pterygium excision with conjunctival autograft or with adjuvant therapy. Expectedly the overall rate of recurrence was low (13.2%).<sup>[17]</sup> The Lagos and Ado-Ekiti studies also revealed a low recurrence rate of 5% and 3.7% in eyes with conjunctival autograft, respectively.<sup>[17,26]</sup> Bekibebe *et al.* reported a slightly lower recurrence rate with the use of five fluorouracil compared to conjunctival autograft.<sup>[34]</sup> Akinsola *et al.* reported a recurrence rate of 33.3% in eyes that were operated with bare sclera technique.<sup>[17]</sup> The latter is comparable to the recurrence rate observed in this study.

We observed that only 1.1% of eyes had pinguecula excision, which is quite low compared to 8.7% observed

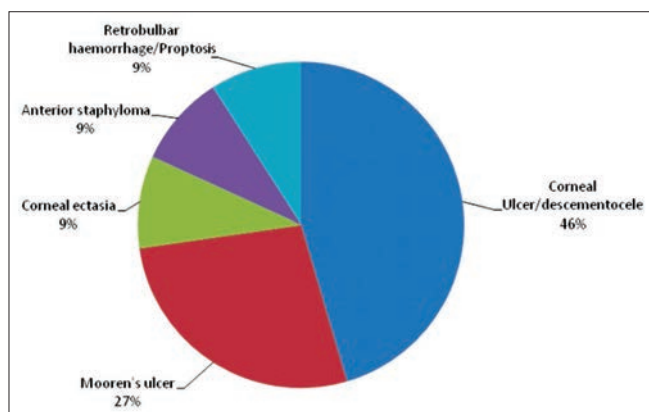


Figure 3: Indication for conjunctival flap surgery



by Akinsola *et al.* in Lagos.<sup>[17]</sup> Again the different study groups (i.e., surgical versus clinic patients) could be responsible for this difference. Pinguecula, though a very common conjunctival morbidity, is not a common indication for surgery like pterygium. Indications for surgery will include recurrent inflammation and cosmesis.

Conjunctival neoplasia was the indication for surgery in a quarter of patients; this is higher than 0.5% observed by Akinsola *et al.* in Lagos<sup>[17]</sup> and lower than 53% reported by Pola *et al.* in Zimbabwe.<sup>[25]</sup> The higher prevalence of systemic illnesses like HIV/acquired immunodeficiency syndrome in Southern Africa may be the reason for the observed difference between our study and the study in Zimbabwe.<sup>[35]</sup> SCC of the conjunctiva was the most common (58.3%) OSSN in our study; this is similar to 56.6% observed by Ackuaku-Dogbe in Ghana.<sup>[36]</sup> The mean age of patients with OSSN (42.6 years) in our study is, however, in contrast to a mean age range of 32–37 years observed in Harare, Zimbabwe.<sup>[21,25]</sup> Other studies have reported OSSN as the first clinical presentation of HIV in young patients.<sup>[23,37]</sup> Late presentation and the fact that our patients were all surgical patients could be responsible for the observed difference.

Patients with a definitive diagnosis of squamous cell papilloma of the conjunctiva had a mean age of 39.9 years, similar to the report of Ogun *et al.* in Ibadan where this neoplasm was found commonly in patients in their fourth decade of life.<sup>[38]</sup> It was the second most common type of OSSN observed in our study. Squamous cell papilloma is a benign neoplasm of the squamous epithelium of the conjunctiva characterized by finger-like projections comprised a fibrovascular core covered by acanthotic squamous epithelium.<sup>[39]</sup>

More patients had conjunctival cysts (2.1%) and limbal dermoid cysts (1.1%) in our study compared to 0.8% and 0.2% observed in Lagos, respectively,<sup>[17]</sup> but similar to 3.4% (conjunctival cysts) and 1.1% (limbal dermoid cysts) observed in Ghana.<sup>[36]</sup>

One eye (0.5%) each had conjunctival laceration and subconjunctival hemorrhage warranting surgical intervention. The conjunctiva can be easily affected in ocular trauma. Conjunctival lacerations must be carefully evaluated to ensure there is no underlying full thickness sclera laceration which may be obscured by significant subconjunctival hemorrhage.<sup>[1]</sup> Only one case of conjunctival laceration had to be sutured in theater in the period under review as most conjunctival lacerations are treated conservatively with topical antibiotics and occasionally pressure patching.

The main indications for conjunctival flap surgeries were corneal ulcer/descemetocele and Mooren's ulcers that were associated with corneal perforation. Chronic corneal surface diseases are an important and common indication for conjunctival surgery.<sup>[1]</sup> Participants with perforated Mooren's ulcers who had conjunctival flap surgery in this study were all relatively young (aged <40 years). Mooren's ulcer is associated with autoimmune disease in some but not all patients. The West African type of ulcer rodens has a higher prevalence and a tendency toward perforation.<sup>[40]</sup> Conjunctival flap surgeries help to improve chronically compromised corneal surfaces. It is an effective method to replace damaged or nonexistent corneal epithelium with more resilient conjunctiva. The aim is to stabilize the eye, not to immediately improve vision. Conjunctivectomy is also a modality of treating Mooren's ulcer.<sup>[41,42]</sup>

The hospital-based nature of this study limits the inference which can be made on the types of conjunctival surgical morbidity in our environment. This will be better accomplished by a community-based study.

## CONCLUSION

Conjunctival surgeries constituted about one-third of minor ophthalmic surgeries in our center. Over half of conjunctival surgeries were pterygium excision mostly performed using the bare scleral method, with a significant recurrence rate; hence, the need for modification with the use of antimetabolites and conjunctival autograft. OSSN was the most common conjunctival neoplasia among patients with conjunctival surgeries in our setting.

## Financial support and sponsorship

Nil.

## Conflicts of interest

There are no conflicts of interest.

## REFERENCES

1. Spaeth GL. Ophthalmic Surgery: Principles and Practice. 3<sup>rd</sup> ed. Philadelphia: WB Saunders; 2003. p. 127-34.
2. Balogun MM, Ashaye AO, Ajayi BG, Osuntokun OO. Tear break-up time in eyes with pterygia and pingueculae in Ibadan. West Afr J Med 2005;24:162-6.
3. Hill JC, Maske R. Pathogenesis of pterygium. Eye (Lond) 1989;3(Pt 2):218-26.
4. Okoye OI, Umeh RE. Eye health of industrial workers in Southeastern Nigeria. West Afr J Med 2002;21:132-7.
5. Omoti AE, Waziri-Erameh JM, Enock ME. Ocular disorders in a petroleum industry in Nigeria. Eye (Lond) 2008;22:925-9.
6. Anguria P, Ntuli S, Interewicz B, Carmichael T. Traditional eye medication and pterygium occurrence in Limpopo province. S Afr Med J 2012;102:687-90.

7. Abdull MM, Sivasubramaniam S, Murthy GV, Gilbert C, Abubakar T, Ezelum C, *et al.* Causes of blindness and visual impairment in Nigeria: The Nigeria national blindness and visual impairment survey. *Invest Ophthalmol Vis Sci* 2009;50:4114-20.
8. Ajayi IA, Omotoye OJ. Pattern of eye diseases among welders in a Nigeria community. *Afr Health Sci* 2012;12:210-6.
9. Bekibele CO, Ajav R, Asuzu MC. Eye health of professional drivers of a Nigerian University. *Niger Postgrad Med J* 2009;16:256-9.
10. Wade PD, Oduqbo OP, Velle LD, Kyari F. Prevalence and causes of ocular morbidity among commercial intercity vehicle drivers in Jos, Nigeria. *Niger J Med* 2011;52:123-7.
11. Adekoya BJ, Owoeye JF, Adepoju FG, Ajaiyeoba AI. Pattern of eye diseases among commercial intercity vehicle drivers in Nigeria. *Niger J Ophthalmol* 2008;16:55-9.
12. Oladehinde MK, Adeoye AO, Adegbehingbe BO, Onakoya AO. Visual functions of commercial drivers in relation to road accidents in Nigeria. *Indian J Occup Environ Med* 2007;11:71-5.
13. Nwosu SN. Ocular problems of young adults in rural Nigeria. *Int Ophthalmol* 1998;22:259-63.
14. Otulana TO. Blindness and visual impairment in Remo, Ogun State, Nigeria: A hospital-based study. *Niger Postgrad Med J* 2012;19:153-6.
15. Adebusey LA, Owoaje ET, Ladipo MM, Adeniji AO. Visual morbidities among elderly patients presenting at a primary care clinic in Nigeria. *West Afr J Med* 2011;30:118-20.
16. Lawan A. Causes of red eye in Aminu Kano Teaching Hospital, Kano-Nigeria. *Niger J Med* 2009;18:184-5.
17. Akinsola FB, Mbadugha CA, Onakoya AO, Adefule-Ositelu AO, Aribaba OT, Rotimi-Samuel A. Pattern of conjunctival masses seen at Guinness Eye Centre Luth Idi-Araba. *Nig Q J Hosp Med* 2012;22:39-43.
18. Adio AO, Alikor A, Awoyesuku E. Survey of pediatric ophthalmic diagnoses in a teaching hospital in Nigeria. *Niger J Med* 2011;20:105-8.
19. Lee GA, Hirst LW. Ocular surface squamous neoplasia. *Surv Ophthalmol* 1995;39:429-50.
20. Simbiri KO, Murakami M, Feldman M, Steenhoff AP, Nkomazana O, Bisson G, *et al.* Multiple oncogenic viruses identified in ocular surface squamous neoplasia in HIV-1 patients. *Infect Agent Cancer* 2010;5:6.
21. Karcioqglu ZA, Wagoner MD. Demographics, etiology, and behavior of conjunctival squamous cell carcinoma in the 21<sup>st</sup> century. *Ophthalmology* 2009;116:2045-6.
22. Thomas JO. Acquired immunodeficiency syndrome-associated cancers in Sub-Saharan Africa. *Semin Oncol* 2001;28:198-206.
23. Spitzer MS, Batumba NH, Chirambo T, Bartz-Schmidt KU, Kayange P, Kalua K, *et al.* Ocular surface squamous neoplasia as the first apparent manifestation of HIV infection in Malawi. *Clin Experiment Ophthalmol* 2008;36:422-5.
24. Shields CL, Ramasubramanian A, Mellen PL, Shields JA. Conjunctival squamous cell carcinoma arising in immunosuppressed patients (organ transplant, human immunodeficiency virus infection). *Ophthalmology* 2011;118:2133-7.
25. Pola EC, Masanganise R, Rusakaniko S. The trend of ocular surface squamous neoplasia among ocular surface tumour biopsies submitted for histology from Sekuru Kaguvi Eye Unit, Harare between 1996 and 2000. *Cent Afr J Med* 2003;49:1-4.
26. Fadamiro CO, Ajite KO, Ajayi AI, Omotoye OJ. Pterygium excision with conjunctival autograft: Our technique. *Niger J Ophthalmol* 2012;20:38-41.
27. Moukourv NE, Epee E, Nsangou JFI, Noa NTB. Pterygium in a tropical region. Analysis of 344 cases in Cameroon. *Bull Soc Belge Ophthalmol* 2009;311:11-5.
28. Wong TY, Foster PJ, Johnson GJ, Seah SK, Tan DT. The prevalence and risk factors for pterygium in an adult Chinese population in Singapore: The Tanjong Pagar survey. *Am J Ophthalmol* 2001;131:176-83.
29. McCarty CA, Fu CL, Taylor HR. Epidemiology of pterygium in Victoria, Australia. *Br J Ophthalmol* 2000;84:289-92.
30. Dolezalová V. Is the occurrence of a temporal pterygium really so rare? *Ophthalmologica* 1977;174:88-91.
31. Ashaye AO. Pterygium in Ibadan. *West Afr J Med* 1991;10:232-43.
32. Kenyon KR, Wagoner MD, Hettinger ME. Conjunctival autograft transplantation for advanced and recurrent pterygium. *Ophthalmology* 1985;92:1461-70.
33. Mpyet C, Oko H. Results of intra-operative 0.5mg/ml mitomycin C with 20mg depo steroid in the treatment of primary pterygium. *Cent Afr J Med* 2000;46:330-2.
34. Bekibele CO, Baiyeroro AM, Olusanya BA, Ashaye AO, Oluleye TS. Pterygium treatment using 5-FU as adjuvant treatment compared to conjunctiva autograft. *Eye (Lond)* 2008;22:31-4.
35. UNICEF. Prevalence of HIV in Zimbabwe. Available from: [http://www.unicef.org/infobycountry/Zimbabwe\\_statistics.html](http://www.unicef.org/infobycountry/Zimbabwe_statistics.html). [Last accessed on 2015 Jul 25].
36. Acquaku-Dogbe E. Histopathological features of tumours of the orbit and adnexia seen in Korle-Bu teaching Hospital Ghana. *West Afr J Med* 2012;31:58-62.
37. Pradeep TG, Gangasagara SB, Subbaramaiah GB, Suresh MB, Gangashettappa N, Durgappa R. Prevalence of undiagnosed HIV infection in patients with ocular surface squamous neoplasia in a tertiary center in Karnataka, South India. *Cornea* 2012;31:1282-4.
38. Ogun OA, Ogun GO, Bekibele CO, Akang EE. Squamous papillomas of the conjunctiva: A retrospective clinicopathological study. *Niger J Clin Pract* 2012;15:89-92.
39. Farah S, Baum TD, Conlon MR, Alfonso EC, Starck T, Albert D. Tumours of the cornea and conjunctiva. In: Albert DM, Jakobiec FA, editors. *Principles and Practice of Ophthalmology*. 2<sup>nd</sup> ed. Pennsylvania: W.B. Saunders; 2000. p. 1002-19.
40. Stilma JS. Conjunctival excision or lamellar scleral autograft in 38 Mooren's ulcers from Sierra Leone. *Br J Ophthalmol* 1983;67:475-8.
41. Chen J, Xie H, Wang Z, Yang B, Liu Z, Chen L, *et al.* Mooren's ulcer in China: A study of clinical characteristics and treatment. *Br J Ophthalmol* 2000;84:1244-9.
42. Nguyen QD. Mooren's Ulcer: Diagnosis and Management. Available from: <http://www.uveitis.org/medical/articles/casez>. [Last accessed on 2015 Jun 04].