

VITREO-RETINA

Prevalence, Pattern, and Risk Factors for Retinal Vascular Occlusions in a Tertiary Hospital in Jos, Nigeria

Olukorede O. Adenuga, Alice V. Ramyil, Ojo P. Odugbo, Funmilayo J. Oyediji

Department of Ophthalmology, Jos University Teaching Hospital, Jos, Plateau State, Nigeria. E-mail: korexmed@yahoo.com

Objective: Retinal vascular occlusions are the second most common retinal vascular diseases following diabetic retinopathy.^[1] They are associated with several systemic and ocular pathologies and are significant causes of visual loss.^[1-3] The aim of this study was to determine the prevalence, pattern, and risk factors for retinal vascular occlusions in a tertiary hospital in Jos, Nigeria.

Methods: A retrospective review of all cases of retinal vascular occlusions seen in the eye clinic from January 2011 to December 2014.

Results: Three thousand eight hundred twenty-one new patients were seen during the study period, and there were 52 (1.36%) cases of retinal vascular occlusions. Only the case files of 44 (84.6%) patients were available and were analyzed. These were made up of 17 (39%) males and 27 (61%) females with a mean age of 53.5 years. These had a total of 46 retinal vascular occlusions comprised of 37 (80.4%) retinal vein occlusions, 8 (17.4%) central retinal artery occlusions, and a case (2.2%) of combined central retinal artery and vein occlusion [Figure 1]. Hypertension and diabetes were the most common systemic risk factors while glaucoma was the most common ocular association [Table 1]. Presenting visual acuity (VA) ranged from no light perception to 6/18 with 31 (54%) eyes having a VA of <3/60. Ocular complications such as neovascularization, macular edema, neovascular glaucoma, and vitreous hemorrhage were documented in 32 (70%) eyes.

Table 1: Systemic and ocular associations

Type of VO	HT n (%)	DM n (%)	HIV n (%)	SCD n (%)	Glaucoma n (%)	Others n (%)
CRVO	17 (53)	4 (36.4)	-	-	3 (33.3)	-
BRVO	4 (13)	2 (18.2)	-	-	3 (33.3)	-
HRVO	8 (25)	4 (36.4)	-	-	2 (22.2)	-
CRAO	3 (9)	1 (9)	2 (100)	-	1 (11.1)	6 (100)
CRAO+CRVO	-	-	-	1 (100)	-	-
Total	32 (100)	11 (100)	2 (100)	1 (100)	9 (100)	6 (100)

VO: Vascular occlusion, HT: Hypertension, DM: Diabetes mellitus, HIV: Human immunodeficiency virus, SCD: Sickle cell disease, HRVO: Hemiretinal vein occlusion, CRVO: Central retinal vein occlusion, BRVO: Branch Retinal vein occlusion

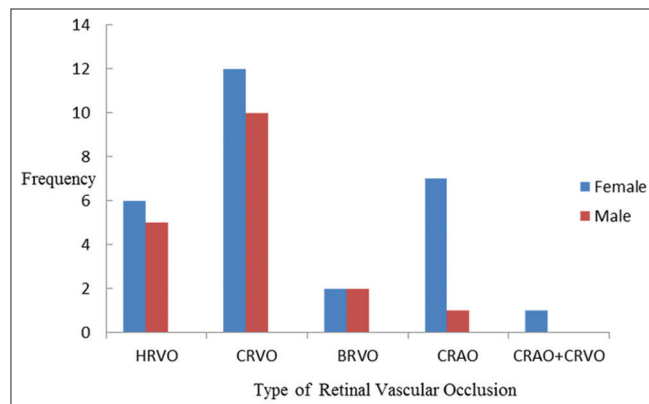


Figure 1: Sex distribution of retinal vascular occlusions. HRVO: Hemiretinal vein occlusion; CRVO: Central retinal vein occlusion; BRVO: Branch retinal vein occlusion; CRAO: Central retinal artery occlusion

Conclusion: Retinal vascular occlusions are uncommon in Jos. They are associated with significant systemic pathologies and lead to severe visual loss. A comprehensive management of patients with retinal vascular occlusions is, therefore, necessary to correct associated diseases or predisposing risk factors that could lead to local recurrences. Early diagnosis and treatment of these associated systemic disorders in the general population will also help in reducing the incidence of these conditions and resultant blindness.

REFERENCES

- Lang GE, Spraul CW. Risk factors for retinal occlusive diseases. *Klin Monbl Augenheilkd* 1997;211:217-26.
- Lim LL, Cheung N, Wang JJ, Islam FM, Mitchell P, Saw SM, *et al.* Prevalence and risk factors of retinal vein occlusion in an Asian population. *Br J Ophthalmol* 2008;92:1316-9.
- Fiebai B, Ejimadu CS, Komolafe RD. Incidence and risk factors for retinal vein occlusion at the University of Port Harcourt Teaching Hospital, Port Harcourt, Nigeria. *Niger J Clin Pract* 2014;17:462-6.

Mobile Phones for Retinopathy of Prematurity Screening in Lagos, Nigeria, Sub-Saharan Africa

Oluleye T. S., Rotimi-Samuel A.¹, Akinshola F. B.¹, Adefule-Ositelu O. A.¹, Onakoya O. A.¹, Aribaba O. T.¹, Musa K. O.¹, Adenekan O. A.¹, Ilo O. T.¹, Abikoye T. M.¹, Eminike A. I.¹

Department of Ophthalmology, Retinal and Vitreous Unit, University College Hospital, Ibadan, ¹Department of Ophthalmology, Guinness Eye Center, Lagos University Teaching Hospital, Lagos, Nigeria. E-mail: t_oluleye@yahoo.co.uk

Introduction: Retinopathy of prematurity (ROP) was initially thought to be rare in Sub-Saharan Africa. The first reported cases in Nigeria were noted in blind schools study with an incidence of 0.5%.^[1] Another study in Ibadan, Southwest Nigeria noted a prevalence of 5.5%.^[2] A more recent study in Port Harcourt, Southern Nigeria, and the middle belt region recorded prevalence rates of 47.2% and 89.6%, respectively.^[3,4] Reasons given for the rarity of ROP included the nonsurvival of the preterms due to inadequate infrastructures. The other reason given was the nonavailability of trained personnel to detect the disease. Some eye doctors would not screen because of the nonavailability of treatment modalities. However, recent developments have shown that more preterms are delivered, and facilities for special baby care are becoming readily available.^[3] A sample of opinions among Neonatologists in Nigeria revealed that screening for ROP is not done in their centers.^[5] The aim of this study was to describe the use of mobile phone technology in the screening of ROP in Lagos, Nigeria, Sub-Saharan Africa.

Methods: Ethical Committee approved the program before the commencement of the study. Preterms with birth weight of <1.5 kg or gestational age of <32 weeks are eligible for screening according to laid down criteria.^[6] In conjunction with the neonatologist, topical tropicamide (0.5%) and phenylephrine (2.5%) were used to dilate the pupils. Examination was carried out in dim illumination. A lid speculum (Sauer Premature Infant Speculum Denville, New Jersey, USA) was used to part the lids. Indirect ophthalmoscopy was used to examine the fundus to ensure there were no missed diagnoses. Iphone 5S by Apple Inc. Cupertino, California, United States with 20 diopter lens (Volk) was used to examine the fundus. A mobile phone app, FILMiC Pro (developed by Cinegenix, Seattle, USA) was launched in video mode. The camera flash served as the source of illumination, and its intensity was controlled by the App. The 20 diopter lens was used to capture the image of the retina which was picked up by the camera system of the mobile phone [Figure 1]. After a thorough examination, the video was examined and snapshot of still images taken [Figure 2]. Another mobile phone app, Aviary (Adobe Inc., New York, USA) was used to edit the picture.

Abstracts

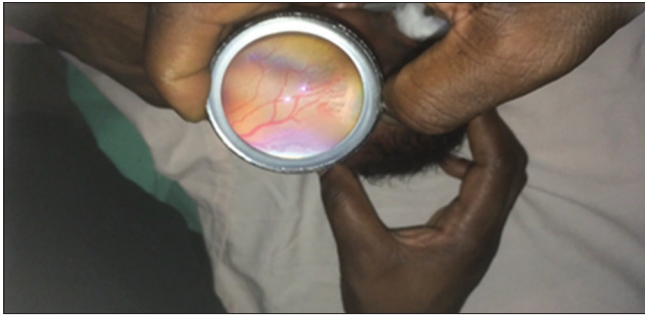

Figure 1: Mobile phone for retinopathy of prematurity screening, screenshot from the mobile phone

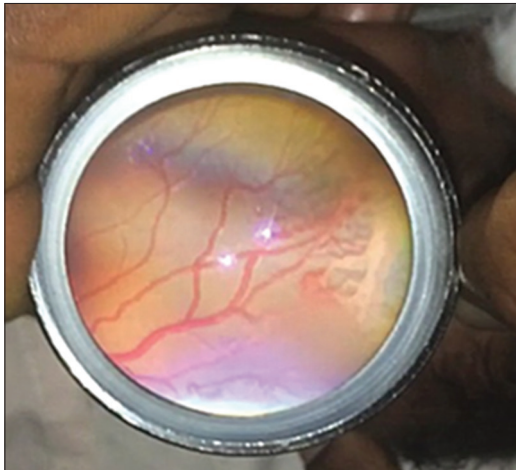

Figure 2: Edited picture showing a ridge and new vessels

Results and Discussion: The flash of the phone camera serves as the illumination, and its intensity is controlled by the mobile phone app - FILMiC pro. The distance between the phone and the 20 diopter lens is much shorter than what obtains in indirect ophthalmoscopy [Figure 1]. A video recording of the examination is preferable. The video can subsequently be reviewed to choose the appropriate frame(s) for editing.

Mobile phone fundus photography appears to be useful in screening for ROP. It is good for documentation, patient education, and for teaching in poor resource settings where Retcam is not available. It also enhances telemedical services in remote areas where retina surgeon may not be readily available. Previous workers have stressed the use of mobile phone fundus photography in poor resource settings.^[6-9]

Conclusion and Recommendation: It is recommended that more studies be done in the area to perfect the method.

REFERENCES

1. Adekeye M. Causes of Blindness in Children in NE Nigeria: A Blind School Study [Dissertation for Masters' Degree in Community Eye Health]. London, UK: Department of Preventive Ophthalmology, Institute of Ophthalmology; 1996.
2. Baiyeroju-Agbeja AM, Omokhodion F. Screening for retinopathy of prematurity. *Niger J Ophthalmol* 1998;6:23-5.
3. Adio AO, Ugwu RO, Nwokocha CG, Eneh AU. Retinopathy of prematurity in Port Harcourt, Nigeria. *ISRN Ophthalmol* 2014;2014:481527.
4. Ademola-Popoola D, Adesiyun O, Durotoye IA, Obasa TO. Screening programme for retinopathy of prematurity in Ilorin, Nigeria: A pilot study. *West Afr J Med* 2013;32:281-5.
5. Uhumwangho O, Israel-Aina Y. Awareness and screening for retinopathy of prematurity among paediatricians in Nigeria. *J West Afr Coll Surg* 2013;3:33-45.

6. Reynolds JD, Dobson V, Quinn GE, Fielder AR, Palmer EA, Saunders RA, *et al.* Evidence-based screening criteria for retinopathy of prematurity: Natural history data from the CRYO-ROP and LIGHT-ROP studies. *Arch Ophthalmol* 2002;120:1470-6.
7. Shanmugam MP, Mishra DK, Madhukumar R, Ramanjulu R, Reddy SY, Rodrigues G. Fundus imaging with a mobile phone: A review of techniques. *Indian J Ophthalmol* 2014;62:960-2.
8. Haddock LJ, Kim DY, Mukai S. Simple, inexpensive technique for high-quality smartphone fundus photography in human and animal eyes. *J Ophthalmol* 2013;2013:518479.
9. Raju B, Raju NS. Regarding fundus imaging with a mobile phone: A review of techniques. *Indian J Ophthalmol* 2015;63:170-1.

Mobile Phones for Diabetic Retinopathy Screening in Poor Resource Setting of Nigeria, Sub-Saharan Africa

Oluleye T. S., Rotimi-Samuel A.¹, Akinshola F. B.¹, Adefule-Ositelu O. A.¹, Onakoya O. A.¹, Aribaba O. T.¹, Musa K. O.¹, Adenekan O. A.¹, Ilo O. T.¹, Abikoye T. M.¹, Eminike A. I.¹

Department of Ophthalmology, Retinal and Vitreous Unit, University College Hospital, Ibadan, ¹Department of Ophthalmology, Guinness Eye Center, Lagos University Teaching Hospital, Lagos, Nigeria. E-mail: t_oluleye@yahoo.co.uk

Introduction: The number of people with type 2 diabetes is increasing in every country. Eighty percent of people with diabetes live in low- and middle-income countries.^[1] Prevalence rates of diabetes mellitus in Nigeria are estimated to be between 8% and 10%.^[2] The International Diabetic Federation reported that Nigeria has the highest number of diabetics in Africa.^[3] Diabetic retinopathy (DR) is now a significant cause of blindness in developing countries such as Nigeria.^[4,5] A majority of diabetics are unaware of their diabetic status, those who are aware do not realize the importance of consistent follow ups with the physicians, and most of the physicians are not trained to detect and refer sight-threatening DR for timely treatment.^[6] People with DR can be treated to prevent visual impairment and blindness. Most endocrinologists and general physicians are not trained to screen for DR. Indirect ophthalmoscopy is too cumbersome for general ophthalmologists, direct ophthalmoscopy is inadequate, and fundus photography is beyond the reach of poor economies. Mobile phones technology combined with a 20 diopter lens appear to be less expensive and can be taught to endocrinologists, general physicians, and resident doctors. The aim of this study is to describe the use of mobile phone technology in the screening for DR in poor resource setting of Nigeria.

Methods: Patient population: The diabetic patients attending the University College Hospital and the Lagos University Teaching Hospital. All consenting patients had their pupils dilated with tropicamide 0.5% and phenylephrine 10% before the examination. The iPhone system is

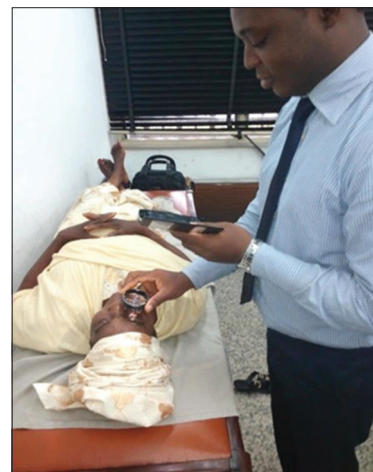

Figure 1: Mobile phone with 20 diopter lens for funduscopy and photographyt

Abstracts

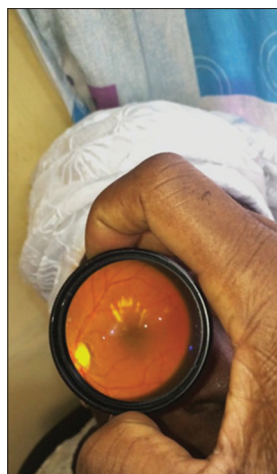

Figure 2: Screenshot from the mobile phone

used. The FiLMiC pro app is launched with the continuous illumination of the camera flash set to the lowest. The flash of the mobile phone produces the illumination. The setup is used as a binocular indirect ophthalmoscope [Figure 1]. The 20 diopter lens captures the image of the retina, which is viewed by the examiner on the screen of the mobile phone [Figure 2]. The video recording mode is activated to capture the video of the retina examination. Still images or frames can be captured with a snapshot and saved into the picture gallery of the mobile phone for further editing.

Results and Discussion: In poor resource settings, the mobile system is worth considering in view of the cost of standard fundus cameras. The other advantage of this system is its portability and its ability to send images by emails to experts who will advise on the management of the patients. Previous studies suggested the use of the mobile systems in poor resource settings.^[7-9] The field of view of the system is much wider when compared to the direct ophthalmoscope. This is useful in DR screening. Patient's teaching, telemedicine, and teaching of undergraduate and postgraduates are enhanced. The pictures can be uploaded to a dedicated server by email for review by retinal doctors in our hospital.

Conclusion: Mobile phones can be adapted to take fundus photographs during screening for DR in poor resource settings of Sub-Saharan Africa. More studies are needed.

REFERENCES

1. King H, Aubert RE, Herman WH. Global burden of diabetes, 1995-2025: Prevalence, numerical estimates, and projections. *Diabetes Care* 1998;21:1414-31.
2. Ogbera AO, Ekpebegh C. Diabetes mellitus in Nigeria: The past, present and future. *World J Diabetes* 2014;5:905-11.
3. International Diabetes Federation Atlas. 5th ed. Available from: <http://www.idf.org>. [Last accessed on 2014 Mar 09].
4. Nwosu SN. Diabetic retinopathy in Nnewi, Nigeria. *Niger J Ophthalmol* 2000;8:7-10.
5. Nwosu SN. Low vision in Nigerians with diabetes mellitus. *Doc Ophthalmol* 2000;101:51-7.
6. Mohan KC, Shukla D, Kim R. *Retinal Vascular Disorders*. New Delhi: Academia Publishers; 2005.
7. Shanmugam MP, Mishra DK, Madhukumar R, Ramanjulu R, Reddy SY, Rodrigues G. Fundus imaging with a mobile phone: A review of techniques. *Indian J Ophthalmol* 2014;62:960-2.
8. Haddock LJ, Kim DY, Mukai S. Simple, inexpensive technique for high-quality smartphone fundus photography in human and animal eyes. *J Ophthalmol* 2013;2013:518479.
9. Raju B, Raju NS. Regarding fundus imaging with a mobile phone: A review of techniques. *Indian J Ophthalmol* 2015;63:170-1.

The Role of Electrophysiological Tests in the Management of Retinal Diseases

Abdulkadir L. Rafindadi

Department of Ophthalmology, Ahmadu Bello University Teaching Hospital, Shika-Zaria, Nigeria. E-mail: arafindadius@yahoo.com

Introduction: Electrophysiological tests (EPTs) are a group of tests that may be used to ascertain the integrity of the visual system and its pathways beyond standard clinical examination. They were first developed in the mid-19th century and introduced in clinics in the mid-20th century.^[1] Objectives are to assess function of visual pathway from the photoreceptors to visual cortex.

Objectives of this Presentation: (1) To demonstrate the importance of EPT in the management of retinal diseases. (2) To enumerate some important EPT available.

Discussion: The various types of electrophysiological testing available include^[1-7] (1) electroretinogram (ERG), (2) macular or focal ERG, (3) pattern ERG, (4) electrooculogram (EOG) measurement of retinal function with standardized eye movements, (5) flash visually evoked cortical potential (Flash VEP), (6) pattern appearance VEP, (7) other nonstandard procedures for recording VEP and ERG, e.g., measurement of interocular beat frequencies, flicker, and sweep VEPs, multi-focal ERG, fast oscillation, (8) electromyogram, and (9) electroretinography. For measurement of nystagmus and eye movements, among these, the ERG, EOG, and VEP are the most commonly performed tests in clinical practice. Indications for these tests include but not only limited to^[1-7] (1) confirmation of neurological or ophthalmological disease, (2) evaluation of the visual pathways in the presence of media opacities, (3) pediatric neurology assessment, (4) unexplained visual loss, (5) drug toxicity and monitoring, (6) assessment of retinal or optic nerve function following trauma, (7) quantitative assessment of visual disease, (8) detection of disease or carrier states of inherited visual disorders, and (9) research. The full field ERG tests the mass electrical response of the retina to photic stimulation, thereby assessing the status of the retina in eye disease. The two components that are most often measured are the a- and b-waves.^[1] The a-wave is the first large negative component, followed by the b-wave which is corneal positive and usually larger in amplitude. Changes in these waves indicate different types of retinal disease [Figure 1]. This type of ERG records the mass potential over the entire retina thus unless 20% or greater of the retina is diseased the test will appear normal. To this end, the multifocal ERG was developed to overcome this challenge and is capable of detecting maculopathies and other focal retinal diseases.^[1] The pattern ERG is used to detect subtle optic neuropathies. The EOG measures the potential that exists between the cornea and Bruch's membrane. It is useful in chloroquine and hydroxychloroquine maculopathy and Best's disease [Figure 2].^[1] VEP is an evoked potential caused by a visual

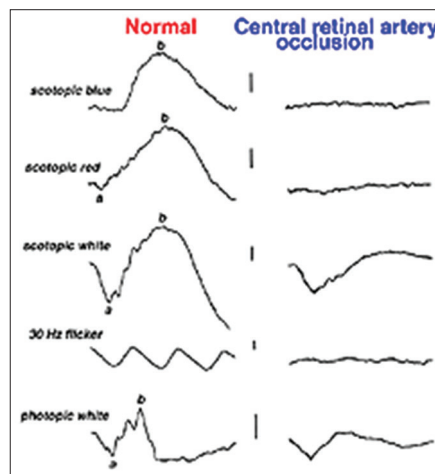


Figure 1: Electrophysiological traces in a patient with central retinal artery occlusion showing absent b-wave

Abstracts

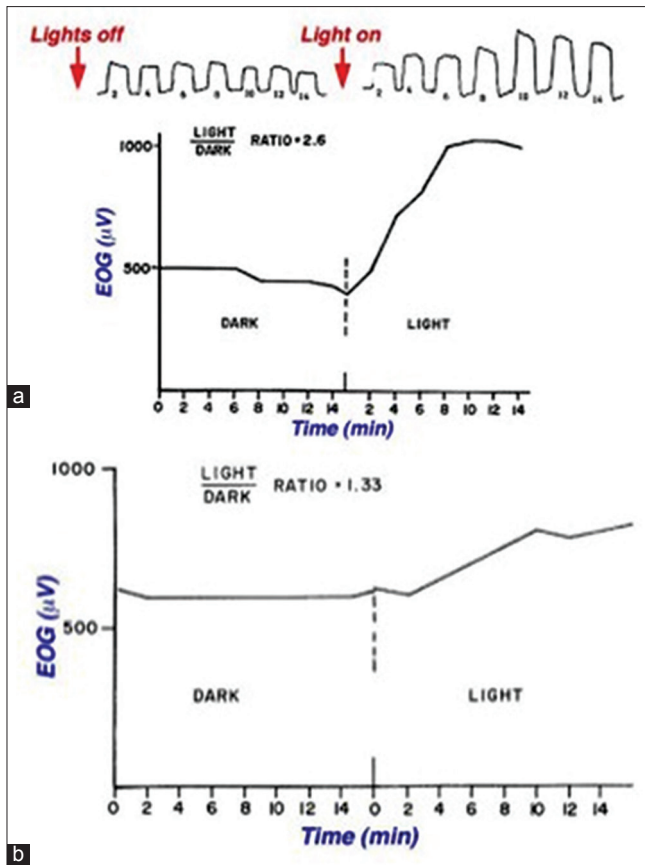


Figure 2: (a) Electrooculogram of a normal patient, (b) Electrooculogram of a patient with Best's disease with Arden ratio of 1.33. Normal ≥ 1.7

stimulus such as an alternating checkerboard pattern on a computer screen and responses recorded from electrodes placed at the occiput are read on an electroencephalogram.^[8]

Conclusion: EPT are very useful in evaluating and managing retinal and optic nerve diseases in conditions where clinical evaluation may be difficult due to reasons already outlined. They may also compliment other investigations such as central visual fields, fundal angiography, radiography, and optical coherence tomography among others.

REFERENCES

- Creel DJ. The Electroretinogram and Electro-oculogram: Clinical Applications; July, 2011.
- Young B, Eggenberger E, Kaufman D. Current electrophysiology in ophthalmology: A review. *Curr Opin Ophthalmol* 2012;23:497-505.
- Vincent A, Robson AG, Holder GE. Pathognomonic (diagnostic) ERGs. A review and update. *Retina* 2013;33:5-12.
- Fishman GA, Birch DG, Holder GE. *Electrophysiologic Testing in Disorders of the Retina, Optic Nerve, and Visual Pathway (Pearls Series)*. 2nd ed. Oxford University Press; 2001.
- Bach M, Brigell MG, Hawlina M, Holder GE, Johnson MA, McCulloch DL, et al. ISCEV standard for clinical pattern electroretinography (PERG): 2012 update. *Doc Ophthalmol* 2013;126:1-7.
- Bach M. Available from: <http://www.iscev.org/standards/proceduresguide.html>. [Last updated on 2013 Feb 20].
- Marmor MF, Zrenner E. Standard for clinical electro-oculography. *International Society for Clinical Electrophysiology of Vision. Arch Ophthalmol* 1993;111:601-4.

- Harding GF, Odom JV, Spileers W, Spekreijse H. Standard for visual evoked potentials 1995. *The International Society for Clinical Electrophysiology of Vision. Vision Res* 1996;36:3567-72.

Presumed Optic Disc Melanocytoma: A Diagnostic Challenge – Case Report

Ugalahi M. O., Adeyemo A. O., Ezichi E. I., Olusanya B. A., Oluleye T. S. *Department of Ophthalmology, University College Hospital, Ibadan, Oyo, Nigeria. E-mail: oheobe26@yahoo.com*

Introduction: Optic disc melanocytoma (ODM) is a rare, benign, pigmented ocular tumor arising from dendritic melanocytes within the optic disc or any part of the uvea.^[1,2]

Case Report: A 17-year-old female with painless, nonprogressive poor vision noticed since childhood. At examination, unaided visual acuity was 6/36 and 6/18 in the right eye and left eye, respectively which improved to 6/9 bilaterally with pin hole examination. There was relative afferent pupillary defect in the right eye. Fundoscopy of the right eye revealed a raised pigmented optic disc lesion, about 1.5 disc diameters in size, obscuring the lower disc margins with overriding normal vessels [Figure 1]. The anterior and posterior segments of the left eye were normal. Ocular ultrasound done showed a well-defined homogenous soft tissue mass arising from the choroid in the optic nerve area and projecting into the vitreous cavity.

The clinical impression was presumed right ODM with refractive error. The patient was counseled and spectacles prescribed, periodic follow-up and monitoring with fundus pictures were emphasized.

Discussion: ODM is seen as a dark brown/black lesion on funduscopy, it may be flat or slightly elevated with fibrillate extensions which may proceed to the edge of the disc and into the adjacent retina.^[2] It is usually unilateral, bilateral cases have been reported, but they are quite rare.

^[3] Visual acuity in most cases remains normal. In a study by Zografos *et al.*, visual acuity was normal in 70%, subnormal in 27% of the cases. ^[4] Afferent pupillary defect is an associated finding in 30% of cases,^[4]

it is likely due to compression of the optic disc fibers and may be seen in the presence of good vision.^[2] ODM is commonly described as a stationary lesion,^[2,5] it may however enlarge in up to 10–15% of cases,^[3] malignant transformation is rare, reported in 1–2% of cases.^[6] Useful investigations include ultrasound or computer tomography especially for lesions >0.5 mm,^[3] but they cannot differentiate ODM from other raised lesions involving the optic disc. Fundus fluorescein angiography is the hallmark of diagnosis; it shows hypofluorescence due to closely compact and deep pigmentation of the melanocytes.^[1,3] Histology shows round, closely apposed cells with normochromic nuclei and distinct borders with abundant cytoplasm.^[1] Factors supporting ODM in this patient include the presence of an RAPD, raised pigmented optic disc lesion, nonproliferation of the lesion on follow-up visits, and being a female of African descent. Differential diagnosis includes juxtapapillary choroidal melanoma, juxtapapillary choroidal nevus, metastatic melanoma to the optic disc, adenoma of the RPE, and hyperplasia of the RPE.

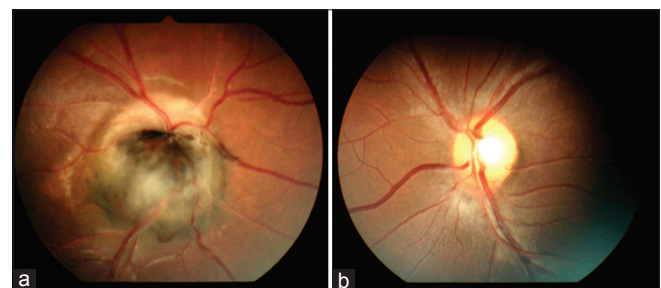


Figure 1: (a) Fundus picture of right eye shows a raised pigmented optic disc lesion, about 1.5 disc diameters, in size obscuring the lower disc margin with overriding normal vessels. (b) Fundus picture of left eye showing normal optic disc and macula

Abstracts

Conclusion: ODM is a rare benign tumor; it should be considered in patients presenting with a pigmented optic disc lesion and regular follow-up with fundus photography is advocated.

REFERENCES

1. William T. Foundations of Clinical Ophthalmology. [CD-ROM]. Pennsylvania: Lippincott Williams & Wilkins; 2005.
2. Kanski JJ, Bowling B. Clinical Ophthalmology: A Systemic Approach. 7th ed. Edinburgh: Elsevier; 2011.
3. Shields JA, Demirci H, Mashayekhi A, Eagle RC Jr, Shields CL. Melanocytoma of the optic disk: A review. *Surv Ophthalmol* 2006;51:93-104.
4. Zografos L, Othenin-Girard CB, Desjardins L, Schalenbourg A, Chamot L, Uffer S. Melanocytomas of the optic disk. *Am J Ophthalmol* 2004;138:964-9.
5. Joffe L, Shields JA, Osher RH, Gass JD. Clinical and follow-up studies of melanocytomas of the optic disc. *Ophthalmology* 1979;86:1067-83.
6. Shields JA, Demirci H, Mashayekhi A, Shields CL. Melanocytoma of optic disc in 115 cases: The 2004 Samuel Johnson Memorial Lecture, part 1. *Ophthalmology* 2004;111:1739-46.

