

ORIGINAL ARTICLE

# Trabeculectomy for Congenital Glaucoma in University College Hospital, Ibadan: A 7 Year Review of Cases

Bolutife Ayokunnu Olusanya, Mary Ogbenyi Ugalahi, Morolake Oluwayomi Malomo, Aderonke Baiyeroju

Department of Ophthalmology, University College Hospital, Ibadan, Oyo State, Nigeria

## ABSTRACT

**Introduction:** Congenital glaucoma is an uncommon ocular condition affecting about 1/15,000 live births. About two third of cases are bilateral with a higher prevalence in males. The definitive treatment requires surgery which could be trabeculectomy, trabeculotomy, goniotomy, drainage tubes or a combination of trabeculotomy and trabeculectomy. **Aim:** To determine the outcome of trabeculectomy in patients with congenital glaucoma seen at the University College Hospital Ibadan between 2007 and 2013. **Methods:** The medical records of all patients with congenital glaucoma seen between the years 2007 and 2013 were retrieved. Inclusion criteria were patients who had trabeculectomy with or without anti-metabolites within this period. The main outcome measures assessed were postoperative intraocular pressure (IOP) and corneal clarity. Data was analyzed with the statistical Package for Social Sciences version 21. **Results:** Thirty-four eyes of 18 patients were reviewed out of which 16 patients had bilateral trabeculectomy while two had unilateral trabeculectomy. The mean preoperative IOP was 26.31 mmHg while the mean IOP in the immediate postoperative period, at 3 months after surgery and at last follow-up visit were 13.31 mmHg, 12.78 mmHg and 15.89 mmHg respectively. IOP was <21 mmHg in 81.82% of the eyes as at last clinic visit. All eyes had cloudy corneas preoperatively while 38.24% had minimal residual corneal opacity (Haab's striae) as at last follow-up visit. **Conclusion:** In the absence of equipment for other surgical options, trabeculectomy is an effective surgical approach in the management of congenital glaucoma in the short term.

**Keywords:** Congenital glaucoma, glaucoma, trabeculectomy

## INTRODUCTION

Congenital glaucoma is a group of heterogeneous disorders characterized by maldevelopment of the eye's aqueous outflow system.<sup>[1]</sup> The incidence is about 1 in 15,000 births with males accounting for 65% of cases<sup>[1]</sup> and presenting as bilateral disease in about 75% of cases.<sup>[2]</sup> The pathology of the condition remains unclear: But it is probably due to a developmental anomaly of

the anterior chamber tissue derived from neural crest cells.<sup>[2]</sup> It occurs sporadically with a few occurring as an inherited autosomal recessive disease.<sup>[2]</sup>

Presentation is in infancy with epiphora, large cornea diameter for age, cloudy cornea, photophobia evident by blepharospasm, bulphthalmous, cupping of the disc and elevation in intraocular pressure (IOP). Gonioscopy reveals trabeculodysgenesis and diagnosis is usually clinical.<sup>[1,2]</sup>

Surgical intervention is the treatment of choice. Goniotomy and trabeculotomy are the initial preferred

### Address for correspondence

Dr. Mary Ogbenyi Ugalahi, Department of Ophthalmology, University College Hospital, Ibadan, Oyo State, Nigeria. E-mail: oheobe26@yahoo.com

### Access this article online

#### Quick Response Code



#### Website:

[www.nigerianjournalofophthalmology.com](http://www.nigerianjournalofophthalmology.com)

#### DOI:

10.4103/0189-9171.170968

This is an open access article distributed under the terms of the Creative Commons Attribution-NonCommercial-ShareAlike 3.0 License, which allows others to remix, tweak, and build upon the work non-commercially, as long as the author is credited and the new creations are licensed under the identical terms.

**For reprints contact:** [reprints@medknow.com](mailto:reprints@medknow.com)

**How to cite this article:** Olusanya BA, Ugalahi MO, Malomo MO, Baiyeroju A. Trabeculectomy for congenital glaucoma in University College Hospital, Ibadan: A 7 year review of cases. Niger J Ophthalmol 2015;23:44-7.

## Olusanya, *et al.*: Trabeculectomy for congenital glaucoma in Ibadan

methods of treatment while trabeculectomy is usually reserved for refractory cases.<sup>[1]</sup> Other surgical options include combined trabeculotomy and trabeculectomy, as well as glaucoma filtration devices.

This study aims to determine the outcome of trabeculectomy in patients with congenital glaucoma between 2007 and 2013 in the University College Hospital, Ibadan.

### METHODS

This is a retrospective interventional case series.

Medical records of all patients diagnosed with congenital glaucoma in the pediatric ophthalmology clinic of University College Hospital Ibadan between 2007 and 2013 were retrieved. Only patients who had trabeculectomy with or without the use of anti-metabolites (5-fluorouracil) within this period were included while patients who had combined trabeculectomy and trabeculotomy were excluded from the study.

Data collected included age at onset of symptoms, age at presentation, age at surgery, pre and postoperative cornea clarity, pre and postoperative IOP, horizontal cornea diameter (HCD), duration of follow-up, and use of anti-glaucoma medications.

All patients had an examination under general anaesthesia. Induction was achieved with either halothane or isoflurane. These medications have a lowering effect on IOP after induction of anaesthesia. However preoperative and postoperative IOP measurements used for analysis in this study were performed in clinic with the use of Perkins applanation tonometer under sedation with chloral hydrate.

Following induction of general anaesthesia with halothane or isoflurane, the HCD was measured using Vernier's calipers. Surgery was performed by the same surgeon (AMB) throughout the study period. Patients with bilateral disease underwent surgery in both eyes at the same sitting or within 1 week of each other. All patients had the fornix based conjunctiva flap approach. In four eyes, 5-fluorouracil was applied after raising the conjunctiva flap with cotton pledgets and thoroughly irrigated with normal saline. A partial thickness rectangular scleral flap was made, which was dissected forwards until the clear cornea was reached. Following paracentesis, a deep rectangular-shaped block was excised and peripheral iridectomy was done. The superficial sclera flap was then sutured lightly at its corners posteriorly with 10/0 nylon and after which the conjunctival flap was sutured ensuring that it was

water tight. A bleb was produced intraoperatively by injecting balanced salt solution into the anterior chamber through the paracentesis.

Postoperative examination was done under sedation with the administration of chloral hydrate syrup at a dose of 80–100 mg/kg; Chloral hydrate as a sedative in children has not been shown to have any effect on IOP. IOP, cornea clarity and bleb characteristics were assessed at all visits. Success criteria were defined as IOP <21 mmHg as at the last clinic visit with or without medications. Late presentation was defined as presentation to our clinic later than 3 months after the onset of symptoms.

Congenital glaucoma was diagnosed clinically as onset of symptoms of photophobia, cloudy cornea, enlarged cornea or bulphthalmous, epiphora with or without IOP >25 mmHg on examination before 6 months of age.

Immediate postoperative period was defined as a period of 2 weeks following surgery.

Data was analyzed by Statistical Package for Social Sciences (SPSS), version 21 (IBM Corp., New York, NY, USA).

### RESULTS

Eighteen patients met the inclusion criteria of the study. The mean age at presentation was 12.31 ( $\pm 17.13$ ) months with the youngest being 10 days old. There was a male to female ratio of 3.5:1. A total of 34 eyes of 18 patients were reviewed, 16 (88.89%) patients had bilateral disease. Four eyes of two patients underwent trabeculectomy with the use of anti-metabolite (5-fluorouracil), while the remaining 30 eyes underwent trabeculectomy without anti-metabolite. The mean age at onset of symptoms and at surgery was 1.08 ( $\pm 1.47$ ) months and 18.88 months ( $\pm 19.97$ ) respectively. The mean time between presentation and surgery was 5.74 months ( $\pm 8.41$ ).

Early onset of symptoms (within the first 3 months of life) was noted in 95% of the patients; however, 9 (50%) of the patients presented late.

The mean HCD at presentation was 14.04 mm ( $\pm 1.38$ ). Twenty-one (61.7%) eyes had HCD  $\geq 14$  mm; and 20 (58.82%) eyes had IOP of  $\geq 25$  mmHg at presentation. All eyes had corneal edema with or without cornea opacities (Haab's striae) prior to surgery.

The mean preoperative IOP was 26.31 mmHg ( $\pm 9.07$ ), while mean IOP in the immediate postoperative period, at 3 months postoperatively and at last clinic visit are

Olusanya, *et al.*: Trabeculectomy for congenital glaucoma in Ibadan

presented in Figure 1. There was an appreciable fall in IOP following surgery with a slight rise in the mean IOP at the last follow-up clinic visit.

Out of the 29 eyes with measured IOP in the immediate postoperative period, 21 (72.41%) eyes had an IOP of <21 mmHg, while at 3 months 21 (61.8%) eyes had IOP below 21 mmHg. The remaining 13 eyes were not available for assessment due to missed follow-up appointment. As at last follow-up visit, 27 (81.82%) eyes out of 33 eyes had IOP <21 mmHg [Figure 2]. One patient did not keep follow-up appointment after the first clinic visit 2 weeks postoperatively and was excluded from the analysis for mean IOP at last follow-up.

The mean duration of follow-up was 9.19 months with a range of 0.5–38 months. At time of this review, the duration of follow-up was <6 months in 9 (50%) patients, between 6 months and 1 year in 4 (22.22%) patients, between 1 year and 2 years in 3 (16.67%) patients while two patients (11.11%) were followed-up for more than 2 years.

The IOP distribution for the population of patients in the different categories of follow-up are shown in Figure 3.

Success rate of trabeculectomy in this population of patients was 81.82% as defined by IOP of <21 mmHg as at last clinic visit, six eyes (17.65%) of four patients required postoperative anti glaucoma medications.

As at the last follow-up visit, 9 (26.47%) eyes had complete resolution of cornea oedema with no residual scarring, 12 (35.29%) eyes had persistent cornea oedema while 13 (38.24%) had resolution of oedema with minimal residual cornea scarring.

**DISCUSSION**

The laterality of disease and male to female ratio from our study is similar to findings from other populations<sup>[1,2]</sup> as the disease was found to affect predominantly males, with about two-thirds of cases having bilateral involvement.

Late presentation was noticed among our patients despite early onset of disease in majority of them, and this may explain the high proportion of the patients with advanced disease noted in this study. Late presentation has also been reported by Bekibele and Olusanya who found that less than half of their patients with congenital glaucoma had presented by the age of 1 year.<sup>[3]</sup> Late presentation with advanced disease in our environment may be due to poor public awareness about the disease.

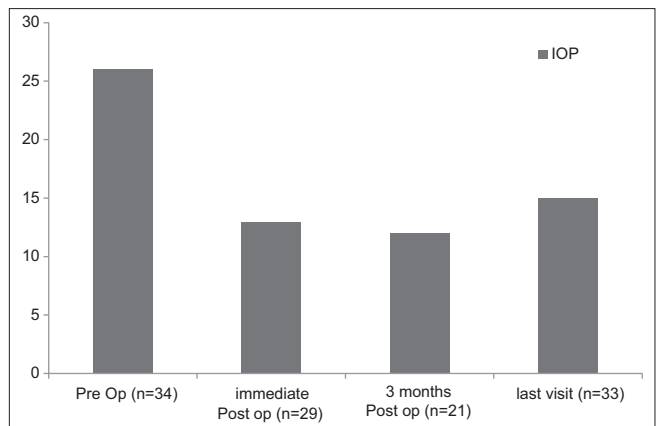


Figure 1: Mean intraocular pressure preoperative and postoperative period

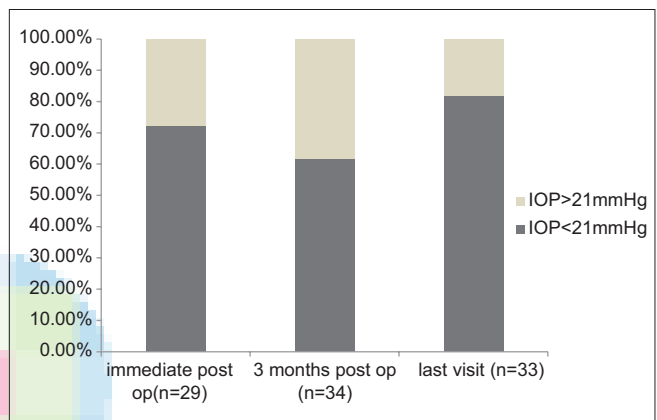


Figure 2: Distribution of intraocular pressure among eyes in the postoperative period

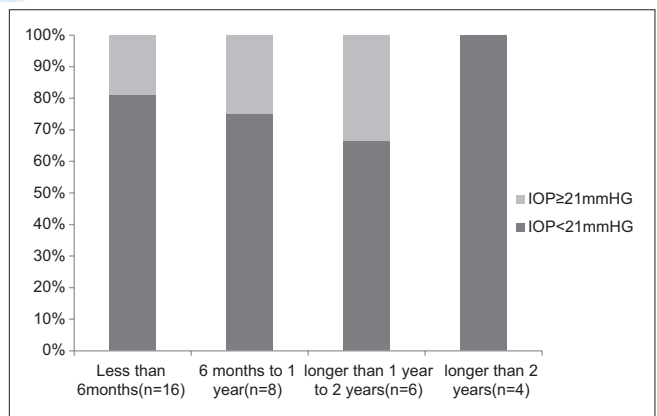


Figure 3: Distribution of intraocular pressure among eyes at last follow-up visit categorized according to duration of follow-up

Advanced disease is a known risk factor for poor outcome in congenital glaucoma which is often associated with poor visual prognosis.<sup>[1,2]</sup> A retrospective study by Al-Hazmi *et al.*<sup>[4]</sup> which assessed the correlation between surgical success rate and severity of congenital glaucoma revealed that severe primary congenital glaucoma (HCD ≥ 14.5 mm) showed less success than mild and moderate disease

## Olusanya, *et al.*: Trabeculectomy for congenital glaucoma in Ibadan

over time. Early diagnosis of congenital glaucoma and prompt surgical intervention can significantly improve a child's visual outcome.

Overall, our study showed that primary trabeculectomy is effective in the management of congenital glaucoma with a success rate of 81.82%. This is similar to findings from Eastern Nigeria and Dublin where success rates ranged between 83% and 92.3%.<sup>[5-7]</sup> In the study from Eastern Nigeria, Onwasigwe *et al.*<sup>[5]</sup> reported a success in 87.7% of patients who had IOP  $\leq$ 20 mmHg. However their study comprised of patients with less severe disease (mean HCD – 12 mm) and with a follow-up period of only 3 months. Similarly, Burke and Bowell<sup>[7]</sup> from Dublin had a success rate of 87% after a single procedure although surgical success criteria was IOP  $\leq$ 18 mmHg and patients were followed-up for an average of 3.5 years, which is longer than our follow-up period.

A study on trabeculectomy in young Nigerians by Agbeja-Baiyerolu *et al.*<sup>[8]</sup> where similar success criteria IOP of 21 mmHg with or without medications was used reported a success rate of 91.1%. However, only 40% of the patients in their study were diagnosed with congenital glaucoma.

An earlier study by Bekibele and Olusanya conducted in our hospital reported a success rate of 66.7%.<sup>[3]</sup> The difference in success rates may be explained by the longer duration of follow-up of patients in the earlier study. In addition, there were older children in that study with a mean age of 25.5 months compared to 12.3 months in the present study. Giampani *et al.*<sup>[9]</sup> reported a lower success rate of 55.26% following primary trabeculectomy with mitomycin C. We attribute the difference to the longer duration of follow-up (mean of 61.16 months) in their study compared to this one.

Therefore, although in the short term, we have observed an above average surgical success, long term follow-up will be required to evaluate the success of trabeculectomy in these patients.

The main limitation of this study was late presentation and poor follow-up rate among our patients. In addition, the retrospective design of the study is a limitation especially with regards to incomplete and missing data,

no uniform protocol for patients' follow-up, as well as the absence of a control group. Although education and counseling of parents about the disease is a very important part of the management of patients with congenital glaucoma in our centre, some patients are still lost to follow. Perhaps the approach to counseling of these parents needs re-evaluation.

## CONCLUSION

Trabeculectomy for congenital glaucoma has a good success rate in the short term and remains an effective primary surgical option in our environment. In addition, education of health workers in the antenatal clinic and well baby clinics about common childhood eye diseases is recommended to encourage early presentation.

## Financial support and sponsorship

Nil.

## Conflicts of interest

There are no conflicts of interest.

## REFERENCES

1. Pickering TD, Wong PC, Dickens CJ, Hoskins HD Jr. Developmental glaucoma. In: Tasman W, Jaeger EA, editors. *Duanes Ophthalmology on DVD-Rom*. Ch. 51. Philadelphia: Wolters Kluwer Health/Lippincott Williams and Wilkins; 2011.
2. Simon JW, Aazy AA, Drack AV, Hutchinson AK, Olitsky SE, Plager DA, *et al.* 2009-2010 Basic and Clinical Sciences Course (BCSC) Section 6: Pediatric Ophthalmology and Strabismus. Ch. 21. San Francisco, CA: American Academy of Ophthalmology; 2009. p. 325-32.
3. Bekibele CO, Olusanya BA. Buphthalmos: A twelve-year review at Ibadan. *Niger J Pediatr* 2004;31:39-42.
4. Al-Hazmi A, Awad A, Zwaan J, Al-Mesfer SA, Al-Jadaan I, Al-Mohammed A. Correlation between surgical success rate and severity of congenital glaucoma. *Br J Ophthalmol* 2005;89:449-53.
5. Onwasigwe EN, Ezegwui IR, Onwasigwe CN, Aghaji AE. Management of primary congenital glaucoma by trabeculectomy in Nigeria. *Ann Trop Paediatr* 2008;28:49-52.
6. Fulcher T, Chan J, Lanigan B, Bowell R, O'Keefe M. Long-term follow up of primary trabeculectomy for infantile glaucoma. *Br J Ophthalmol* 1996;80:499-502.
7. Burke JP, Bowell R. Primary trabeculectomy in congenital glaucoma. *Br J Ophthalmol* 1989;73:186-90.
8. Agbeja-Baiyerolu AM, Owoaje ET, Omoruyi M. Trabeculectomy in young Nigerian patients. *Afr J Med Med Sci* 2002;31:33-5.
9. Giampani J Jr, Borges-Giampani AS, Carani JC, Oltrogge EW, Susanna R Jr. Efficacy and safety of trabeculectomy with mitomycin C for childhood glaucoma: A study of results with long-term follow-up. *Clinics (Sao Paulo)* 2008;63:421-6.