

## ORBIT AND OCULOPLASTY

### Adverse Effects of Local Anaesthesia During an Evisceration

Ubah J. N., Adekunle M. O., Adejumo O. O.  
*Ladoke Akintola University of Technology, Teaching Hospital, Osogbo, Nigeria. E-mail: ubahjn@gmail.com*

**Introduction:** Peribulbar technique is widely used by ophthalmologists. No local anesthetic technique is entirely free of severe systemic adverse events and they cannot be reliably predicted. We present a case report of complications arising from peribulbar injection of 2% Xylocaine (lidocaine) for evisceration.

**Case Report:** A 43-year-old male farmer presented on account of pain, and loss of vision involving his right eye. On examination, the vision in the affected eye was light perception. The cornea was densely infiltrated and the central part was melting with descemetocele. Evisceration under local anesthesia was advised. 7 ml using of 2% xylocaine with 1:100,000 Adrenaline was administered by peribulbar method using a 23 gauge needle. About 5 min after the local anesthesia was infiltrated, while 360° peritomy was being performed, the patient developed generalized tonic clonic seizures, became aggressive, unresponsive and hypertonic. The seizure was arrested with intravenous Diazepam 10 mg and thiopentone 200 mg given intramuscularly. Supportive treatment was also given and continued for about one hour after which he became calm, relaxed and regained full consciousness. Surgery was suspended. The rest of his stay in the hospital was uneventful. Investigations carried out were normal. He later had uneventful evisceration under general anesthesia.

**Discussion:** Systemic side effects of locally injected anesthetic agents occur if very large dose is injected or a normal dose is inadvertently injected intravenously. These include; vasovagal reactions, confusion, respiratory depression, convulsions and hypotension. For healthy adults, the maximum recommended dose of Lidocaine HCL with epinephrine should not exceed 7 mg/kg (3.2 mg/lb) of body weight. When used without epinephrine, the maximum individual dose should not exceed 4.5 mg/kg (2 mg/lb) of body weight.<sup>[4]</sup> The total recommended doses of Xylocaine is 20–300 mg.<sup>[5]</sup> Systemic side-effects like stress of the day's event, eye drops and other agents used in the eye, and causes that may be entirely unrelated to anesthesia or surgery could have contributed to the side-effects.<sup>[1]</sup> Local anesthesia administration generally carries low rate of complications,<sup>[6]</sup> but could be devastating when they occur. Adverse effects have been reported.<sup>[7,8]</sup> In the patient being reported, only 14 mg (7 ml) of 2% Xylocaine was given. There could have been inadvertent intravenous injection. The treatment of toxicity of local anesthesia essentially is supportive. Local anesthesia is very popular in ophthalmic surgeries. Knowledge of the possible complications should also be borne in mind. Adequate precautions should be taken to handle these adverse effects when they occur.

### REFERENCES

- Mary Lowth. Ocular Local Anaesthetics; 2014. Available from: <http://www.patient.c.uk/doctor/ocular-local-anaesthetics>.
- Lignocaine – Side effects. Available from: <http://www.druginfosys.com>.
- Lidocaine Hydrochloride Injection, USP Rx only. American Regent, INC. Shirley, NY 11967. Available from: <http://www.vaxserve.com>. [Browsed 2014 Jun 16].
- Omudhome Ogbru Lidocaine HCL, Xylocaine Drug facts, Side Effects and Dosing. 2014. Available from: <http://www.medicinenet.com>. [Browsed 2014 Jun 16].
- Complications and how to avoid them in Local anaesthesia for ophthalmic surgery. Joint guidelines from the Royal College of Anaesthetists and Royal College of Ophthalmologists. Ch. 8. Feb, 2012.
- Murdoch IE. Peribulbar versus retrobulbar anaesthesia. *Eye (Lond)* 1990;4 (Pt 3):445-9.
- Donald MJ, Derbyshire S. Lignocaine toxicity; a complication of

local anaesthesia administered in the community. *Emerg Med J* 2004;21:249-50.

- Ashaye AO, Ubah JN, Sotumbi PT. Respiratory arrest after retrobulbar anaesthesia. *West Afr J Med* 2002;21:343-4.

### Congenital Ptosis in a Tertiary Hospital in Lagos: Clinical Variety and Visual Status

Balogun Bolanle G., Balogun Modupe M., Adekoya Bola J., Diaku-Akinwumi Ijeoma N.<sup>1</sup>  
*Department of Surgery, Ophthalmology Unit, <sup>1</sup>Department of Pediatrics, Lagos State University Teaching Hospital/College of Medicine, 1-5 Oba Akinjobi Street GRA Ikeja, Lagos, Nigeria. E-mail: appleclinic@yahoo.com*

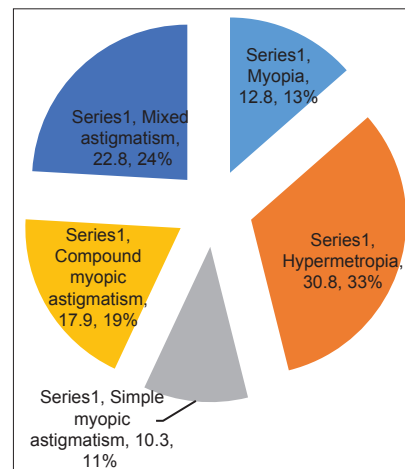
**Introduction:** Congenital ptosis is drooping of the upper eyelid present at birth or within the first year of life. Severe ptosis results in poor visual development,<sup>[1]</sup> amblyopia<sup>[2,3]</sup> and astigmatism.<sup>[4]</sup> Ptosis is cosmetically unacceptable and may impact negatively on carrier development and the quality of life of affected individuals.<sup>[5-7]</sup> There is paucity of literature on the clinical types and visual status of these patients in the study environment thus stimulating this study.

**Methods:** Descriptive prospective study of congenital ptosis from January 2007 to June 2014. Data on age, gender, diagnosis and refractive errors were recorded. Refractive errors were measured using auto-refraction, objective retinoscopy and subjective refraction.

**Results:** Totally 37 patients aged 8 months–27 years presented. 54.1% males. Unilateral ptosis in 89.2%, left sided ptosis 60.6%. 21.6%,

**Table 1 : Clinical variety of congenital ptosis**

Variety of congenital ptosis	n	%
Isolated		
Simple congenital	21	56.8
Marcus gunn jaw wink phenomenon	2	5.4
Congenital aponeurotic	2	5.4
Blepharophimosis	2	5.4
Non-isolated		
Congenital third nerve palsy	4	10.8
Congenital ptosis+superior rectus weakness	1	2.7
Congenital horner's syndrome	0	0.0
Congenital ptosis+esotropia+nystagmus	5	13.5
Total	37	100.0



**Figure 1:** Visual status of the patients (refractive errors)

## Abstracts

presented in the first year of life.

**Clinical Variety:** Table 1 shows simple congenital ptosis was commonest, followed by congenital ptosis with esotropia + nystagmus, and congenital third nerve palsy.

**Visual Status:** Astigmatism 54% [Figure 1] was the commonest refractive error.

**Discussion:** We highlight the clinical variety and visual status in congenital ptosis. Simple congenital ptosis 56.8% was the commonest though with a lower prevalence than 74% (UK)<sup>[9]</sup> and 75.7% (USA),<sup>[9]</sup> mainly attributable to unavailability of oculoplastic surgeons prior sub-specialization era in the study population. Uncorrected refractive errors (59.5%) was high similar to 54% by Oral *et al.*<sup>[10]</sup> Delayed presentation could explain this. 21.6% were amblyopic and comparable to 20–23.9% by preceding works.<sup>[11,12]</sup>

**Conclusion:** It is important to encourage early presentation by educating parents especially at the ante-natal and well-baby/immunization clinics.

## REFERENCES

1. Anderson RL, Baumgartner SA. Amblyopia in ptosis. *Arch Ophthalmol* 1980;98:1068-9.
2. Finsterer J. Ptosis: Causes, presentation, and management. *Aesthetic Plast Surg* 2003;27:193-204.
3. Guercio JR, Martyn LJ. Congenital malformations of the eye and orbit. *Otolaryngol Clin North Am* 2007;40:113-40, vii.
4. Klimek DL, Summers CG, Letson RD, Davitt BV. Change in refractive error after unilateral levator resection for congenital ptosis. *J AAPOS* 2001;5:297-300.
5. Whitehouse GM, Grigg JR, Martin FJ. Congenital ptosis: results of surgical management. *Aust N Z J Ophthalmol* 1995;23:309-14.
6. Ahmadi AJ, Sires BS. Ptosis in infants and children. *Int Ophthalmol Clin* 2002;42:15-29.
7. Battu VK, Meyer DR, Wobig JL. Improvement in subjective visual function and quality of life outcome measures after blepharoptosis surgery. *Am J Ophthalmol* 1996;121:677-86.
8. Berry-Brincat A, Willshaw H. Paediatric blepharoptosis: a 10-year review. *Eye (Lond)* 2009;23:1554-9.
9. Griepentrog GJ, Diehl NN, Mohnhey BG. Incidence and demographics of childhood ptosis. *Ophthalmology* 2011;118:1180-3.
10. Oral Y, Ozgur OR, Akcay L, Ozbas M, Dogan OK. Congenital ptosis and amblyopia. *J Pediatr Ophthalmol Strabismus* 2010;47:101-4.
11. Thapa R. Refractive error, strabismus and amblyopia in congenital ptosis. *JNMA J Nepal Med Assoc* 2010;49:43-6.
12. Dray JP, Leibovitch I. Congenital ptosis and amblyopia: A retrospective study of 130 cases. *J Pediatr Ophthalmol Strabismus* 2002;39:222-5.

### Impacted Foreign Body to the Anterior Orbit

Ajayi Iyiade, Omotoye Olusola, Ajite Kayode, Alegbeleye Titilope  
*Department of Ophthalmology, Ekiti State Teaching Hospital, Adoekiti, Nigeria. E-mail: iyiseye2005@yahoo.com*

**Introduction:** Orbital foreign body may present with varying signs and symptoms and they usually occur from high missile objects. Small and inert objects could be retained in the orbit unnoticed while larger objects are usually very obvious because of the external extension in most cases. The role of radiological investigations cannot be overemphasized.

**Case Report:** A 41-year-old welder presented with 6 h history of impacted orbital foreign body in the right eye sustained while trying to fix the brake of a motorcycle. The retaining spring sprang back accidentally with resultant penetration and impaction in the anterior orbit. Patient claimed to have good vision in both eyes prior to the injury. He was not wearing protective device at the time of injury. Examination of the affected eye revealed complete mechanical ptosis, with bleeding from the medial canthal region and nasal cavity. Also seen was a metallic spring with the external extent lying as far as the neck inferiorly. Orbital X-ray was done which confirmed an anterior orbital metallic foreign body. After generous local anesthesia, metallic object was removed following

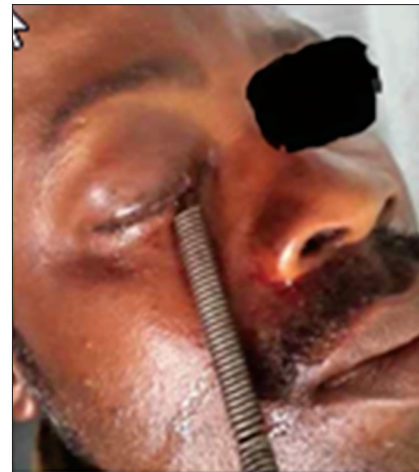

Figure 1: At presentation with impacted foreign body in place

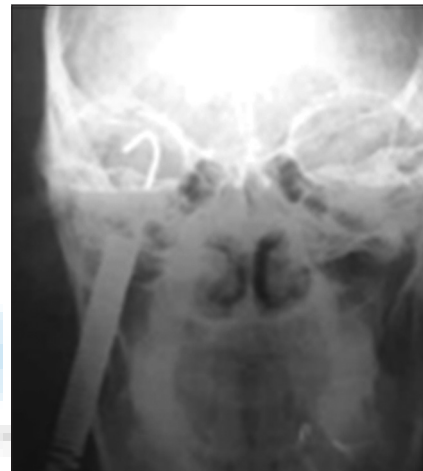

Figure 2: Plain X-Ray showing the metallic foreign body

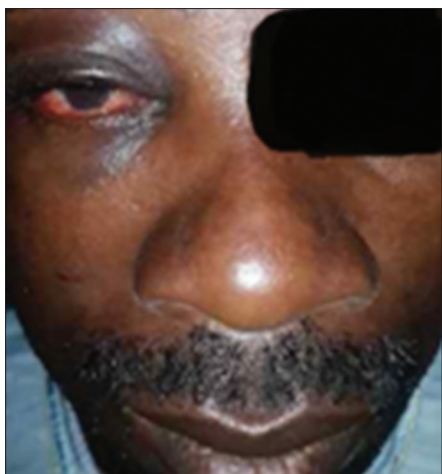


Figure 3: Foreign body after removal

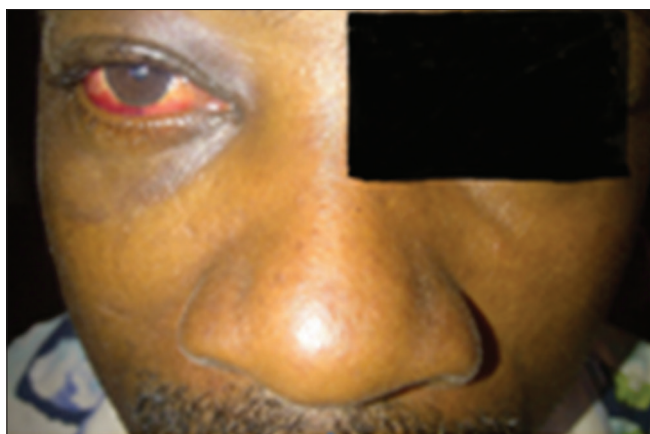the direction denoted by the shape of the curved tip of the spring within the anterior orbit as revealed on X-Ray film. Visual acuity (VA) done after removal was 6/24 + 1. The conjunctiva was moderately injected with mild chemosis. Pupil was round, regular and briskly reactive. The contralateral eye was essentially normal. Fundoscopy findings were essentially normal in both eyes. Tetanus toxoid injection, intravenous (IV) ceftriaxone and frequent topical ciprofloxacin, analgesic, acetazolamide were given. Oral antibiotics were commenced after 72 h of administration of IV antibiotics. First day post removal of foreign body, unaided VA was 6/6. Ptosis and conjunctival chemosis were resolving. There was mild subconjunctival hemorrhage inferiorly with normal intraocular pressure. No Retinal hemorrhage or tear was seen. Patient was given one week appointment but did not show up. The management of this patient would have been bedeviled by the twin problem of non-availability and non-affordability of recommended investigative procedure if cheaper and easily available alternative had been ignored.

**Conclusion:** Plain X-ray should be done to determine the orientation of radiopaque objects when penetrating orbital injuries occur in places where computed tomography scan is not readily available. This helps to minimize the risk of iatrogenic ocular damage.

## Abstracts



**Figure 4:** The right eye day 1 post removal of foreign body



**Figure 5:** The right eye 5 days after removal of the foreign body

### Non Surgical Treatment of Periocular Skin Cancer

Oworu O.

*Department of Eye, Huddersfield Royal Infirmary, England, United Kingdom. E-mail: Gbemsol@aol.com*

**Introduction:** Non-surgical treatment of periocular skin cancer includes Topical preparations such as 5 Fluorouracil cream (Efudex) and Topical Imiquimod Cream (Aldara). Other treatment modalities include cryotherapy, PDT and radiotherapy. Efudex can be used in the treatment of actinic keratosis, Superficial BCC and *in situ* squamous cell carcinoma. The mechanism of action is believed to be by direct cytotoxic effect on neoplastic cells. The recommended treatment is 5% cream twice daily for 3 weeks. After 3–5 days treatment, the sun damaged skin usually becomes very inflamed, red angry and sore.<sup>[1]</sup> After 11–14 days the skin will start to peel and crack which looks terrible before the skin finally heals. Efudex does not appear to penetrate very deeply into the skin, and may not destroy deeper cancer cells.<sup>[1]</sup> Aldara is an immunomodulatory agent<sup>[2]</sup> belonging to the Imidazoquinoline family. It is recommended for small superficial BCC. It acts by activating antigen-presenting cells and by inducing secretion of proinflammatory cytokines with a resultant cytotoxic effect. Side effects include itching, burning, redness, ulceration, scabbing, flaking and pain.<sup>[3]</sup> Treatment is applied 5 times a week for 6 weeks. The long term cure rate is around 80%. Cryotherapy can be used in the treatment of extrafacial lesions including superficial BCC, solar keratosis and viral warts. It utilizes liquid nitrogen and works by causing intra and extra cellular ice crystals which then causes cell rupture and tissue disruption. It is suitable for lesions <6 mm. Treatment could either be a continuous freeze

thaw cycles. It can cause loss of pigment in the treated area as well as scarring hence may not be suitable for dark skinned patients.<sup>[4]</sup> Photodynamic therapy (PDT) works by activating of a tissue-localized photosensitizer by visible light, resulting in cell damage and death.<sup>[5]</sup> Topical 5 aminolevulinic acid (5-ALA) is applied to lesions for 1–18 h with or without occlusion. ALA appears to be taken up selectively by the diseased tissue and is converted to the photosensitizer protoporphyrin IX. Activation of the photosensitizer with light of appropriate wavelength leads to the release of reactive oxygen species (singlet O<sub>2</sub>). This modifies cell function subsequently causing cell death. Methyl aminolevulinic acid (MAL) an ester of ALA is more lipophilic than free ALA and penetrates more effectively through cutaneous tissue. MAL 160 mg/g only needs to be applied for 3 h. MAL is licensed in Europe for the treatment of actinic keratosis and BCC (both nodular and superficial). PDT can be painful and produces a dose dependent photo toxicity reaction (erythema and edema) that lasts for several days. Radiotherapy can be used in the treatment of BCC (nodular and superficial BCC) and SCC. It is suitable for extrafacial lesions (except Merkel cell tumor) and may be a viable option for frail elderly patients who do not wish surgical excision or who have inoperable tumor.<sup>[2]</sup> It is important to remember that radiotherapy may be carcinogenic and previous radiotherapy may make subsequent surgery more challenging.

**Summary:** In deciding the best non-surgical treatment to offer, considerations should include patient's preference, age and general health, clinical and histological subtype, size and site of tumor.

### REFERENCES

1. Lee S, Selva D, Huilgol SC, Goldberg RA, Leibovitch I. Pharmacological treatments for basal cell carcinoma. *Drugs* 2007;67:915-34.
2. Wagstaff AJ, Perry CM. Topical imiquimod: A review of its use in the management of anogenital warts, actinic keratoses, basal cell carcinoma and other skin lesions. *Drugs* 2007;67:2187-210.
3. Wagstaff AJ, Perry CM. Topical imiquimod: A review of its use in the management of anogenital warts, actinic keratoses, basal cell carcinoma and other skin lesions. *Drugs* 2007;67:2187-210.
4. National Cancer Institute. Skin Cancer (PDQ®): Treatment. Health Professional Version. Available from: [http://www.cancer.gov/cancertopics/pdq/treatment/skin/HealthProfessional/Page4#Section\\_363](http://www.cancer.gov/cancertopics/pdq/treatment/skin/HealthProfessional/Page4#Section_363). [Last accessed on 2014 Nov 07].
5. Fien SM, Oseroff AR. Photodynamic therapy for non-melanoma skin cancer. *J Natl Compr Canc Netw* 2007;5:531-40.
6. Neville JA, Welch E, Leffell DJ. Management of nonmelanoma skin cancer in 2007. *Nat Clin Pract Oncol* 2007;4:462-9.

### Surgical Management of Periocular Carcinoma

Oworu O.

*Department of Eye, Huddersfield Royal Infirmary, Huddersfield, England, UK. E-mail: Gbemsol@aol.com*

**Introduction:** Basal cell carcinoma (BCC) is the most common skin cancer worldwide accounting for 90% of head and neck cancer of which 10% occur around the eyelid. Basal cell carcinomas are slow growing, rarely metastasising malignant tumors and mortality is <0.1%. Perivascular and perineural invasion is associated with aggressive tumor. In Nigeria,<sup>[1]</sup> nasopharynx appears to be the commonest site for head and neck cancer, followed by sinonasal and laryngeal involvement in that order. Majority of the cancer is epithelial in origin [Figure 1] mostly squamous cell carcinoma (SCC). There is paucity of data on periocular involvement of head and neck cancer in Nigeria so this is a potential area of research. The aim of treatment includes total tumour eradication using a method that achieved the smallest risk of recurrence using the most effective method that is acceptable to the patient Mohs micrographic surgery remains the gold standard but this is not generally available even in the U K. Incision biopsy is required for histological diagnosis. Suggested excision margin are 3–4 mm for BCC, 5 mm for SCC and 10 mm for melanoma. Reasons for Incomplete excision include inadequate surgical

Abstracts

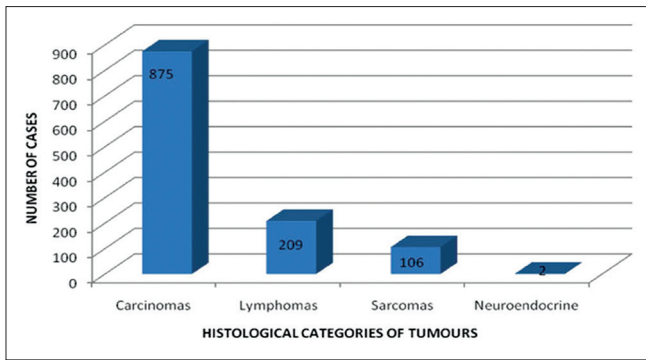


Figure 1: Histological categories of tumours

margin, site of tumor (recurrence is higher in H zone), size of tumor (the bigger the tumor, the higher the risk of incomplete excision), recurrent tumor (has a higher risk of incomplete excision compared to a primary excision), histology of tumor (morphoeic tumor is likely to be incompletely excised compared to a nodular tumor). 5 year cure rate of SCC<sup>[3]</sup> is 99% in a small tumor <2 mm, 82% in a tumor measuring 2–3 mm and 59% in a tumor measuring >3 mm. The risk of recurrence is higher in SCC if there is perineural or perivascular invasion. When considering full thickness eyelid reconstruction, the following combinations are acceptable. Anterior flap and a posterior flap, anterior flap with posterior graft, anterior graft with posterior flap. What is not acceptable is an anterior graft in combination with a posterior graft as at least one lamella has to be a flap (with its own blood supply). When reconstructing full thickness lower eyelid defect, direct closure may be possible in a small defect (<1/3 of the lower eyelid). In a moderate defect (>1/3 but <1/2 of the lower eyelid) a Tenzel flap may be required. In a large defect (>1/2 but <2/3 of the lower eyelid) a Mustarde cheek flap may be required. If there is total loss of the lower eyelid then an eyelid sharing flap may be required. Laissez-faire is an alternative to surgical repair which allows wound to heal by secondary intention. This technique, as used in the periorbital region, was first described in 1957. Traction sutures and seeding sutures may be placed to facilitate healing. Occlusive wound dressing (e.g. Allevyn) can be applied for up to 48 h postoperative. Systemic and topical antibiotics may also be used. Laissez-faire may be an option if the patient does not wish extensive reconstruction or because the patient is too frail to undergo further surgery.

REFERENCES

1. da Lilly-Tariah OB, Somefun AO, Adeyemo WL. Current evidence on the burden of head and neck cancers in Nigeria. *Head Neck Oncol* 2009;1:14.
2. Adisa AO, Adeyemi BF, Oluwasola AO, Kolude B, Akang EE, Lawoyin JO. Clinico-pathological profile of head and neck malignancies at University College Hospital, Ibadan, Nigeria. *Head Face Med* 2011;7:9.
3. Malhotra R, Huilgol SC, Huynh NT, Selva D. The Australian Mohs database: Periocular squamous cell carcinoma. *Ophthalmology* 2004;111:617-23.

Oculoplastic Complications in HIV Positive Patients-A Retrospective Hospital Based Pilot Study

Chaha K.

Chaha Eye Hospitals, Kaduna State, Nigeria. E-mail: [katorchaha@gmail.com](mailto:katorchaha@gmail.com)

**Introduction:** Though the HIV affects purely the humans, it actually originated from the Chimpanzees as the Simian immunodeficiency virus (SIV) which got mutated into the HIV after coming in contact with some humans.<sup>[1,2]</sup> The HIV compromises the immune system of the patient by depleting the CD4<sup>+</sup> T-Lymphocytes thus exposing the victim to both opportunistic and nonopportunistic infections together with and noninfectious disease like neoplasms involving all parts of the human body. Oculoplasty is a field that deals with specific eye

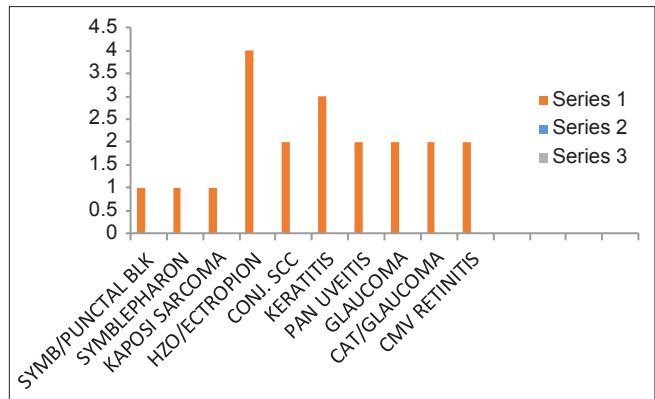


Figure 1: Results chart

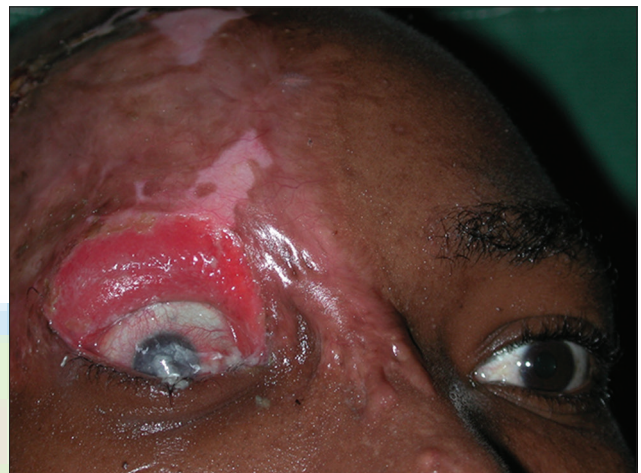

Figure 2: Severe form of Herpes Zoster ophthalmicus related upperlid cicatricial ectropion

structures including the orbit and the adnexae of the eyeball. Today the field of oculoplasty has expanded to include the entire face particularly for aesthetic reasons as in face lifting procedures. The oculoplastic tissues involved in the HIV patients are the orbit, eyeball adnexae, the lids, the conjunctiva and the lacrimal drainage system.

**Aim of the Study:** The aim of this study is to highlight the commonest oculoplastic complications in HIV patients in our hospitals between 2007 and 2010.

**Methodology:** All case folders of the HIV positive cases that presented to our hospitals between 2007 and 2010 were retrieved and reviewed.

**Results:** Out of the 20 cases that were analyzed, 9 cases (45%) had oculoplastic manifestations or complications. Herpes Zoster Ophthalmicus (HZO) induced cicatricial ectropion was found the commonest oculoplastic complication with 4 (44.4%) cases out of the 9 cases [Figure 1].

**Discussions and Literature Review:** Studies have shown that between 70 and 80% of all HIV positive patients present to the ophthalmologist with various eye complaints depending on the level of the CD4<sup>+</sup> cell count.<sup>[2]</sup> The CD4<sup>+</sup> T-cell count of <500/mL is associated with Kaposi Sarcoma, Lymphoma and Tuberculosis while the CD4<sup>+</sup> T cell count of <250/mL is associated with Pneumocystosis and Toxoplasmosis.<sup>[2,3]</sup> The CD4<sup>+</sup> T cell count of <100/mL is associated with retinal microvasculopathy, conjunctival microvasculopathy, cytomegalovirus (CMV) retinitis, varicella zoster virus (VZV) retinitis, mycobacterium avium complex infections, *Cryptococcus*, microsporidiosis, HIV encephalopathy, progressive multifocal leukoencephalopathy.<sup>[2,4]</sup> Though orbital complications in HIV patients are very rare they could include orbital lymphomas and aspergillus induced orbit and in such cases the CD4<sup>+</sup> cell count drops to as low as <100/ $\mu$ l.<sup>[3,5]</sup> HZO is also a common complication in the HIV patient affecting the ophthalmic branch of the

#### Abstracts

trigeminal (5<sup>th</sup> cranial) nerve.<sup>[6,7]</sup> It is more common in the patients with CD4+ T cell count of between 50 and 200/mL.<sup>[3,5]</sup> In our study the HZO related cicatricial ectropion appears to be the commonest oculoplastic complication in our HIV patients. The cicatricial ectropion in our study seems to differ from that found in other studies<sup>[6]</sup> [Figure 2].

**Summary and Conclusion:** The CD4+ T-Lymphocyte cell count has been very predictive and most cases presenting to the ophthalmologist have CD4+ T cell count of <500/mL, and most oculoplastic cases will begin to show once the CD4+ T cell count drops to <250/mL. In our pilot study HZO appears to be the commonest oculoplastic complication in our HIV positive patients followed by the squamous cell carcinoma of the conjunctiva. The major limitation of our study is the small sample size. We can therefore not make categorical conclusions for now until more studies.

#### REFERENCES

1. Ah-Fat FG, Batterbury M. Ophthalmic complications of HIV/AIDS. *Postgrad Med J* 1996;72:725-30.
2. Basic and Clinical Science Course, Section 7, American Academy of Ophthalmology; 2011-2012.
3. Ahmed I, Pacific Eye Associates, Ai E, Chang E, California Pacific Medical Center, Luckie A, *et al.* HIV InSite Knowledge Base Chapter August, 2005; Content Reviewed January, 2006.
4. Demathé A, Arede LT, Miyahara GI. Case report – Mucous membrane pemphigoid in HIV patient: A case report. *Cases J* 2008;1:345.
5. Copeland RA Jr. Ocular Manifestations of HIV Infection. *Medscape* Oct 18, 2013. Holds JB, Basic and Clinical Science Course, Section 7, American Academy of Ophthalmology, 2011-2012. Ophthalmic Manifestations of HIV.
6. Wiafe B. Herpes Zoster Ophthalmicus in HIV/AIDS. *Community Eye Health* 2003;16:35-6.
7. Shaikh S, Christopher NT. Standard university medical center, Stanford, California. Evaluation and management of herpes zoster ophthalmicus. *Am Fam Physician* 2002;66:1723-30.

