

# CONGENITAL ORBITAL TERATOMA IN A NIGERIAN CHILD

NO MAGULIKE FWACS, FRCS

\*O IKE OKOYE FMCophth, FICS

A AGHAJI FMCophth

Department of Ophthalmology, University of Nigeria Teaching Hospital, PMB 01129, Enugu, Nigeria

Email: oicokoye@yahoo.com

EEC ECHEZONA, FWACS, FICS

Plastic and Reconstructive Surgery Unit, National Orthopaedic Hospital, Enugu, Nigeria

## ABSTRACT

Congenital orbital teratomas are rare. This is a case report of an otherwise healthy five-month female Nigerian child with a history of painless progressive protrusion of the right eyeball since birth. Examination revealed a massive, non-axial proptosis with superonasal displacement of a deformed blind right globe. Other findings included a large fluctuant non-tender ill-defined mass adherent to the deformed globe, conjunctival keratinization, and an opaque, lustreless cornea. Radiological investigations revealed significant widening of the orbit (orbital x-ray), a large expanding multilocular cystic tubular orbital mass (ocular ultrasonography), and a poorly-enhancing mixed attenuation complex right orbital mass with a focus of calcification encasing a deformed globe (computerized axial tomography scan). A lid-sparing modified exenteration with temporalis muscle transplant/split skin graft was performed. Histopathology reports on biopsy tissues revealed derivatives of all three germ cell layers consistent with the diagnosis of orbital teratoma. Six months post-operatively, there is no obvious evidence of reoccurrence of the tumour.

components, in varying degrees of complexity, including as an extreme curiosity, a fully developed foetus.<sup>2</sup> In view of the rarity of these lesions and the need to highlight the importance of interdisciplinary team approach in the management, we present a case of congenital teratoma in a 5-month-old Nigerian child.

## CASE REPORT

An otherwise healthy 5-month female (6.4 kg weight) Nigerian child, who had attained age-appropriate milestones, presented to us with a history of painless, progressive, protrusion of the right eyeball since birth. Apart from a history of maternal fever at 6 months of pregnancy, the antenatal and postnatal histories were uneventful.

No abnormality was noted on general and systemic examination. However, examination of the eye and its adnexae revealed a massive, non-axial proptosis with superonasal displacement of a deformed, blind right globe. Manual reduction of the proptosis failed. A large fluctuant, non-tender ill-defined mass of variable consistency in some portions was noted to be continuous with the deformed globe. Other findings included conjunctival keratinization, chemosis and an opaque, lustreless, keratinized cornea; which precluded further visualization of deeper ocular structures. There was also restriction of ocular motility

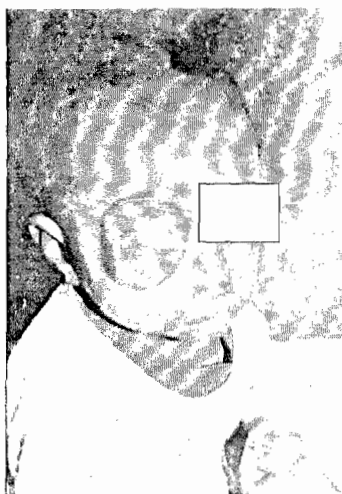

Figure 1. Plain photograph of the patient (with normal eye concealed)

and an opaque, lustreless, keratinized cornea; which precluded further visualization of deeper ocular structures. There was also restriction of ocular motility

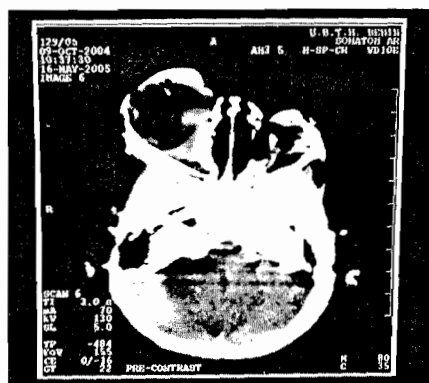
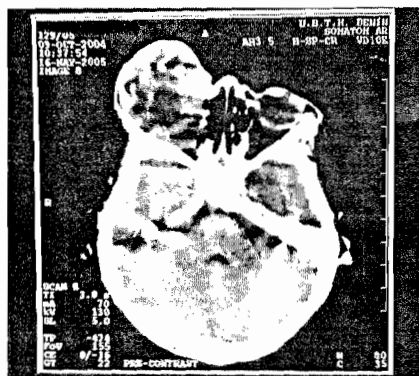**Key words:** congenital, orbital, teratoma, exenteration, Nigerian

## INTRODUCTION

Given the considerable variety of tissues comprising the orbit, orbital tumours constitute a heterogeneous array of lesions, and as such, pose numerous challenges to the ophthalmologist. Teratomas are rare congenital germ cell tumours, which arise from primordial germ cells, and comprise approximately 1% of orbital tumours in childhood.<sup>1</sup> These tumours are characterized by the presence of ectodermal, mesodermal and endodermal

\* Author for correspondence

in all directions of gaze. Findings from haematological and chemical pathological tests were essentially normal. Radiographs of the orbit showed a large soft tissue mass occupying the right orbit with associated significant widening of the orbit. There was no evidence of erosion of the bones and the sphenoidal ridge was not displaced. An ultrasonographic scan showed a large expanding multifollicular cystic tubular orbital mass, with deformity of the right globe due to compression and anterior displacement. No intraocular masses were seen. Pre- and post-contrast axial and coronal CT scans revealed a poorly-enhancing mixed attenuation complex right orbital mass with a focus of calcification encasing a deformed globe. There was associated widening of the right orbit, with no evidence of bony erosions, intracranial mass lesions or collections. The paranasal sinuses and mastoid air cells were well pneumatized for the patient's age.



Figures 2. CT scan films of the patient showing a poorly enhancing mixed attenuation complex right orbital mass with a focus of calcification encasing a deformed globe.

In view of the visual status of the affected eyeball and cosmetic considerations, a lid-sparing modified exenteration/cyst aspiration with temporalis muscle transplant/split skin graft (taken from the thigh) was performed. The postoperative period was grossly

uneventful apart from mild pyrexia, which was attributed to malaria. Cytological examination of the aspirate showed fairly cloudy, blood-tinged straw-coloured fluid with no malignant cells or organisms. Two histopathology reports of 3cm/ 3.5cm wedges of roundish whitish tissues revealed derivatives of all three germ cell layers, consistent with the diagnosis of orbital teratoma. Six months postoperatively, there is no obvious evidence of recurrence of the tumour. The next line of action is to plan for prosthesis.

DISCUSSION

The presentation at birth, unilaterality, female sex of the patient, clinical, radiologic and histopathologic findings noted in this report are typical of a benign congenital orbital teratoma.<sup>2</sup> Orbital teratomas are recognized to be rare,<sup>1,3</sup> and are probably choristomas rather than true neoplasms.<sup>3</sup> Another report<sup>4</sup> attests to the rare occurrence of orbital teratomas even among Nigerians. Proptosis at birth, as noted in this patient and in other reports,<sup>5</sup> is rare. Rapid growth, causing orbital enlargement, destructive proptosis, conjunctival keratinization, exposure keratopathy and corneal ulceration in otherwise healthy newborns, and occurring more in females, with a slight left-sided preponderance is the more usual presentation of orbital teratoma.<sup>2,6</sup> The eye may be damaged due to compression or exposure but there is usually no bony defect. The role of the CT scan in assessing the presence of calcification and to define the orbital/cranial anatomy cannot be overemphasized.<sup>5,7</sup> As in this case, teratomas contain elements derived from all three embryonic germ cell layers<sup>1</sup> and are usually benign and nonrecurrent<sup>2,7</sup> with only a few reported cases of malignancy.<sup>2,4,8</sup>

In order to ensure visual preservation and symmetric orbital growth in affected children, early and complete extirpation is the treatment of choice when possible.<sup>1,2,3,5,9</sup> In the case of this patient, delayed presentation and the hideous proptosis with its attendant complications informed the decision for a modified exenteration, which is also recognized as a treatment option.<sup>4,10</sup> Better outcomes (especially cosmetic) would definitely be obtained if an interdisciplinary team approach (involving the ophthalmologist, radiologist, oncologist, paediatrician, pathologist, plastic surgeon, neurosurgeon) is employed in the management of such cases.

References

1. Spinelli HM, Criscuolo GR, Tripps M, Buckley PJ. Massive orbital teratoma in the newborn. *Ann Plast Surg* 1993 Nov; 31(5): 453-458.
2. Kivela T, Tarkkanen A. Orbital germ cell tumours revisited: A clinicopathological approach to classification. *Surv Ophthalmol* 1994; 38: 541-554.
3. Levin ML, Leone CR Jr, Kincard MC. Congenital orbital teratomas. *Am J Ophthalmol* 1986; 102(4): 476-481.

4. Akabe EA, Mpyet CD, Mandong BM. Orbito-ocular teratoma: A case report. *Nig J Surg Res* 2000; 2: 155-157.
5. Lea GA, Sullivan TJ, Tsikelas GP, Davis NG. Congenital orbital teratoma. *Aust NZ J Ophthalmol*. 1997; 25(1): 63-66.
6. Alkemade PPH. Congenital teratoma of the orbit. *Ophthalmologica* 1976; 173: 274-285.
7. Abdelmoula M, Gdoura A, Feki J. Primary teratoma of the orbit. Apropos of a case. *Rev Stomatol Chir Maxillofac* 1997; 98(1): 7-11.
8. Soares EJC, Lopes K da S, Andrade J de S, Faleiro LC, Alves JCR. Orbital malignant teratoma. A case report. *Orbit* 1983; 2: 135.
9. Guthoff R, Schmelze R, Schafer HJ. Orbital teratoma-microsurgical therapy possibilities. *Klin Monatsbl Augenheilkd*. 1992; 200(4): 294-298.
10. Bilgic S, Dayanir V, Kiratli H, Gungen Y. Congenital orbital teratoma: A clinicopathologic case report. *Ophthalm Reconstr Surg* 1997; 13(2): 142-146.