

# FAILURE OF PAN-RETINAL LASER PHOTOCOAGULATION TO REGRESS NEOVASCULARIZATION IN PROLIFERATIVE DIABETIC RETINOPATHY

AO MAHMOUD, FMCOph, FWACS, FICS

Department of Ophthalmology, University of Ilorin Teaching Hospital, P. O. Box 13834, Ilorin, Nigeria

E-mail: [mahmoud\\_ao@yahoo.com](mailto:mahmoud_ao@yahoo.com)

## ABSTRACT

### Objectives:

- (i) To illustrate the occurrence of failure of regression of neovascularization (NV) following adequate initial and supplemental pan-retinal laser photocoagulation (PRP) using 3 case histories
- (ii) To review the literature on possible aetiogenesis and further management options

**Methods:** The hospital records of 3 patients with proliferative diabetic retinopathy (PDR) and in whom NV did not regress following multiple sessions of PRP were reviewed. The data extracted included status of diabetic control, status of proliferative diabetic retinopathy, and details of laser treatment and outcome.

**Results:** The 3 patients were all middle-aged males in stable clinical condition and with non-insulin dependent diabetes of more than 12 years duration. Two of the patients were managed in Saudi Arabia where the argon green laser was used, while the third one was managed in Nigeria with the diode laser. The number of laser burns for the two patients who were undergoing laser treatment for the first time were not less than 1,750, while the amount during supplemental laser sessions for each of the 3 patients varied according to the available retinal space that had not been treated during past laser treatment sessions. The power settings were generally made to produce moderate laser burns with the spot size set at 500 micro-meters and a duration of 0.1 seconds.

**Conclusions:** Despite adequate initial and supplemental PRP in these 3 patients, their NV failed to regress. It is recommended that a more extensive PRP be made during initial sessions and liberal use of supplemental PRP be made in cases of non-regression.

**Key words:** proliferative diabetic retinopathy, pan-retinal photocoagulation, and persistent neovascularization.

## INTRODUCTION

Routine ophthalmic laser service is becoming more available in developing countries such as Nigeria.<sup>1,2</sup> Pan-retinal (laser) photocoagulation (PRP) for proliferative diabetic retinopathy (PDR) constitutes a significant proportion of the laser treatments being offered,<sup>1</sup> a point that underscores the fact that diabetic retinopathy is no longer a rare condition among Nigerians,<sup>3,4</sup> as it used to be a few decades ago.<sup>5,6</sup>

The Diabetic Retinopathy Study Group proved that PRP significantly decreases the likelihood that an eye with high-risk characteristics in PDR will progress to visual loss.<sup>7-9</sup> The four high-risk characteristics are: presence of new vessels, location of new vessels on the disc, severity of new vessels and presence of pre-retinal or vitreous haemorrhage. These characteristics emanate from the formation and progression of neovascularization (NV), which heralds the beginning of the proliferative phase of diabetic retinopathy. Hence, achieving regression of NV with PRP is the treatment goal for ophthalmic laser surgeons who manage this disease. It is not in all instances that regression of NV is achieved.<sup>10-13</sup> This paper illustrates the occurrence of failure of NV to regress following standard PRP using three (3) cases and a review of the literature on the possible aetiogenesis and further management options.

## CASE REPORTS

### Case I

AI, a fifty-two year old Saudi male had been diagnosed with non-insulin dependent diabetes mellitus (NIDDM) 15 years earlier. He presented at El-Magraby Eye Hospital (EMEH), Jeddah, Saudi Arabia, in 1994 with a complaint of poor vision in both eyes.

He was in good general health and was not hypertensive. Aided visual acuity (VA) in both eyes was count fingers (CF) at 2 metres (m), and the eyes were normotensive. The right fundus had proliferative diabetic retinopathy (PDR) with clinically significant macular oedema, while the left fundus had severe non-proliferative diabetic retinopathy.

Following a modified grid-laser treatment of the

right macular oedema, initial pan-retinal photocoagulation (PRP) using the argon green laser was administered to both eyes, with 1900 burns in each eye, in August 1994. The general laser settings used for all PRP laser sessions (initial or supplemental) were a spot size of 500 micro-meters ( $\mu\text{m}$ ) with a pan-fundoscopic lens, a duration of 0.1 seconds, and varying the power settings as required to achieve moderate intensity burns (400-800 milli-Watts or mW). As the neovascularization of the optic nerve disc (NVD) in the right fundus did not regress, supplemental PRP laser sessions with argon green laser were carried out twice in 1995, using 980 and subsequently 815 burns. The NV had still not regressed when last reviewed in December 1995 (fig. 1), and visual acuity remained unchanged at CF at 2m. The left fundus remained quiescent, as there was no progression to proliferative changes.

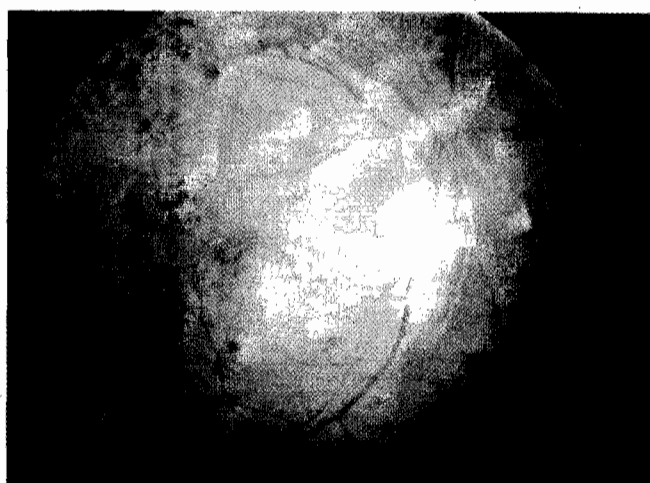


Figure 1. Photograph of the right fundus showing persistent neovascularization of the disc despite the extensive retinal scars from past laser treatment sessions.

#### Case II

AF, a forty-six year old Sudanese male, had been diagnosed with NIDDM 12 years earlier. He first presented in January 1992 at EMEII, with a complaint of poor vision in both eyes. He had had laser treatment sessions elsewhere and was on guttae betagan for his left eye.

He was in good general health and was not hypertensive. He had an aided VA of CF at 2m in the right eye and light perception only in the left eye. The right eye was normotensive and the fundus had a quiescent PDR with avascular fibrous tissues along the vascular arcades following previous laser treatment. The left eye had rubeotic glaucoma and vitreous haemorrhage. He had supplemental PRP using the argon green laser administered to his left eye in 1992 (1000 burns), 1994 (850 burns), and 1995 (735 burns). The same

general laser settings as in the first case were used for all the sessions. Though the vitreous haemorrhage cleared, a florid NVD persisted in his left eye (fig. 2) and the aided VA only slightly improved to CF at 1m.

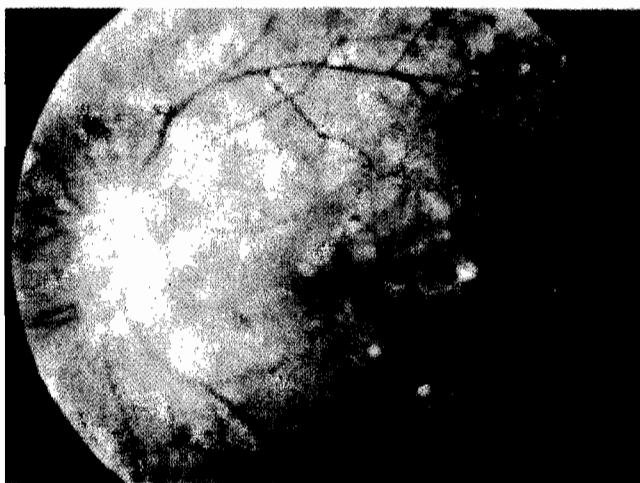


Figure 2. Photograph of the left fundus showing persistent neovascularization of the disc despite the extensive retinal scars from past laser treatment sessions.

#### Case III

SA, a fifty-six year old Nigerian male, had been diagnosed with NIDDM 18 years earlier. He presented at the National Eye Centre, Kaduna, Nigeria in October 1999 with a complaint of blurred vision, which was worse in the right eye.

He was in good general health and was not hypertensive. Aided VA was 5/60 in the right eye and 6/60 in the left, and the intraocular pressure in both eyes was normal. The right fundus had PDR with a florid NVD, while the left fundus showed severe non-proliferative diabetic retinopathy. Initial PRP, using the diode laser, was carried out on both eyes in October 1999, with 1800 burns administered to each eye and using the same general laser settings as for the earlier two patients. The NVD in the right eye did not regress and remained florid even after two supplemental diode laser treatments, one early in the year 2000 (940 burns) and the other in mid-2000 (815 burns). Visual acuity in the right eye remained unchanged (5/60), while that in the left eye, where the fundus remained quiescent, improved slightly to 6/36.

#### DISCUSSION

The pertinent issues that need to be addressed in discussing the failure of neovascularization (NV) to regress in proliferative diabetic retinopathy (PDR) following seemingly adequate initial and supplemental pan-retinal laser photocoagulation (PRP) as recorded in the 3 patients in this paper are: the adequacy of laser treatment, the presence of concomitant retinal ischaemia,

the duration and type of diabetes mellitus, and the presence of posterior vitreous detachment.

The optimal amount of laser treatment and the need for additional laser treatments were not addressed by the Diabetic Retinopathy Study Group (DRSG), which established the efficacy of PRP for proliferative diabetic retinopathy (PDR).<sup>7-9</sup> The beneficial effect of additional PRP in achieving regression has, however, been established by various studies.<sup>10-12</sup> A study, which attempted to quantify the amount of retinal laser burns needed to achieve regression, concluded that the number of initial treatments required for regression might be considerably more than that recommended by the DRSG.<sup>14</sup> It is therefore conceivable that all things being equal, the three patients discussed might have had their NV regressed if their initial PRP had utilized a much greater number of laser burns than the 1,200 to 1,600 evenly spaced 500um size burns that the DRSG protocol recommended.

Concomitant retinal ischaemia from poor diabetic control, hypertensive retinopathy and carotid artery obstruction are other factors that could worsen retinopathic changes in PDR. Hence, ophthalmologists should liaise with the managing physicians of diabetic patients, particularly those with resistant NV, in order to rule out this factor as a cause of persistence of neovascularization. Though there was evidence of retinal ischaemia in all three patients from their PDR, they neither had hypertensive retinopathy nor carotid artery obstruction.

Extensive PRP was required for patients who had had diabetes for more than 15 years (i.e., two of the three case studies), and those who had diabetes mellitus before the age of 30 years.<sup>14</sup>

The presence of posterior vitreous detachment provides the scaffold for fibro-vascular proliferation in NV; hence it may be difficult to achieve regression of NV in such an eye following laser treatment.

Argon green laser was used for the first two patients who were managed in Saudi Arabia, while the third patient who was managed in Nigeria had diode laser. Both types of laser treatment compare favourably.<sup>15</sup>

Apart from the regression of NV, the additional signs that indicate efficacy of PRP in PDR include decrease in retinal venous dilatation, absorption of retinal haemorrhages, and mild disk pallor. Once quiescence of PDR is achieved, patients maintain stable vision. This total package of signs should be borne in mind by the ophthalmologist in judging the success of PRP in laser treatment, as some NV may never regress completely.

Further management options in cases of non-regression include: supplemental PRP and targeting laser burns to gaps or skips in the retina from earlier PRP (This was done for all the 3 patients). The other options which were not utilized in this study include the

application of xenon arc photocoagulation to areas with previous laser burns, especially in instances where there are no gaps or skip areas in the retina. Cryotherapy is especially recommended for application to the anterior retina in eyes with opaque media from cataract or vitreous haemorrhage. Some eyes may, therefore, be saved by using cryotherapy, which is relatively more commonly available in the developing world. The last option is to resort to vitrectomy, which will allow for any needed microsurgical handling of the various pathological entities facilitating non-regression of NV.

## CONCLUSION

Despite adequate initial and supplemental PRP in the three cases studied, NV failed to regress. It is recommended that a more extensive treatment than the currently recommended ones be made at initial PRP sessions. Also liberal use of supplemental laser sessions is recommended for non-regressing NV. For persisting NV, the choice of other options such as xenon arc photocoagulation, trans-scleral cryotherapy and vitrectomy will depend on the availability of these facilities and also on the associated proliferative diabetic complications that would also need to be treated.

## ACKNOWLEDGEMENT

I thank the authorities of El-Maghraby Eye Hospital, Jeddah, Saudi Arabia, for allowing me to be a part of the management of the first two patients who presented while I was undergoing a one-year clinical vitreoretinal sub-specialty training there (1995-1996).

## REFERENCES

1. Mahmoud AO, Kyari F, Ologunsua Y. Initial experience with the utility of the infrared diode laser in Kaduna, Nigeria. *Nigerian Journal of Ophthalmology* 2002; 1(1): 37-44.
2. Hassan AO, Oderinlo O, Okonkwo, O. Visual outcome after laser photocoagulation for stage 4 proliferative sickle cell retinopathy. *Nigerian Journal of Ophthalmology* 2004; 12(1): 19-22.
3. Nwosu SNN. Diabetic retinopathy in Nnewi, Nigeria. *Nigerian Journal of Ophthalmology* 2000; 8 (1): 7-10.
4. Magulike NO, Chuka-Okosa CM, Oli JM. Diabetic eye disease in Enugu, South Eastern Nigeria - A preliminary report. *Nigerian Journal of Ophthalmology* 2003; 11(1): 30-33.
5. Abiose A. Retinal diseases in Nigeria - A preliminary report. *Niger Med J* 1978; 6(2): 180-183.
6. Osuntokun BO. Diabetic retinopathy in Nigerians. *Br J Ophthalmol* 1969; 53: 652.
7. Diabetic Retinopathy Study Group. Preliminary report on effects of photocoagulation therapy. *Am J Ophthalmol* 1976; 81: 383.

8. Diabetic Retinopathy Study Group. Photocoagulation treatment of proliferative diabetic retinopathy: The second report of the diabetic retinopathy study findings. *Ophthalmology* 1978; 85: 82.
9. Diabetic Retinopathy Study Research Group: Four risk factors for severe visual loss in diabetic retinopathy: The third report of the diabetic retinopathy study. *Arch Ophthalmol* 1979; 97: 654.
10. Aylward GW, Pearson RV, Jagger JD, Hamilton AM. Extensive argon laser photocoagulation in the treatment of proliferative diabetic retinopathy. *Br J Ophthalmol* 1989; 73(3): 197-201.
11. Daft BAH, Metz DJ, Kelsey SF. Augmentation laser for proliferative diabetic retinopathy that fails to respond to initial pan-retinal photocoagulation. *Ophthalmology* 1992; 99(11): 1728-34.
12. Vine AK. The efficacy of additional argon laser photocoagulation for persistent, severe proliferative diabetic retinopathy. *Ophthalmology* 1985; 92(11): 1532-7.
13. Doft BH, Blakenship G. Retinopathy risk factor regression after laser pan-retinal photocoagulation for proliferative diabetic retinopathy. *Ophthalmology* 1984; 91(12): 1453-7.
14. Reddy VM, Zamora RL, Oik RJ. Quantitation of retinal ablation in proliferative diabetic retinopathy. *American Journal of Ophthalmology* 1995; 119: 760-766.
15. Bandello F, Brancato R, Trabucchi G, Lattanzio R, Malegori A. Diode versus argon-green laser pan-retinal photocoagulation in proliferative diabetic retinopathy: A randomized study in 44 eyes with a long follow-up time. *Graefes Arch Clin Exp Ophthalmol* 1993; 231(9): 491-4.