

# PRESUMED CHLOROQUINE RETINOPATHY IN IBADAN

**BGK Ajayi** MBBS, FMCophth, FWACS, MHS (Johns Hopkins)  
Ojulowo Eye Clinic, Ibadan

**CO Bekibele\*** MBBS, FMCophth, FWACS  
Department of Ophthalmology, University College Hospital, Ibadan

## SUMMARY

**Objective:** To review patients with clinical features of chloroquine retinopathy seen during the study period with the view of identifying the trend and creating public awareness for behavioural change.

**Methods:** A retrospective review of case notes of patients seen between 1996 and 2002.

**Results:** 19 patients with features of presumed chloroquine retinopathy were reviewed: 5 women and 14 (73.7%) men. The age range is: 36-69 years, mean 50.7 years. Approximately 63% were civil servants, health care workers and teachers. Duration of chloroquine use ranged from six months to ten years, with a mean of 4.1 years. Total cumulative dose ranged from 10 gm to 312 gm, with a mean of 108 gm. Best corrected visual acuity of subjects ranged from 6/5-CF, mean 6/18.

**Conclusion:** The majority of people using large amounts of chloroquine over long periods are educated, middle-aged males, whose loss of vision would have far reaching effects on their families. There is, therefore, a need to create public awareness of the danger of long-term chloroquine use. A follow up national survey would be desirable to determine the actual magnitude of the problem.

**Key words:** chloroquine, retinopathy, irreversible blindness

## INTRODUCTION

Chloroquine is a 4-aminoquinoline compound, used in the treatment of malaria fever, rheumatoid arthritis and systemic lupus erythematosus. In the doses used to suppress or treat malaria, the toxic effect of chloroquine and its derivatives are only minor and have not

impaired their usefulness. In higher doses on the other hand, more serious side effects have been known since the earliest trials with chloroquine in the 1950s.<sup>1</sup>

High doses of chloroquine are commonly used in the treatment of lupus erythematosus and rheumatoid arthritis. The effective doses commonly used exceed that used in treating malaria, as the drug is administered over much longer periods.

A recent trend, however, is the use of chloroquine as a malaria prophylaxis for extended periods without considering the consequences, especially in malaria endemic regions. This results in the toxic accumulation of the drug.<sup>2,3</sup> Minor undesirable effects of chloroquine therapy include, dyspepsia, an initial disturbance in accommodation and sometimes paresis of ocular muscles with high doses. These minor effects usually disappear when the dose is reduced or treatment is stopped. Corneal deposits are another side effect of extended chloroquine use.<sup>4</sup> However, these deposits rarely cause visual disturbance and in most cases disappear within a few weeks of ceasing treatment.

A more serious complication of chloroquine therapy is toxic retinopathy which can be associated with bilateral irreversible blindness.<sup>5</sup>

This study has reviewed patients seen over a period of six years with clinical features of chloroquine retinopathy and a positive history of chloroquine abuse in the absence of other possible causes of toxic maculopathy. The aim was to study the pattern and to use the findings as a starting point in planning a chloroquine retinopathy survey as well as creating sufficient public awareness, so as to prevent further abuse of chloroquine in the community.

## MATERIALS AND METHODS

A retrospective review of case notes of patients seen over a period of six years from 1996 to 2002 was carried

\*Author for correspondence

Note: The research on which this paper is based was carried out at the Ojulowo Eye Hospital, Ibadan.

out at the University College Hospital, Ibadan and the Ojulowo Eye Hospital, Ibadan.

Patients diagnosed as having chloroquine toxic retinopathy were identified from the out-patients register and case notes were retrieved and studied. The diagnosis of chloroquine retinopathy was made on clinical grounds: patients complained of reduced vision, typical concentric pigmentary change in the fovea comparable to a bull's eye target appearance. All patients admitted to abuse of chloroquine at some time as a prophylaxis. Patients who had used other systemic drugs such as, phenothiazines and tamoxifen for prolonged periods were excluded. Some of the patients had confirmatory visual field tests, a few others also had associated depressed colour vision. None, however, had the Amsler grid test, fundus photography or electroretinogram study done.

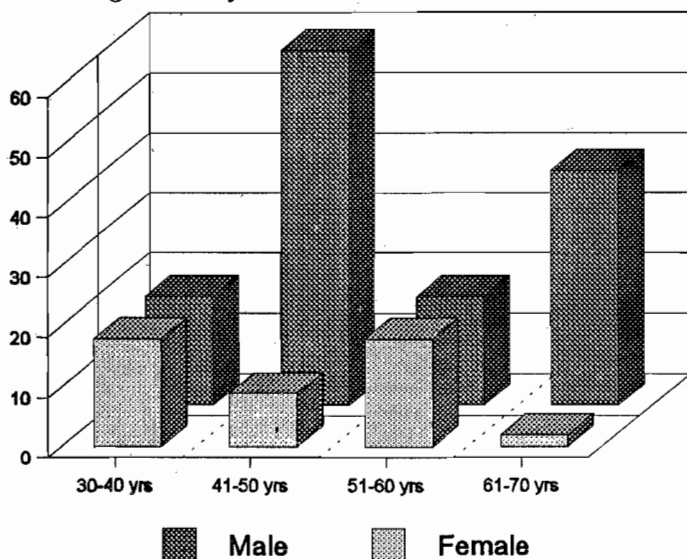


Figure 1. Age and sex distribution of 19 presumed chloroquine retinopathy patients

All case notes were reviewed according to a standard protocol for the following variables: age, sex, occupation, systematic disease present in the patient, duration of chloroquine use, dose of chloroquine taken regularly, an estimate of cumulative dose, daily dose and best corrected visual acuity in the patient.

**RESULTS**

A total of 19 patients with features of presumed chloroquine retinopathy were reviewed. There were 14 (73.7%) men and 5 (26.3%) women. Their ages ranged from 36 to 69 years, with a mean of 50.7 years (see figure 1).

An examination of the occupation of the subjects concerned showed (table 1) that majority (62.7%) were civil servants, health care personnel and teachers with some level of higher education.

Other systemic diseases were found in 4 subjects (21%); comprising diabetes (1) and hypertension (3).

Duration of chloroquine use ranged from 6 months to 10 years, with 5 years as the greatest frequency of use. In some cases, however, the duration could not be specified.

Table 1. Occupational distribution of presumed chloroquine retinopathy patients

Occupation	Number	Per cent
Civil servant	5	36.80
Nurse/health officer	3	15.00
Teacher	2	10.50
Farmer	2	10.50
Mechanic	1	5.20
Not specified	3	15.00
Total	19	100.00

Cumulative dose ranged from 10gm (taken within a period of one year at a dose of 1 tablet weekly) to 312gm (at a dose of 1 tablet twice weekly for 5 years).

The best corrected visual acuity in the patients ranged from 6/5 to count fingers. The mean visual acuity was 6/18 and a reciprocal relationship existed between the cumulative dose and the best corrected visual acuity. The higher the dose, the worse the visual acuity for a majority of the patients, except in two cases (see table 2 and figure 2). Figures 3a and 3b show the visual field of a patient with advanced chloroquine retinopathy with loss of central fixation in both eyes.

Table 2. Profile of 19 patients with presumed chloroquine retinopathy

Characteristic	Range	mean
Age	36-39 yrs	50.7 yr
Duration of C/Q abuse	6 mth -10 yrs	4.1 yr
Cumulative dose	10-312 gm	108.0 gm
Average daily dose	26.3-171 mg	87.0 mg
Best corrected visual acuity	6/5 CF	6/18 CF

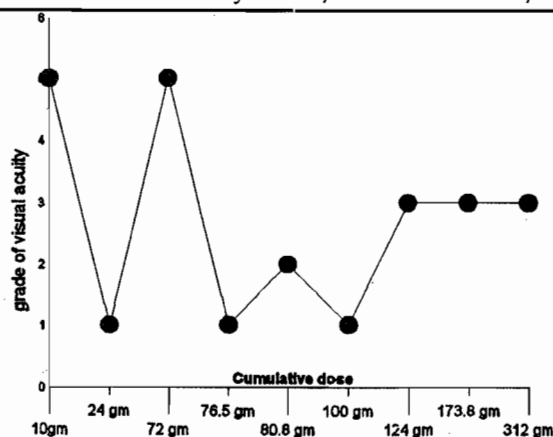


Figure 2. Cumulative dose increase on visual acuity



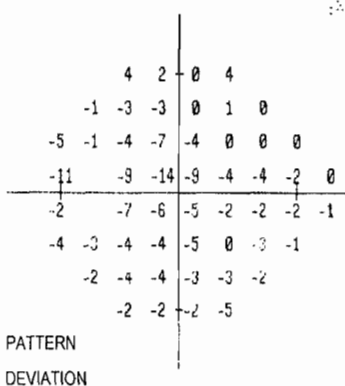
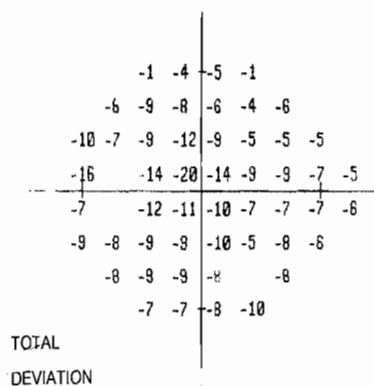
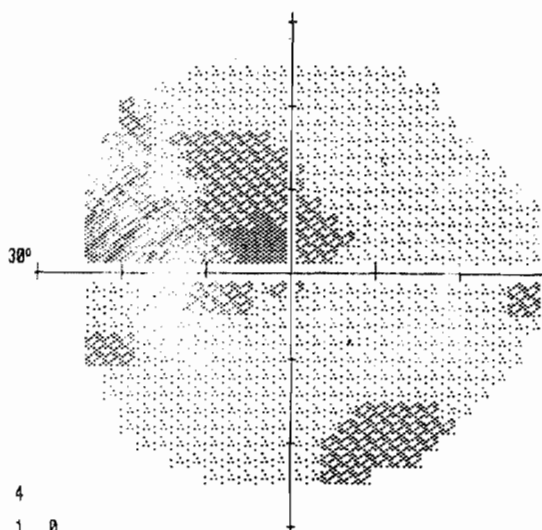
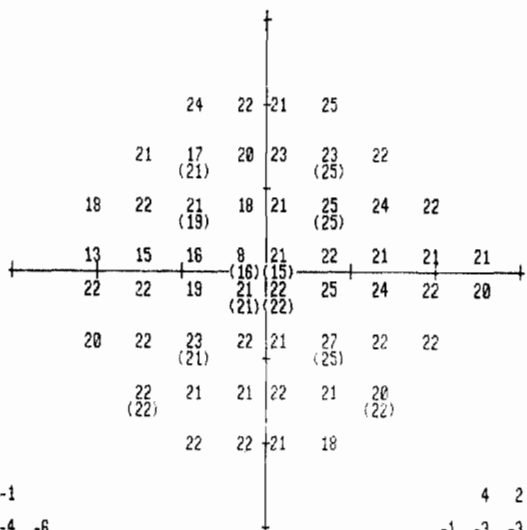
CENTRAL 24 - 2 THRESHOLD TEST

LEFT

STIMULUS III, WHITE, BCKGND 31.5 ASB BLIND SPOT CHECK SIZE OFF  
STRATEGY FULL THRESHOLD

BIRTHDATE 10-30-47 DATE 03-18-03  
FIXATION TARGET CENTRAL ID TIME 10:24:57 AM  
RX USED +3.00 DS DCX DEG PUPIL DIAMETER VA

AGE 56  
FIXATION LOSSES 0/0  
FALSE POS ERRORS 0/10  
FALSE NEG ERRORS 0/9  
QUESTIONS ASKED 329  
TEST TIME 11:28  
HFA S/N 640-3898



GLAUCOMA HEMIFIELD TEST (GHT)  
OUTSIDE NORMAL LIMITS

MD -8.74 DB P < 0.5%  
PSD 3.60 DB P < 5%  
SF 1.29 DB  
CPSD 3.33 DB P < 1%

TOTAL  
DEVIATION

PATTERN  
DEVIATION

PROBABILITY SYMBOLS

- ∴ P < 5%
- ⊗ P < 2%
- ⊠ P < 1%
- P < 0.5%

COPYRIGHT 1999

REV 9.5

SYM										
ASB	.8	2.5	5	10	25	79	251	794	2512	7943
DB	41	36	31	26	21	16	11	6	1	0
	50	40	35	30	25	20	15	10	5	0

HUMPHREY SYSTEMS

Figure 3b. Central visual field, left eye of advanced chloroquine retinopathy patient(visual acuity counting fingers)

**DISCUSSION**

Chloroquine has been used for the treatment of malaria for over five decades without much problem because the effective dose is less than the toxic dose which is achieved only when the drug is used for other purposes such as in the treatment of lupus erythematosus and rheumatoid arthritis.

A recent study in Lomé, (Togo) <sup>2</sup> confirmed the retinal toxicity of chloroquine when used as a prophylactic for the prevention of malaria at a cumulative dose of over 185gm in 18 patients seen.

Our study has, however, identified a mean toxic dose of 108gm when chloroquine is used for the treatment or prevention of malaria using a continuous ten-tablet weekly course for one year. It should, however, be noted that it is possible to have retinal toxicity from chloroquine use for a short period at a cumulative dose of less than 100 gm as reported by a chloroquine retinopathy incidence study in which the use of a relatively small amount of the drug (24 gm) over 2 months was associated with retinopathy.<sup>5</sup> Thus it could be said that some differences exist in the individual predisposition to chloroquine retinopathy, partly based on differences in individual ability to metabolise and excrete the drug.

A linear correlation between the cumulative dose and severity of ocular damage as shown by a decreased visual acuity was observed in this study.

Most of the patients (62.7%) were educated and included health care personnel who should have been aware of the side effects of prolonged use of chloroquine. The majority were also middle-aged males and the main support of their families.

The need for concerted efforts to increase public awareness about the dangerous effects of prolonged chloroquine ingestion to the eye is particularly important in a malaria endemic country like Nigeria, where many members of the public use chloroquine to control and prevent malaria infection.

It is still unclear how chloroquine affects the ocular structures, but it is known that the parenchymal organs such as the kidneys, liver, spleen, and lungs retain chloroquine in a concentration several hundred times higher than in the blood. The concentration is higher still in melanin containing tissues such as the iris, choroid and pigmented epithelium of the retina. On continuous administration, large deposits are formed in the tissues and it can still be demonstrated five years after the last dose when long-term treatment is discontinued.<sup>1</sup>

A typical description of chloroquine retinopathy was reported by Hobbs et al. in 1959.<sup>8</sup> These appear in the form of narrow, constricted retinal vessels, pale disc, irregular patchy pigmentation in the periphery of the retina and circular increase in the pigments around the fovea (bull's eye appearance). There is an associated decreased visual acuity and visual field defects in the form of para-central scotomas, as well as impaired

vision and night blindness. Other changes which have been reported include, abnormalities of the electro retinogram pattern,<sup>5</sup> defective colour vision and abnormal fluorescein angiogram.<sup>6</sup> Pathological changes<sup>7</sup> seen in the eyes of chloroquine retinopathy patients include sclerosis of choroidal vessels and choriocapillaries, destruction of cones and rods in the retina, with earlier lesions characterized by loss of the outer segments of the cones and rods. The rods and cones in the fovea may remain intact for a long time. The bipolar and ganglion layers may remain normal. The pigmented epithelium loses the intra-cellular pigment which migrates in the form of clumps to the inner nuclear layer. In contrast to retinitis pigmentosa, the pigment shows no tendency to proliferate nor is there any perivascular accumulation of pigment. The cause of the retinopathy remains unclear but may be due to retinal photoreceptor damage from an impeded diffusion of nutrients between the choriocapillaries and the photoreceptors (sclerosis of the choriocapillaries and accumulation of chloroquine in the retina pigment epithelium) or possibly a direct toxic effect on the photoreceptors/neurons (enzymatic inhibition).<sup>1</sup> Whatever the mechanism, accumulated chloroquine results in bilateral irreversible blindness with much suffering for the patient.

**CONCLUSION AND RECOMMENDATIONS**

Excessive use of chloroquine as a prophylactic for malaria is toxic to the eyes. A national survey may be required to determine the magnitude of the problem. There is an urgent need to create sufficient public awareness about the danger of chloroquine abuse so as to reduce the number of people becoming blind from chloroquine retinopathy. Ophthalmologists also need to be sensitised to look out for features of chloroquine retinopathy and carry out appropriate tests in suspected cases.

**REFERENCES**

1. Nylander U. Ocular damage in chloroquine therapy. *Acta Ophthalmol* 1966; 335-348.
2. Balo KP, Mensah A and Mihluedo H. Chloroquine maculopathy and prevention of malaria. *J Français d Ophthalmol* 1996; 19 (12): 770-6.
3. Puavilai S, Kunavisarut S, Vatanasuk M, Timpatanapong S et al. Ocular toxicity of chloroquine among Thai patients. *Int J Dermatol* 1999; 38 (12): 934-7.
4. Sandvig K. Chloroquine (resochoin) effects in the cornea. *Acta Ophthalmol* 1996; 355-60.
5. Voipio H. Incidence of chloroquine retinopathy. *Acta Ophthalmol* 1966; 349-54.
6. Linda Vu BL, Easterbrook M and Hovis JK. Detection of colour vision defects in chloroquine retinopathy. *Ophthalmol* 1999; 106 (9): 1799-804
7. Bernstein HN and Ginsberg S. *Arch Ophthalmol* 1964; 71: 238.
8. Hobbs HE, Sorsby A and Freedman A. Retinopathy following chloroquine therapy. *Lancet* 1959; Z: 478-480.