

Waardenburg's Syndrome in a Nigerian Family

ONABOLU O.O

Dept Of Ophthalmology Obafemi Awolowo College of Health Sciences OSUTH
Sagamu

SUMMARY:

Waardenburg's Syndrome {WS} is described in two girls of a Nigerian family. Both girls presented with white forelock, heterochromia irides and sensorineural deafness. WS is inherited as an autosomal dominant gene with variable penetrance and phenotypic expression. It is divided into four clinical sub types according to mutations in the genes responsible for melanocyte proliferation and differentiation. There is no history suggestive of Waardenburg's syndrome in this family. The wide difference between the ages of the father and the mother {30years}, and the old age of the father {65 years} is believed to be responsible for a new mutant gene in the family. Deafness, which is the most disabling feature of this syndrome should be identified early to prepare the child for proper education.

KEY WORDS: *Waardenburg's Syndrome, genetic mutation, deafness.*

INTRODUCTION

In 1951, Waardenburg in Holland studied 1,050 cases of congenital deafness and described a syndrome which is now associated with his name.¹ This syndrome consists of lateral displacement of the medial canthi combined with dystopia of the lacrimal puncta. Other features include blepharophimosis, prominent root of the nose, growing together of eyebrows with hypertrichosis of medial portion, white forelock, partial or complete heterochromia irides and congenital deafness. Several reports of this syndrome had appeared in the literature since then.² It is inherited as autosomal dominant gene.

Waardenburg's Syndrome (WS) is clinically and genetically heterogeneous and is divided into four clinical subtypes. Mutations in the gene encoding the transcription factor Pax3 has been identified in WS1 and WS.³ Mutations in Sox10 gene or endothelinB receptor or endothelin-3 gene has been shown in WS4.⁴ WS2 is thought to be a heterogeneous group with about 10% of cases caused by mutation in microphthalmia associated transcription factor (MITF).⁴ MITF is important in the development and subsequent function of the neural crest derived melanocytes.⁵ WS has been associated with other congenital abnormalities notably Hirschsprung's disease (aganglionic megacolon).⁶

We report Waardenburg's Syndrome WS2 in a Nigerian family in which the probands are sisters. The possibility of genetic mutation in this family is considered.

CASE PRESENTATION

Two sister O. O. and S. O., three years and ten months respectively were seen in the eye clinic of Ogun State University Teaching Hospital, (OSUTH) Sagamu with history of multicoloured irides and deafness since birth. Their mother, 33 year old was the third and youngest wife of a 65 year old man in a non-consanguineous marriage. There was no history of congenital deafness or white forelock in both families. The other two wives of the father had unaffected children. The sisters had a seven year old brother who was not affected. Pregnancy and delivery were normal. She claimed not to have ingested any herbal preparation during pregnancy. On examination, the sisters were deaf. Audiometry report confirmed complete sensorineural deafness (Fig1) The younger sister had a white forelock (Fig2). The hair of the elder sister was brown. The mother claimed that she had a white forelock soon after birth but it gradually turned brown after her first birthday. They were too young to have visual acuity check and it was not possible to communicate with them. However they could follow light. The older sister had grayish blue irides except for a small brown patch on the temporal side

of the right eye (Fig3). The younger sister had patchy grayish blue irides in both eyes. Fundoscopy showed normal non albinotic retinæ. The children had no systemic abnormality. After one year, The white forelock of the younger sister had turned brown.

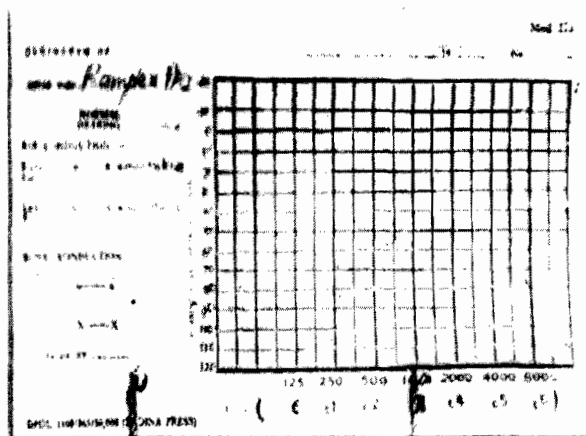


Figure 1: Audiometry Reading 1st Patient (No Response)



Figure 2: White Forelock in Younger Sister

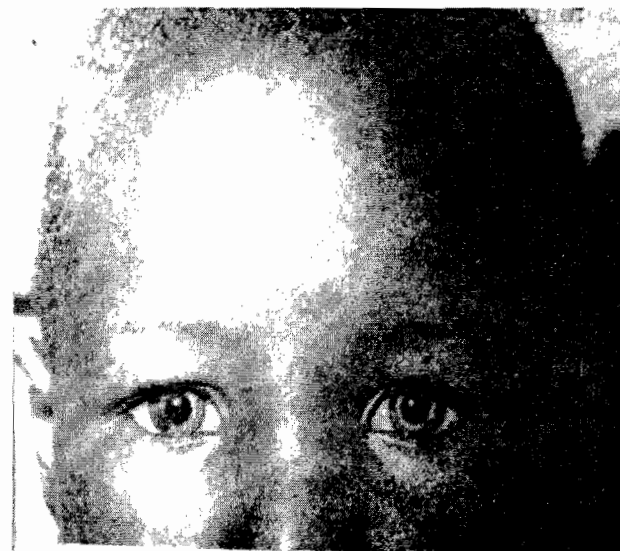


Figure 3: Heterochromia Irides

COMMENT

When Waardenburg examined 1,050 children in several deaf schools in 1951 only 23 of them had one or all the features. Several reports had appeared in the literature suggesting a strong family history.⁷ However some cases with no family history are believed to be the result of genetic mutations.⁸ Our patients had no family history of WS. We believe that this may be due to a fresh gene mutation. About a quarter of cases of WS with eyelid deformity are due to a fresh gene mutation. Corroborative evidence of fresh mutations may be afforded by parental ages at the birth of the child. In a study of 10 cases carried out in Britain, Eire and Australia, the mean paternal age was 41.5 years while mean maternal age was 34.9 years.⁹ The mean difference between the paternal and maternal ages in this study was 6.6 years as opposed to 2-4 years. This may explain a fresh gene mutation in this family although the girls did not have lid deformities. The first boy was not affected suggesting the varying phenotypic expression.

The presence of white forelock in older members of the family may be difficult to ascertain as the colour may change with age.¹⁰ This was demonstrated in the elder sister whose white hair had changed to brown at presentation. The same change was later noted in the younger sister.¹¹ Arias had reported premature greying of hair in WS and a family with black forelock. Deafness, which is the most disabling feature in WS can be unilateral or bilateral and may be related to the side of depigmentation in the iris and retina.⁴ It is caused by absence of melanocytes from the cochlea.¹² The girls in this presentation had complete sensorineural deafness.

CONCLUSION

Waardenburgs Syndrome has different phenotypic expression the most disabling being deafness. It would appear that fresh gene mutation in elderly men can be a causative factor, Genetic counselling is necessary in societies where elderly men marry young women. Children with white forelock should be examined for deafness to prepare them for proper education.

REFERENCES

1. Waardenburg PJ. A new Syndrome combining developmental anomalies of the eyelids, eyebrows and nose root with pigmentary defects of the iris and head hair with congenital deafness. *Am. J. Hum Gen*, 1951;3:195.
2. Di George AM, Omstaed RW, Harley RD. A Syndrome of heterochromia irides, lateral displacement of the medial canthi, and lacrimal puncta, congenital deafness and other characteristics of associated deafness. *J. Paed.* 1960;57:649-651.

3. Tomita Y, Miyamura Y, Kono M, Nakamura R, Matsunaga J. Molecular basis of congenital hypopigmentary disorders in humans and oculocutaneous albinism 1 in Japan. *Pigment-Cell-Res.* 2000;13 Suppl 8130-4.
4. Mullner-Eidenbock A, Moser E. Waardenburg Syndrome type 2 in a Turkish family: implications for the importance of the pattern of fundus pigmentation. *Br. J. Ophthalmol* 2001;85(11):1384-1386.
5. Tachibana M. MITF: a stream flowing for pigment cells. *Pigment-Cell-Res.* 2000;13(4):230-240.
6. Omen GS, McKusick VA. The association of Waardenburg Syndrome and Hirschsprung megacolon. *Am. J. Med. Genet.* 1979;3:217-223.
7. Newton WV. Hearing loss in Waardenburg Syndrome: Implications for genetic counselling. *J. Laryngol. Otol.* 1990;104(2):97-103.
8. Jones KL, Smith DW, Harvey MAS, Hall BD, Quan L. Older paternal age and fresh gene mutation data on additional disorders. *J. Paed.* 1975;86:84-88.
9. Fraser GF. In the causes of profound deafness in childhood. Publisher Balliere Tindall London. Pg128-132.
10. Freingold M, Robinson MJ, Gellis SS. Waardenburg Syndrome during the first year of life. *J. Paed.* 1967,71:871-876.
11. Arias S. Genetic heterogeneity in the Waardenburg Syndrome. *Orig. Art Ser.* 1971;V11(4):87-101.
12. Verastequi C, Bille K, Ortonne JP, Balloti R. Regulation of the microphthalmia-associated transcription factor gene by the Waardenburg Syndrome type 4 gene Sox10. *J. Biol. Chem.* 2000 Oct6;275(40):30757-60.