

Mixed Strokes: (Three Case Reports) with Literature Review

1. Dawodu C . O., 2. Odewole O. A. T.

1. 2. M.B.B.S (Jos, Ilorin), 1. FMCP (neurology)

1. 2. Department of Medicine, Lagos State College of Medicine, Ikeja, Lagos.

1. brainattack2003@yahoo.com.

PREAMBLE

Concurrent clinical presentation of ischaemic and haemorrhagic strokes can only be revealed convincingly with neuroimaging studies. Clinically at presentation, which pathological type (ischaemia or haemorrhagic) precedes the other was appreciated clinically in case I; queried at presentation for case II; was not entertained for case III.

KEYWORDS ISCHAEMIC, HAEMORRHAGIC, STROKE

INTRODUCTION

The prevalence rate of cerebrovascular accident is 114/100,000 in Nigeria¹. The risk factors are similar in both types of strokes but with varying degrees of associations though, differences do exist.²

The pathophysiology of concurrent presentation can be explained as thus; sequel to aneurysm rupture is arterial vasoconstriction with marked arterial vasospasm following subarachnoid haemorrhage results in brain ischaemia and secondary infarction (more severe by seven days).³ A haemorrhagic infarction results from leakage of blood into infarcted tissue usually resulting from delayed restoration of circulation after tissue necrosis has occurred e.g. as with vascular obstruction by embolism which then breaks apart allowing blood flow to resume.³ Symptomatic vasospasm has been defined as documented arterial vasospasm consistent with new neurological deficits presenting within 21 days after onset of a subarachnoid haemorrhage and not explained by other causes of neurological deterioration.⁴ Rabinstein et al defined post haemorrhage cerebral infarction as a new hypodensity located in a vascular distribution on computed tomogram (CT scan).⁴

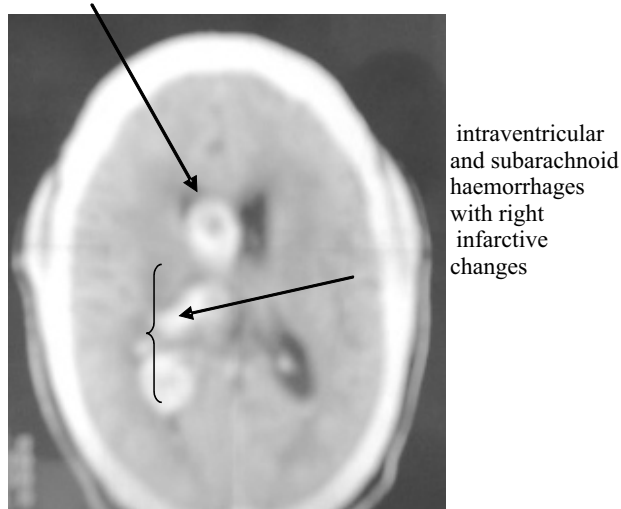
Location of the cerebral infarction on delayed CT scan was predicted by neurological symptoms in 74%, by aneurysm location in 77% and by angiographic vasospasm in 67%. In another study, incidence of brain infarction resulting from vasospasm varies according to the imaging technique used for diagnosis. Rates of cerebral infarction ranged between 24% and 35% in recent studies using CT scan, but were much higher when relying on magnetic resonance imaging (MRI) to identify ischemic lesions, reaching up to 81% in one of the largest series.⁵

Advances in MRI is said to predict the likelihood of hemorrhagic transformation in early ischaemic changes.⁶ The Alberta stroke program early CT scores (ASPECTS) might be of benefit to confirm and monitor radiological dual pathologies. A normal CT scan has an ASPECTS value of 10 points whilst a score of 0 indicates diffuse ischaemia throughout the arterial territory.⁷ Benefits can be obtained from any neuroimaging studies of choice; CT scan ± MRI.

CASE SUMMARY I

A 41 year old monogamous medical practitioner with 2 kids, known hypertensive slumped at home on the 23/02/2006. The wife said prior to that he had complained of restlessness and headache. He later described features of on and off hemi-crania 6 months prior to presentation. Clinically he was a right handed man with a Glasgow coma scale of 13; all meningeal signs were positive; grade 3 left

FIGURE I (caseI)



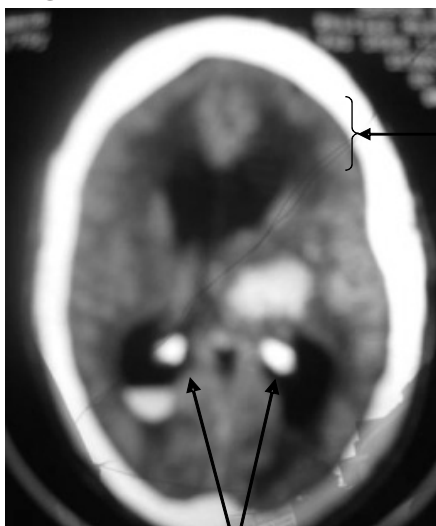
spastic hemi paresis. In the cardiovascular system his pulse rate was 64 beats/minute, blood pressure of 180/110mmhg. Heart sounds S1, S2 and a soft A2. He developed clinical signs of a raised intracranial pressure within 24 hours on admission (bilateral 6th nerve palsies and a Cushing's reflex). His computed tomogram showed both intraventricular and subarachnoid haemorrhages with infarctive changes on the right. He decompensated into a left ventricular failure on the 14/03/2006. He was subsequently discharged (walked without assistance with a blood pressure of 120/100mmhg) after a month and has been seen a couple of times on an out-patient basis. His

visit on the 05/01/07 he complained of hyperaesthesia of the affected half; residual grade 4+ distal muscle weakness, blood pressure 130/100mmhg however he has resumed medical practice with a proviso of not taking calls and delegating administrative duties to hired staff. His routine check-up on the 29/01/08; blood pressure was 120/70mmhg but an obvious compensatory head bending secondary to hemianopia. His blood pressure yo-yoed for a year, before appreciable stabilization. Follow up is now once in 6 months. (Figure I)

CASE SUMMARY II

A 70 year polygamous old man was admitted via the medical emergency on the 14/08/2006 with a history of inability to speak and sudden collapse. He had been a known hypertensive for the past 20 years. He was right handed with a Glasgow coma scale of 6, was motor aphasic with a grade 0 left dense spastic hemiplegia. He had a regular pulse rate of 72 beats/minute and a presenting blood pressure of 230/130mmhg. His computed tomogram showed bilateral haemorrhages with mildly dilated ventricles and left sided infarction (figure II). Notably on admission his blood pressure was swinging in the severe hypertension range. He was subsequently discharged [communicating better but not fluently and could walk with support] after 7 weeks on admission. He is yet to attain full power, but has an appreciable but poor control of blood pressure. However patient has been lost to follow up due to his children's social handicap.

Figure II (case II)



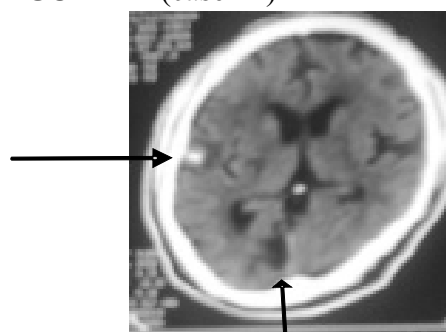
bilateral haemorrhages with mildly dilated ventricles and left sided infarction

CASE SUMMARY III

A 47 year old monogamous computer operator with a local daily with 4 kids, known hypertensive with a

positive dual parental history of diabetes mellitus. Inclusive was 4 pack years of smoking and cumulative 32gm of alcohol/week. The wife gave a two days history on the 14/12/2008 of sudden weakness on his left side and slurred speech. She said he did not complain of visual impairment. Clinically he was a right handed man with a Glasgow coma scale of 15, left upper motor neuron facial palsy and a motor aphasia. Examination of his motor system revealed a left dense normotonic and normoreflexic hemiplegia of grade 2. In the cardiovascular system his pulse rate was 60 beats/minute irregularly irregular, his heart rate was 100beats/minute, thus a pulse deficit of 40, blood pressure of 190/120mmhg. An apical heave with a displaced apex beat in the 6th left intercostal space anterior to the axillary line. Heart sounds S1, S2 and a soft A2 with multiple ectopic beats. Cardiac laboratory results were conclusive of an end organ damage of hypertension. Blood investigations were supportive of renal decompensation. His computed tomogram showed a right parietal lobe haemorrhage and a right occipital pole infarct.

FIGURE III (case III)



right parietal lobe haemorrhage and a right occipital pole infarct

DISCUSSION

Haemorrhage is most efficiently excluded by CT scan, but can also be reliably done using MRI (T2-weighted and FLAIR [fluid-attenuated inversion-recovery] sequences). Diffusion-weighted imaging is the most sensitive way to detect acute infarction; it clearly shows ischemic changes beginning within minutes to a few hours after symptom onset.⁸

We did not request for MRI in our patients because our neuromaging aim was to exclude or confirm a haemorrhagic stroke. Vessel flow abnormalities can be detected indirectly by CT scans and directly by CT angiography, but better still with MRI.⁹

Our third patient actually had an occipital infarction with no clinical manifestations. This could be a chance finding. Incidental finding of an infarction secondary to occlusion of a major artery with no clinical manifestation is possible provided there are good collaterals.¹⁰

Although severe uncontrolled hypertension is a common complication of stroke, the possibilities of dual pathologies could contribute to poor blood pressure control post stroke. Secondly two of our patients were in mild coma at some stages of management and the third patient was never comatose. However some diagnostic dilemmas do still exist.

CONCLUSION

Prompt neuroimaging studies should not be neglected on the background of poverty. This will minimize blind caution in delaying specific timely management goals.

REFERENCES

1. Okubadejo NU, Danesi MA, Ojini FI. Prevalence of Stroke in an Urban, Mixed-Income Community in Lagos, Nigeria. *Neuroepidemiology* 2007; 28: 216-223.
2. Bronner LL, Kanter SD, Manson JE. Primary prevention of stroke. *N. Eng. J of med.* 1995; 333 (21): 1392-1400.
3. Brumback RA, Leech RW. Pathology of cerebrovascular disease. In Hyde RM [ed] *Neuropathology and Basic Science*. 1st edition New York; Springer-verlog. 1995; 45-60.
4. Rabinstein A.A, Friedman J.A, Weigand S.D, McClelland .R.L, Fulgham J.R, Manno.E.M et al. Predictors of cerebral infarction in aneurysmal haemorrhage. *Stroke* 2004; 35(8):1862-6
5. Kidwell CS, Chalela JA, Saver JL, et al: Comparison of MRI and CT for detection of acute intracerebral hemorrhage. *JAMA* 2004; 292(15): 1823-30.
6. Fiebach JB, Schellinger PD, Gass A, et al: Stroke magnetic resonance imaging is accurate in hyperacute intracerebral hemorrhage: a multicenter study on the validity of stroke imaging. *Stroke* 2004; 35(2): 502-6.
7. Barber PA, Demchuk AM, Zhang J, Buchan AM. Validity and reliability of a quantitative computed tomography score in predicting outcome of hyperacute stroke before thrombolytic therapy. ASPECTS Study Group. Alberta Stroke Programme Early CT Score. *Lancet* 2000; 355(9216): 1670-1674.
8. Brant-Zawadzki M. Routine MR imaging of the internal carotid artery siphon: angiographic correlation with cervical carotid lesions. *AJR Am J Roentgenol* 1990; 155: 359-363.
9. Yuh WT, Crain MR, et al. MR imaging of cerebral ischemia: findings in the first 24 hours. *AJNR Am J Neuroradiol* 1991; 12: 621-629.
10. Ueda T, Yuh WT, et al. Current and future imaging of acute cerebral ischemia: assessment of tissue viability by perfusion imaging. *J Comput Assist Tomogr* 1999; 23: [Suppl 1] S3-S7.