

Disseminated Cutaneous Leishmaniasis in HIV positive patient - A Case Report

*Yusuf S M MBBS, MSC, FWACP, *Uloko A E BM BCh, FMCP.

*Adamu H A MBBS, MWACP *Iliyasu G MBBS, MWACP **Mohammed A M BM BCh, FMCPath

* Department of Medicine, Aminu Kano Teaching Kano Nigeria.

**Department of Pathology, Aminu Kano Teaching Hospital Kano Nigeria.

Abstract

Disseminated cutaneous leishmaniasis and HIV dual-infection is seldom reported. Leishmaniasis and HIV co-infection may intensify the immune defect and is the chief reason for atypical presentation and widespread progression of cutaneous leishmaniasis and its defiance to conventional therapy. Here we report a 38-year-old HIV-positive lady who presented with a 6-month history of a progressive papule and nodular eruptions of leishmaniasis on face, trunk and extremities that was recalcitrant to treatment.

Keywords: *Co-infection, Diffuse cutaneous leishmaniasis, HIV infection.*

Date Accepted for publication: 15th Oct 2009

Nig J Med 2010; 112-114

Copyright ©2010 Nigerian Journal of Medicine

Introduction

Human Leishmaniasis is usually classified as visceral, cutaneous and muco-cutaneous.¹ Human immunodeficiency virus (HIV) co-infection with cutaneous leishmaniasis (CL) may be associated with unusually severe presentations, higher rates of recurrence and re-infection and lower cure rates with established treatments. Disseminated (diffuse) leishmaniasis in HIV-positive patients is clinically characterized by multiple (>200), atypical, widespread infiltrations of skin lesions.²

Case report

A 33 years old woman presented with a 10 months history of asymptomatic skin lesions on the face trunks and limbs. The lesions started on the face and progressively spread to involve the trunk. She was diagnosed with HIV and had been on antiretroviral therapy (nevirapine, stavudine and lamivudine) for about 7 months.

Physical examination showed multiple, bilateral, asymmetrical, asymptomatic papulonodular lesions on face (Fig1), trunk, and extremities. Infiltrations of nasal mucosa were also found. There was no history of pain and pruritus, and there were no signs of ulceration and scarring. There was no lymphadenopathy and hepatosplenomegaly.

Laboratory investigations revealed a mild anaemia, HB 9.5g/dl. Liver function tests, urea, electrolytes and creatinine were all within normal limits. CD-4 T cell count was low (30 cells/mm³). Ultrasonography of abdomen was normal. Giemsa staining of scrapped materials from cutaneous lesions showed presence of 2-3 microns blue Leishman bodies. Histology of a punch biopsy specimen showed a dermis with macrophages containing great numbers of amastigotes with few lymphocytes or plasma cells (Fig3a&b). The patient was placed on fluconazole 200mg daily. Antiretroviral therapy was continued. Two month after commencement of therapy the papules and nodules became ulcerated and more widespread despite compliance with medication (fig 2). Unfortunately she was lost to follow up after her second visit.

Discussion

Leishmania species can cause a wide spectrum of cutaneous lesions in HIV-positive patients, the clinical variants of leishmaniasis and clinical status are largely determined by parasite species and host cell mediated immunity (CMI) response. Dissemination of lesions is determined by host immunogenic status. The species involved in diffuse (CL) lesions are *Leishmania braziliensis*, *Leishmania amazonensis*, and *Leishmania aethiopica*.

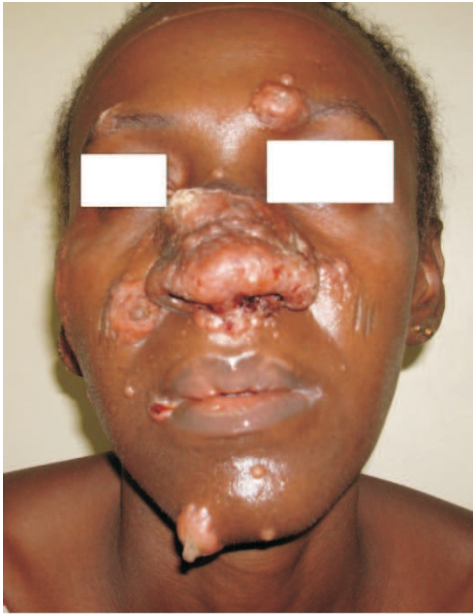

Fig. 1 papulonodular lesions at presentation

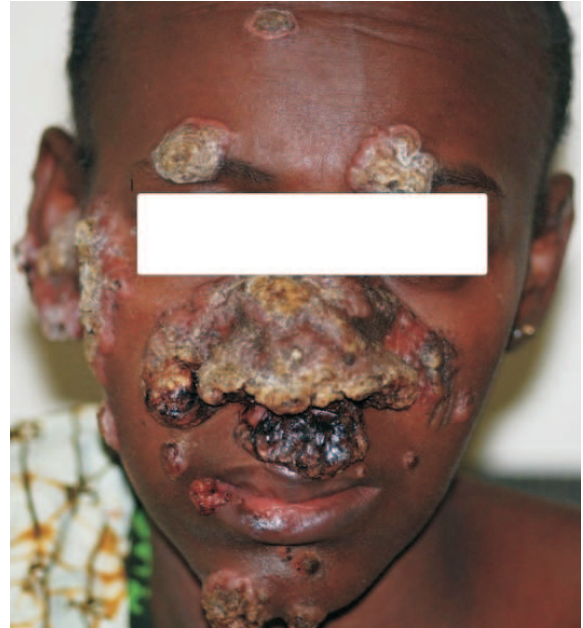

Fig. 2-ulcerated and crusted nodule second visit

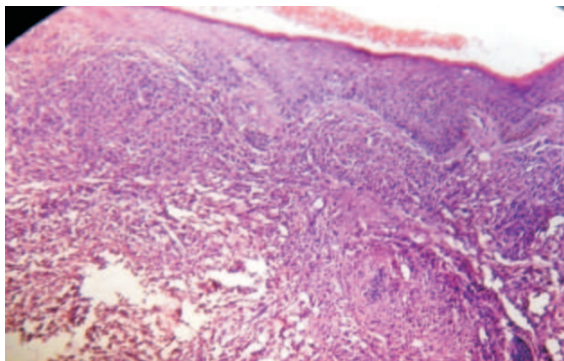


Fig. 3a huge numbers of amastigotes in histiocytes in dermal and subcutaneous tissue. X 40

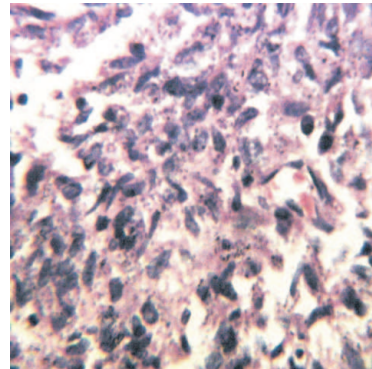


Figure 3b Huge numbers of amastigotes in histiocytes in X 100

Leishmaniasis and HIV co-infection may augment the immune defect by producing cumulative deficiency of the cell mediated immunity and increase disease severity and morbidity. HIV-infected patients quite often have an atypical and severe clinical presentation of CL in terms of number (>200), sites and types of lesions (papulonodular).^{3,4}

Although CL in visceral leishmaniasis has been reported more commonly with HIV infection, diffuse CL in the absence of visceral involvement has been reported as a first manifestation leading to the diagnosis of HIV infection.^{4,5}

Disseminated cutaneous leishmaniasis usually begins with an initial primary lesion and then disseminates to involve other areas of the skin. The lesions are non ulcerative nodules full of parasites, which are often scattered over the limbs, buttocks and face.⁶ The differentials of this type of lesions include lepromatous leprosy, lupus vulgaris, and deep fungal infections. High level of clinical suspicion and tissue smears with Giemsa are needed to make a diagnosis. Findings in biopsy lesions in diffuse CL and HIV co-infected patients are variable and can depend on immune status of the patients.

In most cases, a large and even huge numbers of amastigotes in histiocytes can be seen in dermal and subcutaneous tissue.⁷

Our case had failed to respond to the chosen medication, this is not surprising since diffuse forms of leishmaniasis were known many years ago

to be refractory to anti-leishmanial treatment. Although meglumine antimoniate, pentamidine are considered as first-line treatments in cutaneous leishmaniasis without HIV co-infection,⁸ we were cautious not to use such drugs on our patient for safety reasons.

References

1. Dedet JP, Pratlong F. Leishmaniasis. In: Manson P, Cook GC, Zumla A, editors. Manson's tropical diseases. 21st ed. London: Saunders; 2003. p. 1339-1364.
2. Sinha PK, Pandey K, Bhattacharya SK. Diagnosis and management of leishmania/HIV co-infection. Indian J Med Res 2005;121:407-414
3. Herrera E, Sanchez P, Bosch RJ. Disseminated cutaneous leishmaniasis in an HIV-infected patient. Int J STD AIDS 1995;6:125-126.
4. Niamba P, Goumbri-Lompo O, Traore A, Barro-Traore F, Soudre RT. Diffuse cutaneous leishmaniasis in an HIV-positive patient in western Africa. Australas J Dermatol 2007;48:32-34
5. Calza L, D'Antuono A, Marinacci G, Manfredi R, Colangeli V, Passarini B, et al. Disseminated cutaneous leishmaniasis after visceral disease in a patient with AIDS. J Am Acad Dermatol 2004;50:461-465
6. Christine M. Choi and Ethan A. Lerner. Leishmaniasis: Recognition and Management with a Focus on the Immunocompromised Patient. Am J Clin Dermatol 2002; 3 (2); 91-105
7. Kurban AK, Malak JA, Farah FS. Histopathology of cutaneous leishmaniasis. Arch Dermatol 1966; 93: 396-401
8. Barat C, Zhao C, Ouellette M, Tremblay MJ. HIV-1 replication is stimulated by sodium stibogluconate, the therapeutic mainstay in the treatment of leishmaniasis J Infect Dis. 2007 15;195(2):236-45.