

## **Abscess Of The Deep Cervical Fascial Space In Adults: A Report Of 3 Cases And Review Of Anatomy.**

*AUTHORS:* O. B. Da LILLY-TARIAH, L. O. ONOTAI

Dept Of Otorhinolaryngology University Of Port Harcourt Teaching Hospital Port Harcourt

### **ABSTRACT:**

*Deep cervical space abscess is a disease with the potential for grave consequences if not managed properly. Even though since the antibiotic era it has been on the decline, it still occurs. Better imaging techniques have made the management of this disease better such that it is possible to treat the abscesses conservatively reserving surgical drainage for cases that fail to respond to treatment. We present 3 cases of deep cervical space abscess that were surgically drained and wide spectrum antibiotic administered. In one of the patients, there was coexisting pulmonary tuberculosis.*

**Keywords:** deep cervical fascia abscess pulmonary tuberculosis

*Paper accepted for publication 16th October 2006*

### **INTRODUCTION**

The cervical fascia of the neck is a fibrous connective tissue that is loose and easily breached in some areas while in other areas it is tough and capsular. The fascia compartmentalizes the various muscles, vessels, nerves and glands. The resultant effect of this is that spaces are created within a fascial compartment and between 2 compartments<sup>1</sup>. Infection within a fascial space may be limited to that space in the early stages of the infection. With progression of the infection, other fascial spaces may become involved in the infective process.

The sources of infection of the deep cervical fascial spaces include pharyngeal trauma, pharyngitis, tonsillitis, odontogenic infections, lymphadenitis, direct contiguous spread and haematogenous spread. With widespread usage of antibiotics, odontogenic route is now the commonest source. In a significant number of patients however, the source is not known<sup>2</sup>.

Bacteria involved in the infective process are those of the normal flora of the mouth and pharynx. Before the antibiotic era, staphylococcus and streptococcus were the common isolates. These days, anaerobic bacteria are more commonly isolated than aerobic bacteria. Specimens from most patients however have multiple bacteria<sup>3</sup>.

Diagnosis of deep cervical fascial abscess from the clinical history may not be conclusive. Aspiration of pus may be helpful. Plain radiograph and ultrasonography may be useful in some cases. CT scan and MRI have proved invaluable tools not only in the diagnosis but also in the management<sup>4</sup>. These tools provide very good resolution and high accuracy in diagnosis. Whereas all abscesses were surgically drained previously, with efficacious antibiotic administration and close monitoring with CT scan and MRI, surgery may be reserved for those cases that do not resolve with conservative treatment.

Three cases of deep cervical space abscesses are reported with one of the patients having pulmonary tuberculosis.

### **CASE 1.**

E.L., is a 35 years old married female petty trader who presented at the emergency department of the University of Port Harcourt teaching hospital with complaints of spontaneous discharging sinus in the suprasternal notch and spontaneous discharge of pus from the right side of the neck of one week duration. Four weeks earlier, the patient had developed multiple swellings located at the angle of the right jaw; the right lower neck and midline of the lower neck. The patient also complained of fever, productive cough and vomiting of 4 months duration. There was no haemoptysis. The patient had been admitted in a clinic for unspecified diagnosis 4 months before this.

Physical examination revealed a swelling at the right parotid region that extended from the tragus to the angle of the mandible. It was limited posteriorly by the sternomastoid and anteriorly by the ramus of the mandible. There was a second swelling located in the posterior triangle at the posterior border of the sternal end of the sternomastoid muscle. Both swellings were tender, fluctuant and warm to touch. At the suprasternal notch, there was a sinus that was discharging copious pus. The throat showed areas of hyperemia and discharge of pus in the right pharyngeal wall. There was no swelling or bulge in the pharynx. The patient was ill looking, pale, febrile to touch and dehydrated. She was not dyspnoeic.

Correspondence: O. B. Da Lilly-tariah, E-mail: Dalillytariah@yahoo.ca

Aspiration of the swellings revealed pus. X-ray of soft tissue of neck did not show any significant abnormality. Chest x-ray (fig 1.) showed homogenous opacities with background cystic and thinly nodular changes in the lower right zone. There were patchy opacities coalescing in the mid zone. There was no involvement of the thoracic or vertebral bone. Acid-fast bacilli were identified in all the sputum of the three specimens. A diagnosis of pulmonary tuberculosis (Koch' disease) was made. The patient was HIV seronegative.

Staphylococcus aureus was isolated from the aspirate and was sensitive to ciprofloxacin. Anaerobic bacteria were not cultured because the media was not readily available. The packed cell volume was 21%. While the erythrocyte sedimentation rate was 39mm/hour. The white cell count was unremarkable. Urinalysis was normal as well as the blood electrolytes and urea.

Fig. I. X-ray of the chest showing changes due to pulmonary tuberculosis.

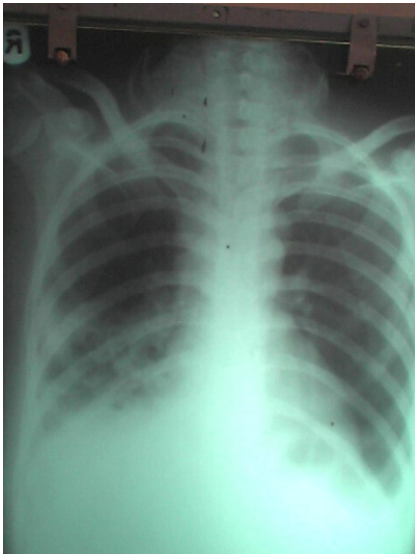
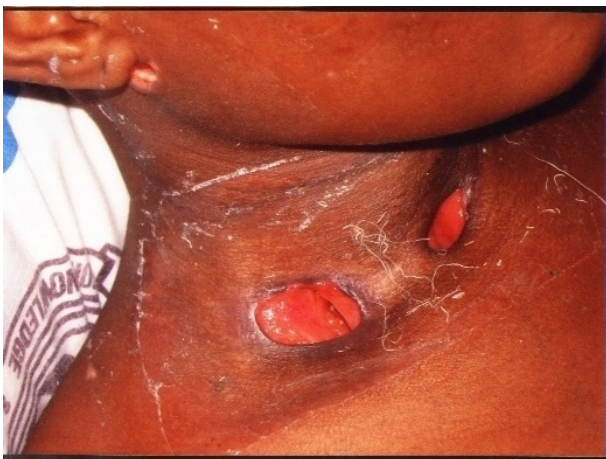

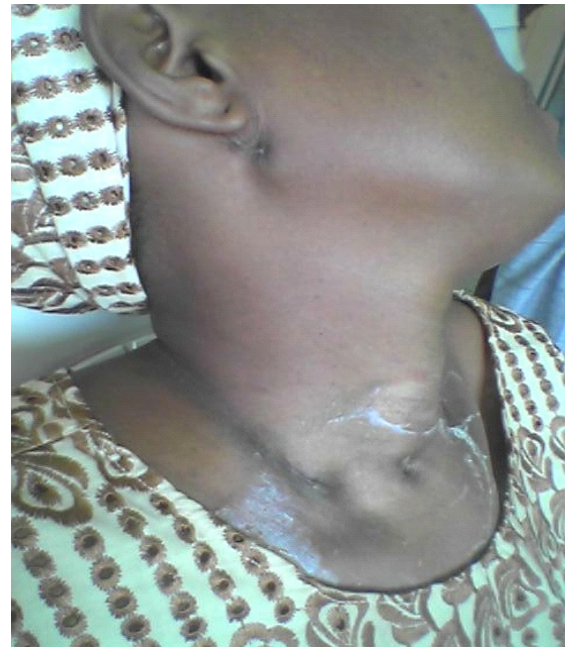Fig. II. Picture of Draining Abscess



A diagnosis of multiple cervical fascial space abscesses involving the retropharyngeal space, parapharyngeal space and the parotid space coexisting with pulmonary tuberculosis was made. She had incision and drainage of the abscesses with daily dressing of the resulting cavities (fig 2). The patient was transfused with 2 units of blood. She was placed on infusion of ciprofloxacin and metronidazole. Her anti-tuberculosis treatment included rifampicin, isoniazid, ethambutol, pyridoxine and pyrizinamide.

The discharge from the abscess sites stopped and wound healed (fig 3). Patient was discharged after 22 days to the medical out patient clinic for continued management of the pulmonary tuberculosis.

Fig III. Healed sinus formations.



### CASE 2.

E. O. is a 27 year old lady that presented at the ENT Out patient clinic of the University of Port Harcourt Teaching Hospital with progressive sore throat of 2 weeks duration that was localized to the left side. She had trismus. There was a swelling on the left side of the neck. She also complained of odynophagia, left sided headache, fever and weakness of the whole body. Two weeks before the current symptoms, patient had developed toothache involving the left lower third molar tooth.

Examination revealed a warm, diffused swelling around the angle of the left mandible that was tender to touch, soft and did not involve the skin or subcutaneous tissue. Oral examination showed a carious third molar tooth on

the left mandible. There was oedema and hyperemia of the retro molar trigone of the left side. There was no cervical lymph node enlargement. X-ray soft tissue of neck did not show any abnormality. A diagnosis of masticator space abscess was made.

The patient had canal root treatment with drainage of pus from around the carious tooth. She was placed on ceftriaxone parenterally, metronidazole and diclofenac orally for 10 days. The trismus resolved after 6 days and the swelling and pain after 8 days.

### **CASE 3.**

M.A. is a 42 years old male trader who presented at Ebenezer ENT Clinic in Port Harcourt with painful swelling of the right cheek of 8 days duration. There were associated complaints of fever, headache, neck pain, odynophagia and trismus.

Examination revealed a febrile and ill-looking patient. There was a fluctuant swelling located at the right side of the face extending from the zygomatic arch to the body of the mandible and from the ramus of the mandible to the anterior of the masseter muscle. There was a right lateral pharyngeal bulge with oedema of the soft palate.

X-ray soft tissue of neck showed soft tissue swelling of the right side. Aspiration revealed purulent, foul smelling material. Microscopy, culture and sensitivity test done isolated staphylococcus aureus which was sensitive to gentamicin, ceftazidime, ciprofloxacin and ofloxacin. Anaerobes were not tested for because of limitation of facilities for this.

A diagnosis of parapharyngeal abscess was made.

A T-shaped incision horizontal to the body of the mandible and vertical along the anterior border of the sternomastoid was made and drained. The wound was dressed daily till it healed in 15 days. Patient was treated with gentamicin, metronidazole and ampicillin/cloxacillin for 21 days.

### **DISCUSSION**

Anatomy of the deep cervical fascia

The cervical fascia is a fibrous connective tissue that varies from loose areolar tissue (visceral fascia) to dense fibrous tissue (salivary gland). The fascia envelopes muscles, nerves, vessels, glands, trachea, laryngopharynx and oesophagus thus forming tissue planes, spaces and potential spaces. The effect of this is that infection may be confined to a space, spread along a space or it may spread along a potential space between two compartments.

The cervical fascia is divided into a superficial layer and a deep layer. The deep layer is further divided into a superficial investing fascia, the middle (visceral) fascia and the deep fascia.

The superficial layer of cervical fascia ensheathes the platysma muscle and form a continuous sheath from the head and neck to the shoulder and the axilla.

The superficial layer of the deep cervical fascia (investing layer) wraps around 2 muscles, 2 glands and forms 2 spaces. This layer originates from the spinous process of the cervical vertebrae and moves round the neck to invest the trapezoid and sternomastoid muscles. Anteriorly, it is attached to the hyoid bone. Superiorly, it invests the parotid and submandibular salivary glands. The investing fascia covers the anterior belly of the digastric and the mylohyoid muscles to form the floor of the submandibular space. The investing fascia extends to the mandible and divides into an inner layer that covers the medial surface of the pterygoid to the base of the skull. The outer layer covers the masseter muscle and attaches into the zygomatic arch. The superficial investing fascia splits into an anterior and a posterior part just above the sternoclavicular junction to form the suprasternal space of Burns and the space of the posterior triangle.

The middle layer of the deep cervical fascia forms 2 divisions. These are the muscular division that wraps the infrahyoid strap muscles and the visceral division that wraps the pharynx, trachea, oesophagus and the thyroid gland. The muscular division of the fascia is attached superiorly to the hyoid bone and thyroid cartilage and inferiorly to the sternum and clavicle. The visceral fascia enters the upper mediastinum and goes down to the fibrous pericardium. Anterior-superiorly, it is attached to the hyoid and thyroid cartilage while posterior-superiorly, it covers the buccinator and the pharyngeal constrictor muscles to form the buccopharyngeal fascia as it attaches to the base of the skull.

The deep layer of the deep cervical fascia takes origin also from the spinous process of the cervical vertebra and the ligamentum nuchae. This fascia divides at the transverse process into anterior alar layer and a posterior prevertebral layer. The alar fascia is attached to the base of the skull and extends down to the second thoracic vertebra where it joins the visceral fascia. The prevertebral fascia lies anterior to the vertebral bodies and covers the vertebral muscles and traverses the length of the vertebral column.

The carotid sheath is formed from contribution of all three layers of the deep fascia. It runs from the base of skull to the chest.

### **Cervical fascial spaces**

The hyoid bone forms the landmark by which the cervical spaces are categorized. These are spaces that traverse the whole neck, those superior to the hyoid bone and those below the hyoid bone.

The spaces that traverse the whole neck are the superficial space, the retropharyngeal space, the danger space, the prevertebral space and the carotid sheath.

The superficial space is a potential space that lies between the superficial fascia and the superficial deep (investing) fascia. It contains the external jugular vein and lymph nodes.

The retropharyngeal space extends from the base of skull to the second thoracic vertebra where the visceral fascia and alar fascia join together. The anterior wall is formed by the buccopharyngeal fascia superiorly and the visceral fascia below. The alar fascia forms the posterior wall and the carotid sheath forms the lateral wall.

The danger space lies posterior to the retropharyngeal space and is situated between the alar fascia and the prevertebral fascia. This space runs from the base of the skull to the diaphragm. It contains loose areolar tissue and offers little resistance to spread of infection.

The prevertebral space lies posterior to the prevertebral fascia and anterior to the deep musculature, the vertebral bodies and anterior longitudinal ligaments. The prevertebral fascia attachment to the transverse processes forms the lateral boundary. This space traverses the length of the vertebral column.

The carotid sheath (visceral vascular space) is a potential space. It extends from the base of the skull to the mediastinum. It contains the carotid artery, the internal jugular and the vagus nerve.

The spaces superior to the hyoid bone are the submandibular space, parapharyngeal space, peritonsillar space, masticator space, temporal space and parotid space.

The mandible bound the submandibular space anteriorly and laterally. The hyoid bone forms the boundary posterior-inferiorly. The lingual mucosa is the superior boundary. The superficial layer of the deep investing fascia lies inferiorly. The mylohyoid muscle divides the submandibular space into a superior sublingual space and an inferior submental space. These 2 spaces communicate freely at the posterior aspect.

The parapharyngeal space is like an inverted cone. Superiorly lies the base of skull and inferiorly is the hyoid bone. The pterygomandibular raphe forms the anterior limit while posteriorly is the prevertebral fascia. The buccopharyngeal fascia forms the medial border. The superficial layer of the deep fascia passes over the mandible, medial pterygoid and parotid to form the lateral border. This space is in communication with the submandibular, parotid, retropharyngeal and masticator spaces. The parapharyngeal space contains the carotid sheath, IX, X and XII cranial nerves, stylomastoid and stylohyoid muscles and lymph nodes.

The peritonsillar space is bounded by the capsule medially in its free surface and laterally by the superior constrictor muscle. In its superior aspect is the anterior tonsillar pillar, which contains loose areolar tissue, and the posterior tonsillar pillar inferiorly.

The masticator space is located in the space between the superficial layer of the deep investing fascia as it surrounds the masseter muscle laterally and the pterygoid muscles medially. Within this space are the ramus of the mandible and the tendon of the temporalis muscle and there is free communication of this space with the temporal space.

The superficial layer of the deep cervical fascia limits the temporal space laterally as it attaches to the zygoma and temporal ridge and to the periosteum of the temporal bone medially.

The parotid space is formed by the superficial layer of the deep cervical fascia as it envelopes the gland. This envelope is however deficient on the supero-medial surface of the gland leading to a direct communication with the parapharyngeal space.

Below the hyoid bone, the anterior visceral space containing the thyroid gland, the trachea and the oesophagus is the only space. It is a potential space.

The space is formed from the middle layer of the deep cervical fascia. It runs from the thyroid cartilage to the anterior mediastinum at the level of the aortic arch. This space communicates with the retropharyngeal space at the level below the thyroid gland.

### **Clinical features**

The symptoms and signs that a patient presents with depends on the space affected, the route of spread of the infection, the infective organism and the health status of the patient. However because the fascial spaces are in communication with each other, the presenting features can change rapidly as the infection progresses and involves other fascial spaces. The effect of this is that the symptoms and signs become more complex as more spaces are involved<sup>2</sup>. The patient (Case 1) had multiple fascial space involvement as compared to the other patients that had only one space infection. Trauma, instrumentation, odontogenic infections and contiguous spread of infection are the usual source of fascial space infection in adults<sup>5</sup>. It is known that in some cases the cause may not be determined<sup>6</sup>. In 2 of the patients in this series, (Cases 2 and 3), the infection could be traced to odontogenic causes. In Case 1, the cause of the infection could not be determined. The lymph node is usually the focus by which fascial space infection takes place in infants and children. The isolation of acid-fast bacilli in the sputum

(Case 1) and the radiological changes suggestive of pulmonary tuberculosis though fortuitous is significant as a leading factor in compromising the patients immunity even in the absence of HIV/AIDS. There was no clinical or radiological evidence of tuberculous infection of the spine, Pott's disease that often involves the danger, retropharyngeal and prevertebral spaces.

### Microbiology

In two of the patients in this study, staphylococcus aureus was the isolate. Before the common use of antibiotics, Staphylococcus aureus was the commonest isolate<sup>7</sup>. In the majority of cases of deep space infection, the flora is often mixed. Common bacteria isolated include aerobic streptococcus, Klebsiella spp, Peptostreptococcus spp, Fusobacterium nucleatum, Bacteriodes melaninogenicus, Eikenella corrodens, Haemophilus influenzae and anaerobic streptococcus. Anaerobic bacteria were not isolated in any of our patients because they were not tested for due to limitation in facilities for isolation of such organisms in our hospitals.

The choice of antibiotics was informed by the need to cover for a mixed flora in these patients with agents that can produce optimal tissue penetration in a short time while awaiting the result of microscopy, culture and sensitivity.

### Therapy

The diagnosis of deep cervical space infection in these patients was made clinically. Plain x-rays, CT scan and MRI are useful radiological tools for diagnosis. However CT scan and MRI have also significantly improved and influenced the treatment options and outcome of this problem<sup>8</sup>. With these tools it is easier to distinguish between an abscess and cellulitis. The decision to drain an abscess or to manage conservatively with antibiotics can be determined by the progress of the abscess on serial CT scan and MRI monitoring. Abscesses can also be drained under CT-scan guidance. Thus only cases that fail to resolve with antibiotics are drained.

All the patients in our study were treated by surgical drainage through an external approach and broad-spectrum antibiotic cover. The patient with pulmonary tuberculosis was commenced on pyridoxine phosphate, isoniazid, ethambutol, rifampicin and pyrizinamide before referral to the medical out patient clinic.

### CONCLUSION

Though the widespread use of antibiotics has brought about a reduction in the incidence of deep cervical fascial space abscess, the challenges they pose still remain. Clinically, there must be a high index of suspicion so that treatment can be started early. Complications of poor treatment such as respiratory tract obstruction, mediastinitis, intra cranial extension, carotid artery and internal jugular vein erosion bear grave consequences. Surgical drainage of the abscess is still the standard treatment in our center as CT scan and MRI are not readily available and are still very expensive. In this report, 2 patients had microscopy, culture and sensitivity done but had the limitation of not being inclusive for anaerobic bacteria.

The choice of antibiotics should be broad spectrum and cover for both aerobic and anaerobic bacteria that are likely isolates in this type of infection.

The role of chronic debilitating disease in deep cervical fascial abscess is well known. Case 1, had a co-existing pulmonary tuberculosis and this may explain the severity and the involvement of multiple spaces in that case.

### REFERENCE

1. Singh T P, Sanju B, Kalsey G, Singla R K; Applied anatomy of fascial spaces in head and neck. J. Anat. Soc. India. 2000; 49: 78-88.
2. Hamza N S, Farrel J, Strauss M, Bonomo RA; Deep fascial space infection of the neck: a continuing challenge. South med J. 2003; 96: 928-932.
3. Bryan M D, Quinn F B; Neck space infections:1994. [http://www.utmb.edu/oto/Grand\\_Rounds\\_Earlier.dir/Neck\\_Infections\\_1993](http://www.utmb.edu/oto/Grand_Rounds_Earlier.dir/Neck_Infections_1993).
4. Hillman E J; Deep neck space infections: changing trends. <http://www.bcm.edu/oto/grand/10694.html>
5. Chow A W; Life-threatening infections of the head and neck. Clin Infect Dis 1992; 14: 991-1002.
6. Sethi D S, Stanley R E; Deep neck abscesses: Changing trends. J. Laryngol. Otol. 1994; 108: 138-143.
7. Rosen E J, Bailey B J; Anatomy of the cervical fascia. <http://www.utmb.edu/otoref/Grnds/Deep-Neck-Spaces-2002-04/Deep-neck-spaces-2002-04.htm>.
8. Weber A L, Siciliano A; CT and MR imaging evaluation of neck infections with clinical correlations. Radiol. Clin North Am 2003; 3: 941-968.