

Fibroadenoma Coexisting With Infiltrating Ductal Carcinoma - A Case Report

* M. Gogo-Abite FWACP (Lab Med), * D. Seleye-Fubara FMCPATH, FWACP (Lab. Med),
** R . S. Jamabo FRCS, FWACS

Department of * Anatomical Pathology and ** Surgery, University of Port Harcourt Teaching Hospital, Port Harcourt, Nigeria.

ABSTRACT

Background: Fibroadenomas are benign breast tumours that are commonly diagnosed in young women in their 20's and early 30's. Occurrence of malignancy in the breasts of these women is very rare.

Method and Result: We report a case of an infiltrating ductal carcinoma within an otherwise benign fibroadenoma in a 23-year-old woman. She presented with a lump, approximately 7cm in diameter, in her right breast. There were no palpable axillary and supra-clavicular lymph nodes. Excision biopsy was carried out and histopathological report showed it to be a fibroadenoma coexisting with infiltrating ductal carcinoma.

Conclusion: Fibroadenomas are commonly diagnosed in patients in their 20's when the risk of developing breast cancer is extremely rare. Despite this rarity all excised breast lumps should be subjected to histopathological evaluation in order to avoid a diagnostic pitfall.

KEYWORDS: Breast; Fibroadenoma; Infiltrating Ductal Carcinoma

Paper accepted for publication 7th February 2005

INTRODUCTION

Fibroadenomas are one of the most common benign tumours of the breast. They are commonly diagnosed in women in their 20's an age when breast cancer rarely occurs. In view of this, fibroadenomas have traditionally been thought to be unrelated to breast cancers. Several series have shown that when compared with women of similar age in the general population, women with fibroadenomas have two to three times the risk of breast cancer¹⁻³. This is especially true for women with complex fibroadenomas (ie fibroadenomas with associated cysts, sclerosing adenosis and

papillary apocrine changes) and strong family history of breast cancer. These women, despite having excised the fibroadenomas, stand a long-term risk of developing breast cancer⁴.

CASE REPORT

A 23-year-old woman presented with a painless lump in her right breast, which she noticed about one year earlier. The lump was said to be increasing in size and was not associated with a nipple discharge, nipple deviation or retraction. She had no family history of breast cancer. On clinical examination, it was a firm, well-circumscribed mobile mass, 7cm in diameter and was found in the upper outer quadrant of the breast. There were no palpable axillary or supraclavicular lymph nodes. A diagnosis of fibroadenoma was made and excision biopsy of the lump was done. The histopathology report read as follows:

Grossly, the specimen received was a fibrofatty tissue measuring 5x4x2cm. On section, there was a firm, white, bulging mass measuring 3x2x1cm, and sharply demarcated from the surrounding fibrofatty tissue.

Microscopic examination shows an intracanalicular fibroadenoma with extensive myxoid stroma (Fig 1). The ductular lining shows focal proliferation of malignant cells protruding into the ductular lumina characterized by nuclear pleomorphism and hyperchromatism. Focal areas show a micropapillary growth pattern (Figs 2 and 3).

Diagnosis: Fibroadenoma coexisting with infiltrating ductal carcinoma

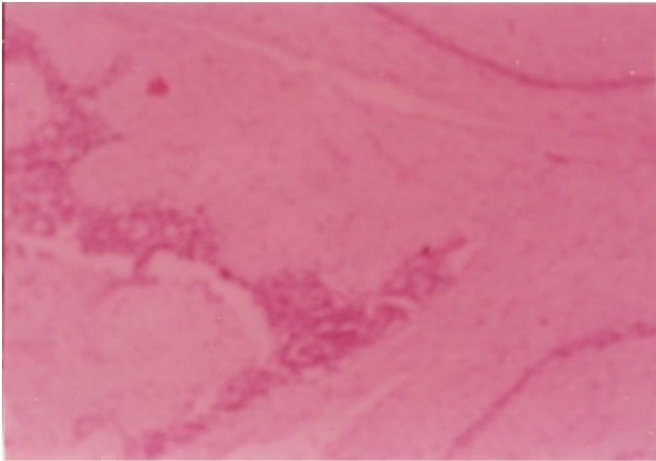


Fig 1. Photomicrograph showing an intracanalicular fibroadenoma with extensive myxoid stroma

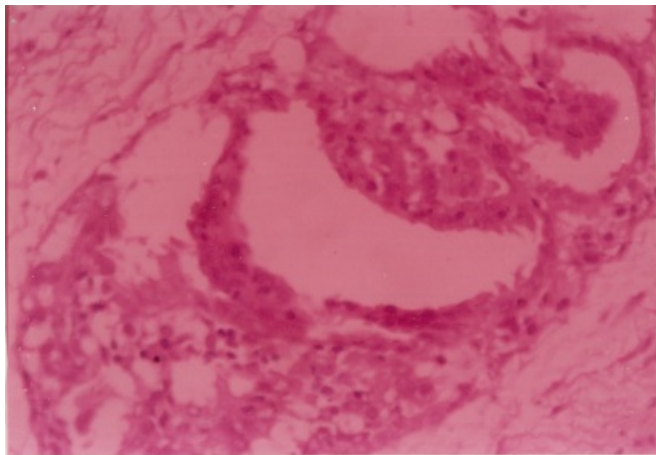


Fig. 2. Focal areas showing micropapillary pattern of growth

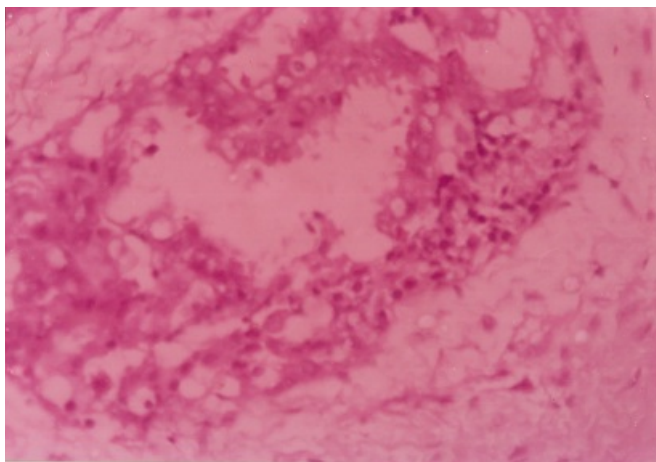


Fig 3. Another photomicrograph showing micropapillary growth pattern

DISCUSSION

Fibroadenomas are benign breast tumours composed of epithelial and stromal components⁵. As in our case, they are commonly diagnosed among women in their 20's, an age when breast cancer is extremely rare.

Carcinoma coexisting with a breast fibroadenoma is very rare, having a reported incidence of 0.1 – 0.3%⁶. Pre-operative diagnosis of these lesions is very difficult because their presenting features are similar to those of fibroadenoma. Mammography and ultrasound scan were not done in this patient, as they may not have revealed any abnormality⁷. The diagnosis usually is a histopathological surprise. In reported cases of carcinomas coexisting with fibroadenomas, two-thirds have lobular morphology and the rest are ductal or mixed ductal and lobular^{7,8}.

The biological behaviour of a carcinoma occurring in a fibroadenoma is no different from that of a breast carcinoma unrelated to a fibroadenoma⁹. Fibroadenomas display considerable morphological variability in those women whose tumours contained cysts, sclerosing adenosis, epithelial calcifications or papillary apocrine changes. They have increased risk of developing breast cancer^{4, 5}. Our case had similar features; in addition there were ductular infiltration by malignant cells disposed in micropapillary growth patterns. There is the evidence that in such patients there is an increased risk of developing breast cancer even 20years later⁴.

There are three forms of association between fibroadenoma and carcinoma¹⁰:

1. Carcinoma arising in the adjacent breast tissue engulfing and infiltrating a fibroadenoma.
2. Carcinoma in the crevices of a fibroadenoma as well as in the adjacent breast tissue.
3. Carcinoma restricted entirely, or at least dominantly, to a fibroadenoma.

Our case was of the third variety and there were no other palpable masses in both the ipsilateral and contralateral breasts.

A patient with a fibroadenoma coexisting

with a carcinoma should be offered either a simple mastectomy or a modified radical mastectomy with axillary clearance^{7,11}.

Following the surgery, the patient should be offered adjuvant chemotherapy with / without radiotherapy. Our case had only an excision and declined to have further treatment. Excision only as advocated by Ozzello *et al*⁶ with a follow-up by mammographic monitoring of the breast having 10-15% risk of developing invasive carcinoma in a fibroadenoma remains controversial. It is also advocated that a random biopsy of the contralateral breast, in addition to an ipsilateral simple mastectomy, be done in cases of lobular carcinoma¹². With a mastectomy the prognosis is good, mainly because the fibroadenoma leads to an early diagnosis.

CONCLUSION

Although fibroadenoma coexisting with infiltrating ductal carcinoma is rare, clinicians should ensure that all excised breast lumps are subjected to histopathological evaluation so that no diagnosis of breast cancer is ever missed.

REFERENCES

1. Hutchinson WB, Thomas DB, Hamlin WB, *et al*. Risk of breast cancer in women with benign breast disease. *J Natl Cancer Inst* 1980;65:13-20.
2. Moskowitz M, Gartside P, Wirman JA, McLaughlin C. Proliferative disorders of the breast as risk factors for breast cancer in a self selected screened population: pathologic markers. *Radiology* 1980;134:289-291.
3. Carter CL, Corle DK, Micozzi MS, Schtzkin A, Taylor PR. A prospective study of the development of breast cancer in 16,692 women with benign disease. *Am J Epidemiol* 1988;128:467-477.
4. Dupont WD, Page DL. Relative risk of breast cancer varies with time since diagnosis of atypical hyperplasia. *Hum Pathol* 1989;20:723-725.
5. Fechner RE. Fibroadenoma and related lesions. In: Page DL, Anderson TJ (ed). *Diagnostic histopathology of the breast*. Edinburgh, Scotland: Churchill Livingstone, 1988:72-85.
6. Ozzello L, Gump FE. The management of patients with carcinomas in fibroadenomatous tumors of the breast. *Surg Gynecol Obstet* 1985;160:99-104.
7. Pick PW, Lossifides IA. Occurrence of breast carcinoma within a fibroadenoma. *Arch Pathol Lab Med* 1984;108:590-594.
8. McDivitt RW, Stewart FW, Farrow JH. Breast carcinoma arising in solitary fibroadenoma. *Surg Gynecol Obstet* 1967;125:572-576.
9. Fondo EY, Rosen PP, Fracchia AA, Urban JA. The problem of carcinoma developing in a fibroadenoma. Recent experience at Memorial Hospital. *Cancer* 1979;43:563-567.
10. Azzopardil JG, Ahmed, Mills RR. Problems in Breast Pathology In: Bannington JC (Ed). *Major Problems in Pathology*. Edinburgh: WB Saunders Company Ltd, 1979;325-328.
11. Sarela AI, Madvanur AA, Soonawala ZF, *et al*. Carcinoma in a fibroadenoma. *J Postgrad Med* 1995;41(1):19-20.
12. Goldman RL, Friedman NB. Carcinoma of the breast arising in fibroadenoma, with emphasis on lobular carcinoma. *Cancer* 1969;23:544-550.