

The Acute Scrotum: Aetiology, Management And Early Outcome-Preliminary report

N. K. Dakum FMCS, FWACS, FICS, Dip. Urol (UK), V. M. Ramyil FMCS, FWACS, Cert. Urol (UK),
A. A. Sani MBBS, A.T. Kidmas FWACS, FRCS (Glas)

Urology Unit, Department of Surgery, Jos University Teaching Hospital, Jos, Nigeria

ABSTRACT

Background: Most patients with acute scrotal pain may require urgent exploration. We determined the aetiological factors, treatment and early complications in such patients.

Methods: This was a prospective study of consecutive patients presenting with the acute scrotum at Jos University Teaching Hospital, Nigeria from January 2001 to December 2002.

Results: Twenty-nine patients were studied with a mean age of 29.4 years (range 12 days to 80 years). Seventeen (58.6%) were 11 to 30 years old. The clinical diagnostic accuracy for testicular torsion was 75% because out of the 24 patients initially thought to have testicular torsion, 18(62.1%), four (14.8%) and two (6.9%) had testicular torsion, epididymoorchitis and torsion of appendix testis respectively at exploration. The diagnosis in other patients was intrascrotal abscess in two (6.9%), Fournier's gangrene in one (3.4%) and haematocoele in one (3.4%). Only four (13.9%) patients presented within the first 24 hours of illness (all explored within 6 hours) and 14 (48.3%) in one to five days. Thirteen (44.6%) patients had orchidopexy while seven (24.2%) had orchidectomy as a result of testicular torsion (five) and intrascrotal abscesses (two). Testicular exploration only, with antibiotics was the treatment for patients eventually found to have epididymoorchitis; with good response. Testicular salvage rate was 72% in patients with testicular torsion. Postoperative complications observed in three patients were wound infection (two) and wound dehiscence (two).

Conclusion: We conclude that testicular torsion is the most common cause of acute scrotum in our environment. Majority of our patients with acute scrotum present to hospital late. Health education of the public and attending physicians is required in order to reduce delay in presentation, improve diagnostic skills, testicular salvage rate and prognosis.

KEY WORDS: Scrotum; Acute; Aetiology; Management; Outcome.

Paper accepted for publication 20th June 2005.

INTRODUCTION

The acute scrotum is an 'acute painful swelling of the scrotum or its content'¹ or otherwise defined as 'acute unilateral pains in the scrotal region and its contents'². This condition has continued to be a challenge to surgeons and can present a diagnostic dilemma, even for the most experienced physician³. Thus, the differential diagnosis of acute scrotum in an emergency is difficult and may not be straightforward. An accurate diagnosis is, however, necessary to save the involved testis, prevent recurrent infectious disease in the opposite testis and prevent systemic manifestation of testicular disease⁴.

The more usual causes of the acute scrotum include torsion of the testis or its appendages, epididymoorchitis, trauma, tumours, hydrocoele, acute idiopathic scrotal oedema, incarcerated hernia and acute haematocoele. Prompt attention is required to unravel the cause in any particular patient and treat accordingly. Most of these causes when identified and treated carefully can greatly reduce patient discomfort, morbidity and even mortality. Although there are elaborate investigations that could be carried out to determine the diagnosis, prompt surgical exploration is the investigation of choice⁵.

This study was aimed at determining the causes of acute scrotum in our environment, types of treatment offered and the early outcomes of such treatment.

PATIENTS AND METHODS

All patients presenting to the Jos University Teaching Hospital with acute scrotal pain from January 2001 to December 2002 were prospectively enrolled into the study. Data entered into proforma required information on personal data, duration of illness, diagnosis (pre- and post-operative), treatment offered, findings at operation and post-operative complications, if any. The data obtained was subjected to simple statistical analysis.

RESULTS

A total of 29 patients with acute scrotum were seen during the study period, with a mean age of 29.4 years (Range 12 days to 80 years). Seventeen (58.6%) were in the 11 to 30 years age bracket

(Figure 1). The aetiological factors were testicular torsion in 18 (62.1%), epididymoorchitis in five (17.3%) patients; torsion of testicular appendages in two (6.9%) and intrascrotal abscess (no identifiable cause), in two(6.9%) patients. One patient (3.4%) each had haematocoele (following inguinal herniorrhaphy done elsewhere in a hypertensive) and Fournier's gangrene (Figure 2). Testicular torsion occurred on the right, left and bilaterally in 10, 7 and 1 patient(s) respectively.

Of the 24(88.9%) patients who were initially thought to have testicular torsion, 18 (62.1%), four (14.8%) and two (6.9%) were found at exploration to have testicular torsion, epididymoorchitis and torsion of appendix testis respectively, giving a clinical diagnostic accuracy for testicular torsion of 75%. Only four (13.9%) patients presented within the first 24 hours of illness and 14 (48.3%) in one to five days (Table I). All patients presenting within the first 24 hours and requiring exploration were explored in one to six hours. Orchidopexy was performed in 13 (44.9%) patients while seven (24.4%) had orchidectomy for testicular gangrene complicating testicular torsion (five patients) and intrascrotal abscess (two patients) (Table II). The testis on the normal side of a torsted testis was routinely fixed. Patients found to have epididymoorchitis preoperatively or on scrotal exploration were given antibiotics with good response. Other patients were treated according to the final diagnosis (Table II). Testicular salvage rate was 72% in patients with testicular torsion presenting early.

Two of the patients who had orchidopexy for testicular torsion had post-operative wound infection and dehiscence respectively while a patient with scrotal haematocoele complicating inguinal herniorrhaphy developed both wound infection and dehiscence.

Table I. Time interval between onset of illness and presentation in hospital in 29 patients with acute scrotum

Duration	Frequency (%)	Number requiring orchidectomy
≤ 24 hours	4(13.9)	0
1 - 5 days	14(48.3)	4
6 - 10 days	2(6.9)	1
11 - 15 days	3(10.3)	2
16 - 20 days	0(0)	0
> 20 days	6(20.6)	0
Total	29(100)	7

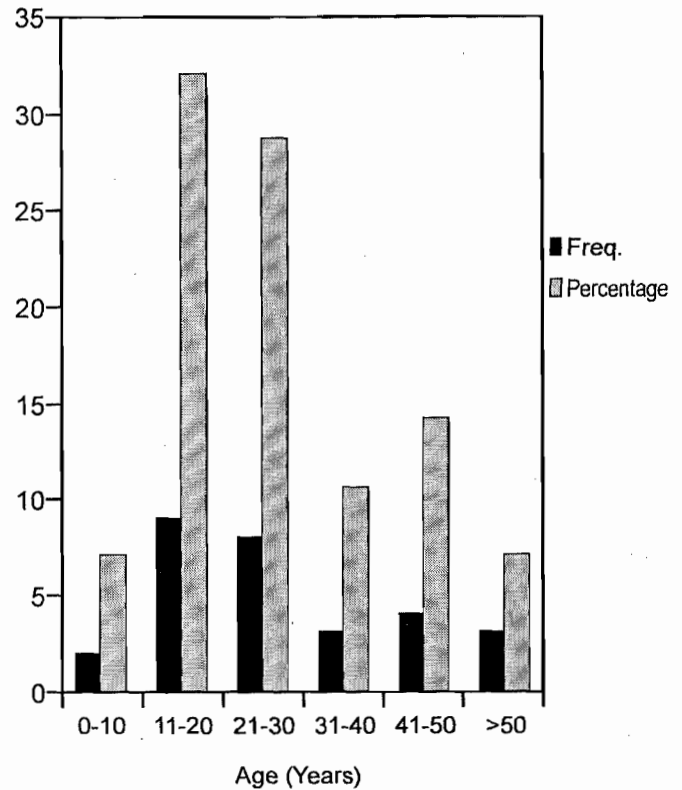


Figure 1. Age Distribution of Patients with Acute Scrotum

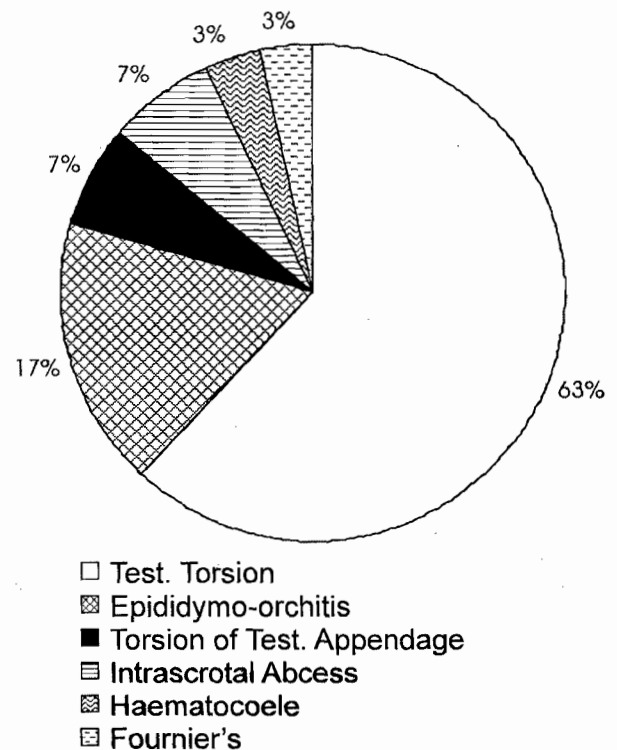


Figure 2. Aetiology of acute scrotum

Table II. Treatment offered to patients with acute scrotum

Diagnosis	Treatment	Frequency (%)
Testicular torsion	Orchidopexy	13 (44.8)
	Orchidectomy plus contralateral orchidopexy	5 (17.3)
Epididymoorchitis	exploration plus antibiotics	4 (13.9)
	antibiotics only	1 (3.4)
Torsion of appendix testis	Excision	2 (6.9)
Scrotal abscess	Unilateral orchidectomy plus drainage	2 (6.9)
Haematocoele	Evacuation	1 (3.4)
Fournier's gangrene	Debridement plus antibiotics	1 (3.4)
Total		29 (100.0)

DISCUSSION

The acute scrotum can be caused by a myriad of conditions. The major causes in our environment are testicular torsion, epididymoorchitis, torsion of appendix testis and intrascrotal abscess, and these four constituting 93.2% of cases in this study. The first three constitute 86.3% of cases of acute scrotum in our environment. A similar report from Virginia, USA attributed 85-90% of all cases of acute scrotum to these three⁶. It is interesting to note that 27.6% of all cases in this study are due to infection (epididymoorchitis, abscess, Fournier gangrene). This is in keeping with the trend in developing countries where infections are rife. This suggests that a third of cases of acute scrotum can be prevented by paying attention to measures that reduce infections e.g. aseptic catheter care, prompt antibiotic treatment and general basic hygiene. Other reported causes of the acute scrotum include torsion of spermatocele⁷, torsion of benign cyst arising from the tunica vaginalis⁸ and torsion of indirect hernial sac⁹. Torsion of the testis can also be induced by trauma as 5% and 10% of patients with testicular torsion and torsion of testicular

appendage respectively have a history of scrotal trauma¹⁰. Trauma could also cause a haematocoele which may result in an intrascrotal abscess.

Rarely, intra-abdominal lesions are known to also cause acute scrotum. Reported cases include acute appendicitis¹¹. Mbibu *et al* have reported a case of scrotal appendicitis in a child mimicking recurrent testicular torsion¹². Other causes of acute scrotum include retroperitoneal necrotizing fasciitis¹³, acute pancreatitis causing fat necrosis of the tunica vaginalis, spermatic cord and scrotum¹⁴ and neonatal adrenal haemorrhage¹⁵.

Cardiac related causes of acute scrotum include *staphylococcus aureus* endocarditis¹⁶ and migration of a ventriculoperitoneal shunt through a patent processus vaginalis¹⁷. Other reported aetiological factors in acute scrotum include insect bites to the external genitalia¹⁸, constipation in children¹⁹, familial Mediterranean fever causing inflammation of the tunica vaginalis²⁰ and Henoch-Schonlein purpura causing a vascular eruption on the scrotum²¹.

The clinical diagnostic accuracy of 75% for testicular torsion on clinical grounds was high. This underscores the high premium placed on a high index of suspicion. A misdiagnosis could have serious implications of testicular loss from necrosis or immunological damage to the contralateral testis²². Clinicians should therefore, acquaint themselves with clinical diagnosis and not over rely on diagnostic investigations as prompt surgical exploration without resort to detailed investigation would reduce morbidity and mortality. Dunne and O'Loughlin have shown that time is the enemy and no investigation substantially improves clinical diagnosis enough to warrant any delay in definitive surgery²³. Although aggressive early surgical exploration of the involved testis has been shown by Cass *et al*²⁴ to result in exploration of twice as many cases of epididymo-orchitis as torsion of the testis or its appendages, it however, resulted in a testicular salvage rate of 90% and long term salvage rate of 73% in patients with testicular torsion. An aggressive policy of immediate exploration is standard practice at our centre, especially if the diagnosis is certain of a condition requiring exploration or if any doubt exists as to the diagnosis. Such a policy however, should not be applied in a blanket fashion as this has been shown by Kass and Lundak²⁵ to result in an unacceptably large number of unnecessary explorations.

Pre-operative diagnostic investigations though not of the utmost importance do have their roles in

assessing patients with acute scrotum. This is especially so as signs and symptoms can overlap in various aetiologies of acute scrotum²⁶. Besides, ultrasonography for example, is able to differentiate between surgical emergencies e.g. testicular torsion and other causes of acute scrotum²⁶. Weber *et al* also have shown that colour doppler sonography can reliably rule out testicular torsion, therefore precluding routine scrotal exploration²⁷. On colour doppler sonography, presence of a normal or increased blood flow indicates that scrotal exploration is not required. However, if blood flow is decreased or no definitive diagnosis can be made, exploration is recommended²⁵. Technetium-99^m sodium pertechnetate scintigraphy is also sensitive and specific for testicular torsion when a decreased vascularity is seen on the symptomatic side²⁸. The disadvantage, however, is that it may not be available at all times, and may not be available at all in most developing countries. Sonography is also more widely available and cheaper in developing countries, with more physicians in such centres being familiar with its use and interpretation. Whichever method of investigation is available or preferred in any centre, it must be emphasized that imaging of any type is not warranted in patients with high suspicion of torsion as it delays surgical treatment needed to prevent permanent damage²⁹. Rivers *et al*²⁹ have found that interleukin-6 is significantly elevated in epididymitis as compared with testicular torsion. The sample size of 25 patients in their study was however small.

Only 13.9% of our patients presented within the first 24 hours of illness, none of whom required orchidectomy. All patients requiring orchidectomy, however, presented >24 hours after onset of symptoms. The delay in presentation resulted in a high early testicular loss rate of 24.4% (salvage rate of 75.6%). Ugwu *et al*³⁰ in Jos found a slightly lower salvage rate of 61% and it is interesting to note that 61% of patients in that study presented after 24 hours of onset of pain. Kuranga and Rahman in Ilorin, Nigeria found a salvage rate of 86.2%³¹. Longer follow up may also detect further testicular loss from atrophy as indicated by Ugwu *et al*³⁰ who found a 7% and 16% incidence of atrophy and subfertility in their patients. There could also be immunological damage to the contralateral testis, a fact stressed by Kuremu²².

Scott *et al*⁶² had a testicular salvage rate of 81% in 51 children with torsion of testicular appendage but this decreased to 50% due to testicular atrophy found in the late follow-up period. Cass *et al* with an aggressive policy of immediate exploration had a

higher early and late testicular salvage rate of 90% and 73% respectively²⁴.

The contralateral testis could also develop torsion synchronously or asynchronously due to bilaterality of predisposing congenital anomalies. Obi and Aghaji in eastern Nigeria found an incidence of such bilaterality to be 50%³³. We therefore routinely performed contralateral orchidopexy.

Careful attention must be paid to antisepsis and surgical techniques so as to minimize complications like wound infection and haematocoele as observed in this study. This is a preliminary report as our sample size could be bigger.

We conclude that testicular torsion is the most common cause of acute scrotum in our environment. Majority of our patients with acute scrotum present to hospital late. Health education of the public and attending physicians is required in order to reduce delay in presentation, improve diagnostic skills, testicular salvage rate and prognosis.

REFERENCES

1. Ben-Chaim J, Leibovitch I, Ramon J, Winberg D, Goldwasser B. Etiology of acute scrotum at surgical exploration in children, adolescents and adults. *Eur Urol* 1992; 21:45-7.
2. Hornak M, Bardos A Jr. Diagnostic and therapeutic problems of acute scrotum. *Czech Med* 1986; 9:29-33.
3. Schul MW, Keating MA. The acute pediatric scrotum. *J Emerg Med* 1993; 11:565-77.
4. Reisman EM, Colquitt LA 4th, Childers J, Preminger GM. Brucella Orchitis: A rare cause of testicular enlargement. *J Urol* 1990; 143:821-2.
5. Fisher R, Walker J. The acute paediatric scrotum. *Br J Hosp Med* 1994; 51:290-2.
6. Burgher SW. Acute scrotal pain. *Emerg Med Clin North Am* 1998; 16:781-809.
7. Jakimoto K, Okamoto K, Wakabayashi Y, Okada Y. Torsion of spermatoceles: A rare manifestation. *Urol Int* 2002; 69:164-5.
8. Yoshimura K, Itoh M, Kawase N, Taki Y, Hosaka N. Torsion of a benign cyst arising from the tunica vaginalis testis. *Int J Urol* 2001; 8:585-7.
9. Motta J, Bagli DJ, Savage JV, Khoury AE, McLorie G, Salle JP. Torsion of an indirect hernia sac: An unusual cause of acute scrotal swelling in children. *Urology* 1997; 50:432-5.
10. Elsharty S, Pranikoff K, Magoss IV, Sufirin G. Traumatic torsion of the testis. *J Urol* 1984; 132:1155-6.
11. Ng KH, Chung YF, Cwilde C, Chee C. An unusual presentation of acute scrotum after appendicitis. *Singapore Med J* 2002; 43:365-6.
12. Mbibu NH, Khalid L, Ameh EA. Scrotal appendicitis in a child mimicking recurrent testicular torsion. *African Journal of Urology* 2002; 8: 94-95.
13. Klutke CG, Miles BJ, Obeid F. Unusual presentation of sigmoid diverticulitis as an acute scrotum. *J Urol* 1988; 139:380-1.
14. Lin YL, Lin MT, Huang GT, *et al*. Acute pancreatitis masquerading as testicular torsion. *Am J Emerg Med* 1996; 14:654-5.

15. Avolio L, Fusillo M, Ferrari G, Chiara A, Bragheri R. Neonatal adrenal haemorrhage manifesting as acute scrotum: Timely diagnosis prevents unnecessary surgery. *Urology* 2002; 59:601.
16. Watanakunakorn C. *Staphylococcus aureus* endocarditis presenting as acute scrotal pain. *Postgrad Med J* 1987; 63:585-6.
17. Ward JF, Moquin RR, Maurer ST. Expanding the differential diagnosis of the acute scrotum: Ventriculoperitoneal shunt herniation. *Urology* 2001; 58:281.
18. Moran ME, Ehreth JT, Drach GW. Venomous bites to the external genitalia: An unusual cause of acute scrotum. *J Urol* 1992; 147:1085-6.
19. Fein JA, Donoghue AJ, Canning BA. Constipation as a cause of scrotal pain in children. *Am J Emerg Med* 2001; 19:290-2.
20. Majeed HA, Ghandour K, Shahin HM. The acute scrotum in Arab children with familial Mediterranean fever. *Pediatr Surg Int* 2000; 16:72-4.
21. Singer JI, Kisson N, Gloor J. Acute testicular pain: Henoch-Schonlein purpura versus testicular torsion. *Pediatr Emerg Care* 1992; 8:51-3.
22. Kuremu RT. Testicular torsion: case report. *East Afr Med J* 2004; 81:274-6.
23. Dunne PJ, O'Loughlin BS. Testicular torsion: Time is the enemy. *Aust NZ J Surg* 2000; 70:441-2.
24. Cass AS, Cass BP, Veeraraghavan K. Immediate exploration of the unilateral acute scrotum in young male subjects. *J Urol* 1980; 124:829-32.
25. Kass EJ, Lundak B. The acute scrotum. *Pediatr Clin North Am* 1997; 44:1251-66.
26. Blaivas M, Sierzenski P, Lambert M. Emergency evaluation of patients presenting with acute scrotum using bedside ultrasonography. *Acad Emerg Med* 2001; 8:90-3.
27. Weber DM, Rosslein R, Fliegel C. Color Doppler sonography in the diagnosis of acute scrotum in boys. *Eur J Pediatr Surg* 2000; 10:235-41.
28. Nakielny RA, Thomas WE, Jackson P, Jones M, Davies ER. Radionuclide evaluation of acute scrotal disease. *Clin Radiol* 1984; 35:125-9.
29. Rivers KK, Rivers EP, Stricker JH, Lewis J, Urrunaga J, Karriem V. The clinical utility of serologic markers in the evaluation of the acute scrotum. *Acad Emerg Med* 2000; 7:1069-72.
30. Ugwu BT, Dakum NK, Yiltok SJ, *et al.* Testicular torsion on the Jos plateau. *West Afr J Med* 2003; 22:120-3.
31. Kuranga SA, Rahman GA. Testicular torsion: Experience in the middle belt of Nigeria. *African Journal of Urology* 2002; 8: 78-82.
32. Scott JH 3rd, Harty JI, Howerton LW. The management of testicular torsion in the acute pediatric scrotum. *J Urol* 1983; 129: 558-60.
33. Obi AO, Aghaji AE. Torsion of the spermatic cord; Is bilateral orchidopexy really necessary? *Journal of College of Med* 2003; 8: 42-4.