

Radiographic Evaluation of Lymphadenopathy in Pulmonary Tuberculosis in Northeastern, Nigeria.

*A. Ahidjo MBBS, FMCR, FWACS, *M.K. Anka MBBS, **H. Yusuph MBBS, FMCP
Departments of *Radiology, **Medicine, University of Maiduguri Teaching Hospital, Maiduguri, Borno State, Nigeria.

ABSTRACT

Background: There is changing pattern of presentation of tuberculosis in the era of HIV. Lymphadenopathy is one of the most important manifestations of tuberculosis, hence the need for the evaluation of its radiologic patterns.

Methods: A multi-centre retrospective study of chest radiographs of 116 adult patients diagnosed bacteriologically (positive sputum smear) as pulmonary tuberculosis was conducted in the University of Maiduguri Teaching Hospital, Maiduguri, and Federal Medical Centre Nguru, in Borno and Yobe States, Nigeria, respectively between April 2003 and March 2004. Lymphadenopathy was assessed in all the radiographs.

Results: Of the one hundred and sixteen radiographs of patients analyzed, there were 83 (71.6%) males and 33 (28.4%) females with mean age of 37.99 ± 14.11 years.

A total of thirty eight patients (32.7%) presented with lymphadenopathy with the highest frequency in the left hilar region (12.9%). Bilateral hilar and paratracheal lymphadenopathy were the lowest with equal percentages (4.3%). Left, right and bilateral hilar enlargement were more common in males than females ($p < 0.000$) and more patients had left hilar (15) than right hilar (13) enlargement ($p = 0.030$). Only 3 (2.6%) out of all the patients presented with lymph node calcification.

CONCLUSION: In conclusion, there is a rise in the prevalence of lymphadenopathy among pulmonary tuberculosis patients when compared to a previous study done in the pre-HIV era in Nigeria.

KEYWORDS: Pulmonary tuberculosis; lymphadenopathy; Adults, Maiduguri.

Paper accepted for publication 8th August 2005.

INTRODUCTION

Pulmonary tuberculosis (TB) is an ancient disease, which was recognized centuries before the Christian era by physicians in many areas including Greece, the Middle East and India¹. It is caused mainly by *Mycobacterium tuberculosis*.

In economically developed countries, pulmonary TB is no longer the scourge it was at the turn of the century². However, it is still a problem ravaging many

people of the various countries of the world where public health facilities are poor³. Worldwide, an estimated 2 billion people carry the causative organism *M. tuberculosis*⁴. Around 80% of TB cases are in economically productive age group of 15-49 years with the highest risk group being in the male subjects^{4,5}.

The global pandemic of human immunodeficiency virus (HIV)/ acquired immune deficiency syndrome (AIDS) has further compounded the spread of TB⁶. Among Africans presenting with AIDS it is the most common opportunistic infection and may present as pulmonary or extrapulmonary disease⁷. Pulmonary TB in these patients may be typical or atypical^{7,8}.

Pulmonary TB produces a broad spectrum of radiographic abnormalities, yet diagnosis is often missed commonly due to failure to recognize hilar and mediastinal lymphadenopathy as a manifestation of the disease in adults⁹. Enlargement of hilar or mediastinal lymph nodes is very common in a primary tuberculous infection^{9,10}. Hilar adenopathy is usually unilateral but may be bilateral and any mediastinal adenopathy is contiguous to the affected hilum. However, mediastinal adenopathy may occur alone^{2,10}. Other radiographic features include consolidation, cavitation or pneumatocele formation, segmental or lobar atelectasis, pleural effusion, miliary disease, empyema, fibrosis, and a normal chest radiograph.

Plain films, Conventional Tomography, Computed Tomography (CT) and Magnetic Resonance Imaging (MRI) are used in the evaluation of pulmonary TB, the last two imaging modalities showing several advantages over the others in the early diagnosis and follow-up of this disease¹¹. However, cost and unavailability of CT and MRI, render these modalities unsuitable for assessment of this disease, particularly in developing countries.

This study assessed the radiographic appearance of lymphadenopathy in confirmed pulmonary TB patients using the cheaper and readily available plain chest radiographs.

MATERIALS AND METHODS

A multi-centre retrospective study of chest radiographs of 116 adult patients diagnosed bacteriologically (positive sputum smear) as pulmonary TB was conducted in the University of Maiduguri Teaching Hospital, Maiduguri, Borno State and Federal

Medical Centre Nguru, Yobe State between April 2003 and March 2004. Postero-anterior and lateral radiographs were obtained with film-screen at 90140 Kvp in all patients.

The age, sex, presence of lymphadenopathy, and the site, the side and calcification of lymphadenopathy were assessed in all the radiographs.

The data was analyzed using SPSS version 11 for windows (SPSS, Chicago). The data was presented in tables. $P < 0.05$ was considered significant.

RESULTS

One hundred and sixteen radiographs of patients were analyzed comprising of 83 (71.6%) males and 33 (28.4%) females with mean age of 37.99 ± 14.11 years and a range of 13 - 75 years.

Table I shows the distribution of lymphadenopathy with the highest frequency in the left hilar region (12.9%). Bilateral hilar and paratracheal lymphadenopathy were the least frequent with equal percentages (4.3%). A total of 38 patients (32.7%) presented with lymphadenopathy.

Table II reveals that left, right and bilateral hilar enlargement were more common in males than females ($p < 0.000$) and more patients had left hilar (15) than right hilar (13) enlargement ($p = 0.030$).

Only 3 (2.6%) out of the 116 patients presented with calcification.

Table I. Frequency distribution of lymphadenopathy according to the region involved in the patients studied.

| Region involved | Frequency | Percent (%) |
|-----------------|-----------|-------------|
| Right Hilar | 13.0 | 11.2 |
| Left Hilar | 15.0 | 12.9 |
| Bilateral Hilar | 5.0 | 4.3 |
| Paratracheal | 5.0 | 4.3 |
| Total | 38.0 | 32.7 |

Table II. Sex distribution of lymphadenopath according to the region involved in the 116 patients studied.

| Region Involved | Females | Males | Total |
|-----------------|---------|-------|-------|
| Right Hilar | 5 | 8 | 13 |
| Left Hilar | 6 | 9 | 15 |
| Bilateral Hilar | 2 | 3 | 5 |
| Paratracheal | 3 | 2 | 5 |
| Total | 16 | 22 | 38 |

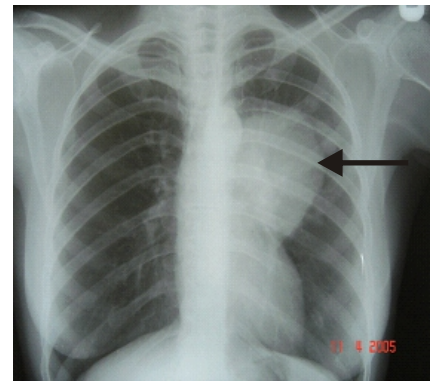


Fig.1 Left hilar adenopathy (arrow) in a patient with pulmonary tuberculosis.

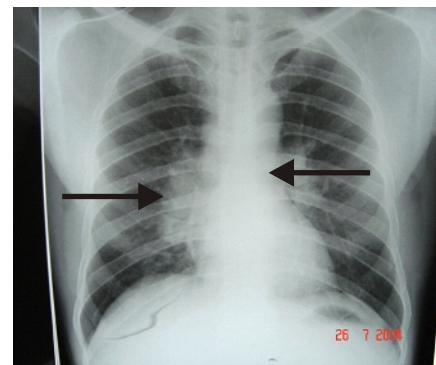


Fig.2 Bilateral hilar adenopathy (arrows) in a patient with pulmonary tuberculosis.

DISCUSSION

Postprimary pulmonary TB occurs predominantly in adulthood. The lungs may be normal, but enlargement of the mediastinal lymph nodes may be the only presenting abnormality in TB discovered on a chest radiograph. The differential diagnosis of enlarged mediastinal and hilar lymph nodes is largely dependent on the local pattern of disease. In the tropics TB usually will be the most likely aetiology. Sarcoidosis is not common in the tropics and there is enlargement of mediastinal and paratracheal nodes in particular, as well as bilateral symmetrical hilar node enlargement. Lymphoma and Kaposi sarcoma may be radiographically indistinguishable from TB. In adults, malignant disease is often the initial diagnosis when mediastinal lymph nodes are enlarged.

A total of thirty eight patients (32.7%) presented with lymphadenopathy in this study.

Kolawole *et al* in Ibadan, Nigeria, found 24 of the 216 pulmonary TB cases (11.1%) he studied presented with lymphadenopathy³. Kawooya *et al* in Uganda found 43.3% of the patients they studied with intrathoracic adenopathy¹². In India, hilar prominence was reported in 4.47% of pulmonary TB patients⁴ and in USA, Woodring, *et al*¹³ and Brenda *et al*¹⁴ reported frequencies of 35% and 45.8% for both hilar and mediastinal lymphadenopathy.

It is also obvious that our value is higher than the same study in Nigeria. These may be explained by the fact that the former study was conducted in the pre-HIV era. In West Africa over 80% of patients with combined TB and HIV have mediastinal lymphadenopathy¹⁵. It is also obvious that the finding in our study is similar to those of Uganda¹² and USA^{13, 14}. However, our value is higher than that reported from India⁴ and the reason for this is unclear.

Lymphadenopathy occurred more frequently in male patients (22) than females (16), this finding may be explained by higher number of TB cases among males in this study. Previous workers in Nigeria and other parts of the world also reported male preponderance of TB¹⁶⁻²⁰. Unilateral hilar adenopathy may be due to TB in 80% cases, other causes include bronchogenic carcinoma, metastases, lymphoma, infectious mononucleosis, rug reaction, histoplasmosis, coccidioidomycosis, blastomycosis, atypical measles, sarcoidosis (1-3%), and bilateral lung abscess. There was more left hilar than right hilar adenopathy in this study, this is similar to the finding of a previous study in our environment³ but a different observation was made among the Caucasians (80% of hilar adenopathy are on right side)²¹.

Bilateral hilar adenopathy may also be caused by sarcoidosis (70 - 90%), lymphoma (50% in Hodgkin disease), other causes include TB, metastases, leukaemia, primary bronchogenic carcinoma, plasmacytoma, silicosis, histiocytosis X, idiopathic pulmonary haemosiderosis, chronic berylliosis, rubella, ECHO virus, varicella, mononucleosis, histoplasmosis, and lymphoma. It occurred in 4.3% of our patients and is similar to the finding of Kolawole *et al* (11 out of 216 patients (5.1%))³. Paratracheal lymphadenopathy was seen in 4.3% of our patients, the percentage is similar to a previous local study³, but higher in Caucasian children (40%)²¹.

If lymphadenopathy is present, this may shrink and calcify. The combination of a peripheral calcification and hilar node calcification (Ranke complex) is a typical finding indicating prior TB and occurs in about half of people with previous primary TB²². Only 2.6% of the patients in this study presented with calcification. Calcified lymph nodes were seen in as high as 36% of patients in other studies³.

In conclusion, there is a rise in the prevalence of lymphadenopathy among pulmonary TB patients when compared with a previous study done in the pre-HIV era in Nigeria.

REFERENCES

1. Nye FJ, Hendrickse RG, Mathews TS. Infectious diseases. In: Hendrickse RG, Barr DGD, Mathews TS (Eds.) Paediatrics in the Tropics. Oxford: Blackwell Scientific Publications, 1991; 570-694.
2. Peter A, Alan GW and Paul D. Infections of Lungs pleura. In: Peter A, Alan GW, Paul D (Eds.) Imaging of diseases of the chest. Chicago, USA: Year Book Medical Publishers, 1990; 152-257.
3. Kolawole TM, Onadeko EO, Sofowora EO, Esan GF. Radiological patterns of pulmonary tuberculosis in Nigeria. Trop Geogr Med 1975; 27: 339-350.
4. Atul Shah, PMehrotra P, Dhar HI. Assessment of pulmonary tuberculosis in patients. Bombay Hosp J 2004; 46(2): 1-7.
5. Aktogu S, Yorganancioglu A, Cirak K, Kose T, Dereli SM. Clinical spectrum of Pulmonary tuberculosis and pleural tuberculosis: a report of 5,400 cases. Eur Resp J 1996; 9 (10): 2031-2035.
6. Dosunmu EA. The role of Mantoux Test as a screening tool for pulmonary tuberculosis in Nigeria. Nigerian Medical Practitioner 2003; 43: 74-76.
7. Williams IG, Weller I. Acquired Immunodeficiency Syndrome. In: Michael WA (Ed.). ABC of Sexually Transmitted Diseases. 4th Edition. London: BMJ Publishing Group, 1999; 33-41.
8. Adefuye BO, Adefuye PO, Ogun SA. Current trends in the Diagnosis and Management of Multi-Drug resistant tuberculosis. Nigerian Medical Practitioner 2003; 43: 77-81.
9. Woodring JH, Vandiner HM, Fried AM, Dillon ML, Williams LD, Melvin IG. Update: the radiographic features of Pulmonary tuberculosis. Am J Roentgenol 1986; 146(3): 497-506.
10. Ronald LE. Mycobacterial Diseases. In: Ronald LE (Ed.) Diagnostic Imaging in Internal Medicine. Baltimore: McGraw-Hill, 1985; 155-176.
11. Buxi T, Sud S, Vohra R. CT and MRI in the diagnosis of tuberculosis. Indian J Pediatr 2002; 69(11): 965-972.
12. Kawooya VK, Kawooya M, Okwera A. Radiographic appearance of pulmonary tuberculosis in HIV-1 seropositive and seronegative adult patients. East Afr Med J 2000; 77(6): 303-307.
13. Woodring JH, Vandiviere HM, Fried AM. Update: the radiographic features of pulmonary tuberculosis. AJR 1986; 146(3): 497-506.
14. Brenda EJ, Robert RYU, Zhenhua Yany, *et al*. Chest Radiographic Findings in Patients with Tuberculosis with Recent or Remote Infection. Am J Respir Crit Care Med 1997; 156(4): 1270-1273.
15. Palmer PES. Tuberculosis of the respiratory tract. In: Palmer PES (Ed). The Imaging of Tuberculosis. Berlin: Springer, 2002: 5-30.
16. Idoko JA, Anteyi EA, Idoko LO, *et al*. HIV and associated TB in Jos, Nigeria. Nigerian Medical Practitioner 1994; 28: 24-50.

17. Habib AG, Keshinro IB, Gebi UI, *et al.* Clinical presentation of HIV infection in Nigeria and its relationship to CD4 + T - cell counts. *Nigerian Medical Practitioner*. 1998; 35: 3-8.
18. Wokoma FS. HIV status of adult Nigerian patients suffering from pulmonary tuberculosis. *Nigerian Medical Practitioner* 1997; 34:22-24.
19. Styblo K. Overview and epidemiological assessment of the current global tuberculosis situation with an emphasis on control in developing countries. *Rev infect Dis* 1989; 11 (suppl 2): 339-346.
20. Kayembe KP, Nelson AM, Colebunders RL. Opportunistic infections and diseases. In: Max E, Mboup S, Kanki PJ. (Eds). *AIDS in Africa*. New York: Raven press, 1994; 373-391.
21. Dähnert W. Chest. In: Dähnert W (Ed.) *Dähnerts Electronic Radiology Review (CD-ROM)*. Baltimore: Williams and Wilkins, 1996.
22. Onorato IM, Rizdon R. The epidemiology, transmission and prevention of TB in the United States. In: Fishman A (Ed.) *Pulmonary Diseases and Disorder*. New York: McGraw-Hill, 1997; 24312440.