

Case Series: Uterine Rupture with a Life Baby after Two Previous Caesarean Sections: An Incidental Finding at Elective Caesarean Sections at Term

Obiora Asiegbu^{1,2}, Darlington-Peter Chibuzor Ugoji^{1,3}, Uzoma Vivian Asiegbu⁴, Bobbie C. Iwe¹, Paschal Chijioke Okoye^{1,3}, Kelvin Emeka Ortuanya⁵, Chidebe Christian Anikwe⁶

Departments of ¹Obstetrics and Gynaecology and ⁴Paediatrics, Alex Ekwueme Federal University Teaching Hospital, ²Department of Obstetrics and Gynaecology, National Obstetrics Fistula Centre, Abakaliki, ³Department of Obstetrics and Gynaecology, David Umahi Federal University Teaching Hospital, Uburu, Ebonyi State, ⁵Department of Obstetrics and Gynaecology, Enugu State University Teaching Hospital, Enugu, Enugu State, ⁶Department of Obstetrics and Gynaecology, Nnamdi Azikiwe University Teaching Hospital, Nnewi, Anambra State, Nigeria

Abstract

We present three cases of the absence of lower uterine segment (LUS) muscles with a life baby covered by the fetal membrane after two previous caesarean sections (CS) at elective CSs at term. The first case was a 30-year-old booked multipara with bad obstetrics history and two previous CS at a secondary facility on account of unexplained three serial stillbirths at term. There were no histories of maternal obesity, hypertension, or diabetes mellitus. She then had an elective CS at 37 weeks on account of two previous CS. Intraoperatively, it was noted that the LUS was covered by the fetal membranes with visceral peritoneum and no muscle layer. The second case was a 33-year-old booked G4P2 + 1A2 with two previous CSs on account of fetal distress and breech presentation with one previous scar at term, respectively. Pregnancy was uneventful till the presentation. At presentation, there was no history or examination finding suggestive of uterine rupture. She had an elective CS at 39 weeks on account of two previous CS. Intraoperatively, a thin membrane at the LUS with no muscular tissue exposing the fetal membranes was seen, with good fetomaternal outcomes. The third case was a 30-year-old booked G3P2 + 0A2 with two previous elective CSs on account of primigravida with breech presentation and placenta praevia, respectively. The course of the pregnancy was uneventful. At presentation, there was no clinical sign or symptom suggestive of uterine rupture. She had an elective CS at 37 weeks on account of two previous CS. Intraoperatively, a thin membrane at the LUS with visceral peritoneum and no muscular tissue was seen. The pregnancy outcome was favorable. Silent scar rupture as seen in our case series is one of the common complications of previous CS. Early detection with the introduction of imaging techniques, although not done for our cases and prompt intervention reduces morbidity and mortality.

Keywords: Caesarean, dehiscence, pregnancy, reports, rupture, scar

INTRODUCTION

Caesarean section (CS) was introduced in clinical practice as a lifesaving situation both for the mother and the fetus.^[1,2] It is an operative technique by which a fetus is delivered through an abdominal and uterine incision after 28 weeks of gestation.^[3,4] It is classified traditional as either elective or emergency.^[4] More than 50% of the CSs take place below 39 weeks.^[5] The indications can either be maternal, fetal, or fetomaternal. However, the most common indication for elective CS is two previous CSs.^[4]

A ruptured uterus is an obstetric catastrophe with public health concerns carrying an increased risk of maternal and perinatal

morbidity and mortality.^[6-10] It is defined as a breach in the integrity of the myometrial wall.^[8,11] It can be a complete rupture; where there is a full-thickness separation of the uterine wall with the expulsion of the fetus and/or placenta into the

Address for correspondence: Dr. Darlington-Peter Chibuzor Ugoji, Department of Obstetrics and Gynaecology, David Umahi Federal University Teaching Hospital, Uburu, Ebonyi State, Nigeria. E-mail: darlingtonpeter2012@gmail.com

This is an open access journal, and articles are distributed under the terms of the Creative Commons Attribution-NonCommercial-ShareAlike 4.0 License, which allows others to remix, tweak, and build upon the work non-commercially, as long as appropriate credit is given and the new creations are licensed under the identical terms.

For reprints contact: WKHLRPMedknow_reprints@wolterskluwer.com

How to cite this article: Asiegbu O, Ugoji DPC, Asiegbu UV, Iwe BC, Okoye PC, Ortuanya KE, *et al.* Case series: Uterine rupture with a life baby after two previous caesarean sections: An incidental finding at elective caesarean sections at term. *Niger J Med* 2023;32:325-9.

Submitted: 09-Jun-2023

Revised: 27-Jun-2023

Accepted: 06-Jul-2023

Published: 22-Sep-2023

Access this article online

Quick Response Code:



Website:
<http://journals.lww.com/NJOM>

DOI:
10.4103/NJM.NJM_65_23

abdominal cavity or incomplete rupture/dehiscence; where the overlying serosa is spared.^[11] A study done at Ebonyi State South East Nigeria showed the highest incidence was found in the para 2–4 group.^[12] In developed countries, the majority of cases occur in women with previous CS, while in developing countries, it usually follows prolonged obstructed labour, previous uterine scar, high parity, advanced maternal age, and delay in decision-making during labour.^[6–11]

One of the most important complications of caesarean deliveries (CD) is CS scar dehiscence (CSSD).^[13,14] The reported incidence of the CSSD ranges from 0.2% to 4.3%^[15,16] and previous CSSD is a well-known risk factor for uterine rupture.^[14] Therefore, the risk factors of caesarean scar rupture should be considered in women undergoing subsequent pregnancies as they may need extra care.^[17] Ultrasonography and magnetic resonance imaging (MRI) have been used in studies to assess the risks of scar rupture during subsequent pregnancies.^[16,18–22] It has been noted that the risk of uterine rupture in the presence of a defective scar is related to the degree of thinning of the lower uterine segment (LUS) as measured by ultrasound.^[16,18–22] Hoffmann *et al.*^[23] noted that variability in anatomy, thickness, and morphology seem to limit ultrasound prenatal LUS imaging diagnostics, hence advances in the use of MRI for better prognostication. A systemic review observed that previous CS was associated with adverse maternal outcomes for the subsequent pregnancies. Therefore, CS rates need to be monitored given the prospective risks which may occur for maternal and child health in subsequent births.^[24]

Bashiri *et al.*^[25] noted that the number of previous CD was an independent risk factor for uterine scar dehiscence. Ramadan *et al.*^[26] showed that uterine scar dehiscence is common among women undergoing elective repeat caesarean delivery, and the increased risk was associated with preterm delivery, tertiary caesarean delivery, or higher and short interdelivery interval of ≤ 24 months. Studies compared the thickness of LUS and myometrium with sonography. They noted that sonographic evaluation of LUS scar and myometrial thickness both with transabdominal scan and transvaginal scan is a safe, reliable, and noninvasive method for predicting the risk of scar dehiscence/rupture.^[16,18–21] Hatstat^[18] found out that the dehiscence of a caesarean scar is rarely diagnosed early in pregnancy but is a complication that may lead to uterine rupture if not monitored closely or treated with early caesarean delivery. It is from these notes that we decided to review these cases.

CASES SERIES

Case 1

Mrs. U. M, a 30-year-old booked G6P5 + 0A2 businesswoman with National Certificate in Education. Her last menstrual period (LMP) was March 18, 2022, with expected date of delivery (EDD) of December 25, 2022. She was admitted on November 30, 2022, at a gestational age (GA) of 36 weeks and

five days for an elective CS at 37 weeks on account of two previous CSs. There was no history of abdominal discomfort, lower abdominal pain, weakness, dizziness, or bleeding per vaginam. There was no history of trauma to the abdomen or feeling of sharp pain in the abdomen during pregnancy. She felt fetal movement. Pregnancy was spontaneously conceived and was uneventful. She booked antenatal care at the National Obstetric Fistula Centre, Abakaliki, Ebonyi State, Nigeria at a GA of 25 weeks with no complaint at booking. She made three antenatal visits. She was blood group 0 rhesus D positive and genotype AA. Her serology screenings were negative. At booking, her weight was 75 kg and her blood pressure was 110/70 mmHg. In 2017, 2018, and 2019, she had serial term spontaneous vaginal delivery of fresh stillbirths. Their weights were not recalled. Screening for gestational diabetes was normal. For this, she had CSs in 2020 and 2021 at 38 weeks each with delivery of live female neonates that weighed 3.5 kg and 4.5 kg, respectively. She attained menarche at 14 years with a regular 28-day cycle. She was not a known diabetic and hypertensive with no family history of such. There was no history of blood transfusion. She takes alcohol sparingly but not during pregnancies and does not take tobacco in any form. Examination findings were unremarkable. Preoperatively, her packed cell volume was 32%, retroviral screening was negative, and 2 units of blood were grouped and cross-matched. At surgery, the abdominal scar was excised and the incision developed into the peritoneal cavity while making sure that intra-abdominal structures were not injured. Intraoperative findings showed: Pfannenstiel scar that heal with primary intention, LUS covered by fetal membrane with visceral peritoneum, and no muscle layer [Figure 1]. There were healthy-looking tubes and ovaries, with a male neonate delivered cephalic and weighed 2.6 kg and Apgar score of 91 and 105. The placenta was delivered manually. The estimated blood loss was 350 mL. She did well postoperatively and was discharged after four days following postpartum packed cell volume of 30%. Her postnatal clinic was unremarkable and she received an intrauterine contraceptive device with subsequent discharge from the clinic.

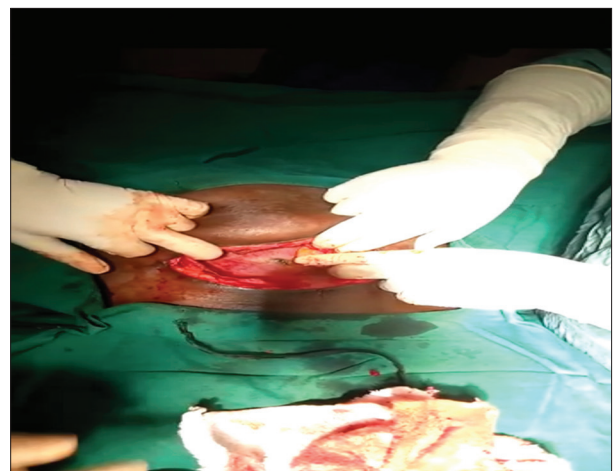


Figure 1: The membrane visible and the muscles separated in case 1

Case 2

Mrs. E. U, a 33-year-old booked G4P2 + 1A2 civil servant with Bachelor of Science. Her LMP was April 21, 2022, with EDD of January 28, 2023. She was admitted on December 27, 2022, at a GA of 38 weeks and Six days for an elective CS at 39 weeks on account of two previous CSs. Pregnancy has been uneventful till the presentation for the scheduled surgery. At presentation, there was no history or examination finding suggestive of uterine rupture. She booked antenatal care at Alex Ekwueme Federal University Teaching Hospital Abakaliki, Ebonyi State, Nigeria at a GA of 18 weeks with no complaint at booking. She made six antenatal visits. She was blood group 0 rhesus D positive and genotype AA. Her serology screenings were negative. At booking, her weight was 83 kg and her blood pressure was 90/60 mmHg. In 2019, she had a spontaneous complete miscarriage at 8-week GA. There was no postabortal complication. She had CSs in 2018 on account of fetal distress and in 2020 on account of breech with one previous scar at term. The outcome was a live male that weighed 4.5 kg and a live female neonate that weighed 3.5 kg, respectively. She attained menarche at 12 years with a regular 30-day cycle. She was not a known diabetic or hypertensive with no family history of such. There was no history of blood transfusion. She does not take alcohol or tobacco in any form. Examination findings were unremarkable. Preoperatively, her packed cell volume was 30%, retroviral and hepatitis B screenings were negative and 2 units of blood were grouped and cross-matched. At surgery, the abdominal scar was excised and developed into the peritoneal cavity without injured to intra-abdominal organs. Intraoperative findings showed: Pfannenstiel scar that healed by primary intention, thick adhesion bands between the upper segment of the uterus and anterior abdominal wall, a thin membrane at the LUS with no muscular tissue exposing the fetal membranes [Figure 2]. There were healthy-looking tubes and ovaries, with a live female neonate delivered cephalic, that weighed 3.45 kg. The Apgar score was 91 and 105. The posterior fundal placenta was delivered by controlled cord traction. The estimated blood loss was 500 mL. She did well postoperatively and was discharged after three days following postoperative packed cell volume of 28%. Her postnatal clinic was unremarkable and she was subsequently discharged from the clinic.

Case 3

Mrs. N. C, a 30-year-old booked G3P2 + 0A2 businesswoman with first school leaving certificate (FSLC). Her LMP was March 18, 2022, with EDD of December 25, 2022. She was admitted on November 30, 2022, at a GA of 36 weeks and five days for an elective CS at 37 weeks on account of two previous CSs. There was no history of abdominal discomfort, lower abdominal pain, weakness, dizziness, or bleeding per vaginam. There was no history of trauma to the abdomen or feeling of sharp pain in the abdomen during the pregnancy. She felt fetal movement. Pregnancy was spontaneously conceived and has been uneventful till the presentation for the scheduled surgery.

She booked antenatal care at Alex Ekwueme Federal University Teaching Hospital Abakaliki, Ebonyi State, Nigeria at a GA of 25 weeks with no complaint at booking. She made three

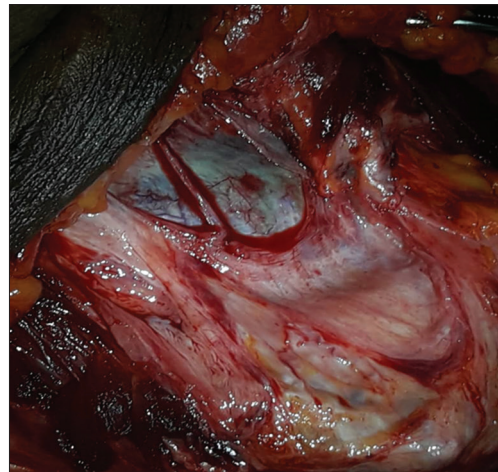


Figure 2: The membrane visible and the muscles well separated in case 2

antenatal visits. She was blood group 0 rhesus D positive and genotype AA. Her serology screenings were negative. At booking, her weight was 75 kg and her blood pressure was 110/70 mmHg. In 2018 and 2022, she had elective CSs on account of breech in a primigravidae and placenta praevia, respectively. Both were male neonates and weighed 3.5 kg and 3.2 kg, respectively. She attained menarche at 14 years with a regular 28-day cycle. She was not a known diabetic or hypertensive and with no family history of such. There was no history of blood transfusion. She does not take alcohol or tobacco in any form. Examination findings were unremarkable. Before the surgery, her packed cell volume was 34%, hepatitis B and retroviral screenings were negative and 2 units of blood were cross-matched. After a sterile procedure, the old scar was excised and the incision developed into the peritoneal cavity while making sure that intra-abdominal structures were not injured. Intraoperative findings showed: Pfannenstiel scar that healed by primary intention, LUS covered by fetal membranes, and visceral peritoneum without any muscular layer [Figure 3]. There were healthy-looking tubes and ovaries, with a live female neonate delivered cephalic and weighed 2.6 kg. The Apgar score was 91 and 105. The placenta was delivered manually. The estimated blood loss was 350 mL. She did well postoperatively and was discharged after four days with a packed cell volume of 32%. Her postnatal clinic was unremarkable and she was subsequently discharged from the clinic.

DISCUSSION

CS is the most common obstetric intervention to prevent fetomaternal morbidity and mortality and studies have noted that the most common indication for elective CS is two previous CS.^[4] These were evident in our cases as the three women underwent elective repeat CS on account of two previous CS. Intraoperative findings were of incomplete uterine rupture as also documented by Aliyu *et al.*^[11] A study done at Ebonyi State South East Nigeria showed the highest incidence was found in the para 2–4 group.^[12] Our cases were performed at two of the Ebonyi state tertiary institution and

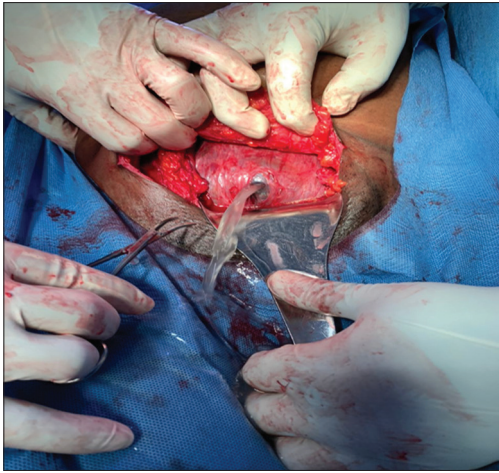


Figure 3: The membranes separated from the muscles with liquor draining in case 3

they fell within the above-stated parity range. Literature noted that the majority of cases in developing countries usually follow prolonged obstructed labour, previous uterine scar, high parity, advanced maternal age, and delays following the decision for emergency CS.^[6-11] The risk factors implicated in our cases were previous uterine scar and high parity.

CSSD is one of the most important complications of CDs^[13,14] as was also noticed in our three cases. The risk factors of caesarean scar rupture should be considered in women undergoing subsequent pregnancies as they may need extra care.^[17] Our patients had routine clinical risk assessment and remained stable. There were no symptoms or signs suggestive of uterine rupture before the CS. It has been noted that the risk of uterine rupture in the presence of a defective scar is related to the degree of thinning of the LUS as measured by ultrasound or MRI.^[16,18-22] Our patients did not benefit from these investigations. If they had, it could have led to earlier delivery with attendant management of possible preterm babies. However, no fetomaternal postoperative morbidity was recorded in our cases.

Bashiri *et al.*^[25] noted that the number of previous CD was an independent risk factor for uterine scar dehiscence. This supports our cases as they all had two previous CS scars. Ramadana *et al.*^[26] showed that uterine scar dehiscence is common among women undergoing elective repeat caesarean delivery, as was seen in our cases, and the increased risk was associated with preterm delivery, tertiary caesarean delivery, or higher and short interdelivery interval of ≤ 24 months. Our cases only had tertiary CS. Hatstat^[18] found out that the dehiscence of a caesarean scar is rarely diagnosed early in pregnancy but is a complication that may lead to uterine rupture if not monitored closely. These were the situation of the cases in this report, as none were previously diagnosed before the intraoperative findings. Hence, the need for this report, so as to encourage obstetricians to add routine radiological assessment of the LUS to the clinical risk assessment in the follow-up of patients with previous CS scars during antenatal visits.

CONCLUSION

Incomplete silent uterine scar rupture as seen in our case series is one of the most common complications of previous CS. The need for early detection, especially a combination of both clinical risk assessment and imaging techniques of the LUS will aid early detection and prompt intervention, thereby reducing possible morbidity and mortality.

Consent

Informed consent was obtained from the patients for the publication of this case report and accompanying images.

Declaration of patient consent

The authors certify that they have obtained all appropriate patient consent forms. In the form, the patients have given their consent for their images and other clinical information to be reported in the journal. The patients understand that their names and initials will not be published and due efforts will be made to conceal their identity, but anonymity cannot be guaranteed.

Financial support and sponsorship

Nil.

Conflicts of interest

There are no conflicts of interest.

REFERENCES

1. Sunday-Adeoye I, Kalu CA. Pregnant Nigerian women's view of caesarean section. *Niger J Clin Pract* 2011;14:276-9.
2. Dresang LT, Leeman L. Caesarean delivery. *Prim Care* 2012;39:145-65.
3. Dahlke JD, Mendez-Figueroa H, Rouse DJ, Berghella V, Baxter JK, Chauhan SP. Evidence-based surgery for caesarean delivery: An updated systematic review. *Am J Obstet Gynecol* 2013;209:294-306.
4. Main EK, Morton CH, Melsop K, Hopkins D, Giuliani G, Gould JB. Creating a public agenda for maternity safety and quality in caesarean delivery. *Obstet Gynecol* 2012;120:1194-8.
5. Zhang J, Troendle J, Reddy UM, Laughon SK, Branch DW, Burkman R, *et al.* Contemporary caesarean delivery practice in the United States. *Am J Obstet Gynecol* 2010;203:326.e10.
6. Qazi Q, Akhtar Z, Khan K, Khan AH. Woman health; uterus rupture, its complications and management in teaching hospital Bannu, Pakistan. *Maedica (Bucur)* 2012;7:49-53.
7. Aziz N, Yousfani S. Analysis of uterine rupture at university teaching hospital Pakistan. *Pak J Med Sci* 2015;31:920-4.
8. Bibi S, Gul K, Gul Z, Gul P. Management of patients with uterine rupture. *Int J Surg Pak* 2014;19:117-20.
9. Mukasa PK, Kabakyenga J, Senkungu JK, Ngonzi J, Kyalimpa M, Roosmalen VJ. Uterine rupture in a teaching hospital in Mbarara, Western Uganda, unmatched case-control study. *Reprod Health* 2013;10:29.
10. Kaye DK, Kakaire O, Nakimuli A, Osinde MO, Mbalinda SN, Kakande N. Lived experiences of women who developed uterine rupture following severe obstructed labour in Mulago hospital, Uganda. *Reprod Health* 2014;11:31.
11. Aliyu LD, Elnafaty AU, Kadas SA, Dattijo LM, Aminu BM. Uterine rupture an obstetrics catastrophe; incidence, risk factors, management and outcome at Abubakar Tafawa Balewa university teaching hospital Bauchi Nigeria. *Trop J Obstet Gynaecol* 2012;29:13-7.
12. Esike CO, Umeora OU, Eze JN, Igberase GO. Ruptured uterus: The unabating obstetric catastrophe in South Eastern Nigeria. *Arch Gynecol Obstet* 2011;283:993-7.
13. Motomura K, Ganchimeg T, Nagata C, Ota E, Vogel JP, Betran AP, *et al.* Incidence and outcomes of uterine rupture among women with prior caesarean section: WHO multicountry survey on maternal and newborn health. *Sci Rep* 2017;7:44093.

14. Abdelazim IA, Shikanova S, Kanshaiym S, Karimova B, Sarsembayev M, Starchenko T. Cesarean section scar dehiscence during pregnancy: Case reports. *J Family Med Prim Care* 2018;7:1561-5.
15. Baron J, Weintraub AY, Eshkoli T, Hershkovitz R, Sheiner E. The consequences of previous uterine scar dehiscence and cesarean delivery on subsequent births. *Int J Gynaecol Obstet* 2014;126:120-2.
16. Sawada M, Matsuzaki S, Nakae R, Iwamiya T, Kakigano A, Kumasawa K, *et al.* Treatment and repair of uterine scar dehiscence during cesarean section. *Clin Case Rep* 2017;5:145-9.
17. Ahmadi F, Siahbazi S, Akhbari F. Incomplete cesarean scar rupture. *J Reprod Infertil* 2013;14:43-5.
18. Hatstat LM. Sonographic assessment of uterine dehiscence during pregnancy in women with a history of cesarean section: A case series. *J Diagn Med Sonogr* 2016;32:283-6.
19. Zhu Z, Li H, Zhang J. Uterine dehiscence in pregnant with previous cesarean delivery. *Ann Med* 2021;53:1265-9.
20. Pomorski M, Fuchs T, Zimmer M. Prediction of uterine dehiscence using ultrasonographic parameters of cesarean section scar in the nonpregnant uterus: a prospective observational study. *BMC Pregnancy and Childbirth* 2014;14:365.
21. Basic E, Basic-Cetkovic V, Kozaric H, Rama A. Ultrasound evaluation of uterine scar after cesarean section. *Acta Inform Med* 2012;20:149-53.
22. Rozenberg P, Goffinet F, Phillippe HJ, Nisand I. Ultrasonographic measurement of lower uterine segment to assess risk of defects of scarred uterus. *Lancet* 1996;347:281-4.
23. Hoffmann J, Exner M, Bremicker K, Grothoff M, Stumpp P, Stepan H. Comparison of the lower uterine segment in pregnant women with and without previous cesarean section in 3T MRI. *BMC Pregnancy Childbirth* 2019;19:160.
24. Jamshed S, Chien SC, Tanweer A, Asdary RN, Hardhantyo M, Greenfield D, *et al.* Correlation between previous cesarean section and adverse maternal outcomes accordingly with Robson classification: Systematic review and meta-analysis. *Front Med (Lausanne)* 2021;8:740000.
25. Bashiri A, Burstein E, Rosen S, Smolin A, Sheiner E, Mazor M. Clinical significance of uterine scar dehiscence in women with previous cesarean delivery: Prevalence and independent risk factors. *J Reprod Med* 2008;53:8-14.
26. Ramadana MK, Kassem S, Itania S, Sinnoc L, Husseinb S, Chahinb R, *et al.* Incidence and risk factors of uterine scar dehiscence identified at elective repeat cesarean delivery: A case-control study. *J Clin Gynecol Obstet* 2018;7:37-42.