

# Analysis of p21 Expression in Cervical Carcinoma at a Tertiary Institution in Ghana: An Immunohistochemical Study

Babatunde Moses Duduyemi<sup>1,2</sup>, Ebenezer Kojo Addai<sup>3</sup>, Kweku Bedu-Addo<sup>3</sup>

Departments of <sup>1</sup>Pathology and <sup>3</sup>Physiology, Kwame Nkrumah University of Science and Technology, Kumasi, Ghana, <sup>2</sup>Department of Anatomic Pathology, University of Sierra Leone Teaching Hospitals Complex, College of Medicine and Allied Health Sciences, Freetown, Sierra Leone

## Abstract

**Background:** Cervical cancer is one of the leading causes of female mortality worldwide. About 85% occur in low-income countries with 13.8% incidence and 14% death in Ghana. p21 has been overexpressed in many cancers. Its overexpression in cervical cancer is linked to tumor growth and a bad prognosis. **Aim:** The expression profile of p21 in our setting is largely unknown, therefore, the necessity to evaluate p21 expression in cervical cancer. **Materials and Methods:** A retrospective and descriptive study design was employed to investigate p21 expression in association with demographic and clinicopathological features on formalin-fixed paraffin-embedded cervical cancer tissues. The age, histologic type, and tumor grade of patients were abstracted from the hospital records between January 1, 2015, and December 31, 2016. Tissue microarray of suitable blocks was constructed, and immunohistochemistry was performed. Data were analyzed using the Statistical Package for the Social Sciences (SPSS) version 26. **Results:** One hundred and thirty-five cases were used for the study with an age range of 31–115 years and mean age of 58.93 years (standard deviation  $\pm$  17.88). Majority of the cases were postmenopausal (40–59 years). Squamous cell carcinoma (SCC) was the most common histological type (96.3%) with the nonkeratinizing variant having the highest frequency (53.1%). Majority of the cases were high grade; Grade 2 (33.3%) and Grade 3 (49.6%). Majority of the cases (66.7%) stained positive for p21 antibody. The associations between p21 and the clinicopathological characteristics were not statistically significant ( $P > 0.05$ ). p21 was more overexpressed in SCC (64.8%) than adenocarcinoma. **Conclusion:** An overexpression of p21 in this study suggests that it may contribute to antiapoptosis in cervical cancer leading to tumor progression, aggressive behavior, and poor prognosis.

**Keywords:** Cervical cancer, Ghana, immunohistochemistry, p21

## INTRODUCTION

Approximately seven years ago, cervical cancer held the rank of the third leading cause of cancer mortality among females<sup>[1]</sup> and the most prevalent gynecological malignancy globally. Owing to early screening and vaccination efforts, the disease was significantly reduced in developed countries but about 85% still occurred in low-income countries.<sup>[2]</sup> Recent reports show an increase in the prevalence of cervical cancer in some developed countries for women under 50 years<sup>[3]</sup> indicating a shift in the disease's dynamics.

According to the World Health Organization cancer country profile for 2020, the second largest cause of cancer in Ghana is cervical cancer, with 13.8% incidence and 14% death.<sup>[4]</sup> A number of studies showed that 2119 women die annually of 3151 diagnosed with cervical cancer.<sup>[5,6]</sup> Human papillomavirus (HPV), smoking, and multiple sexual partners

among others are the etiological agents of cervical cancer,<sup>[7,8]</sup> with the HPV being the most dominant actor, causing 80%–90% of the infection.<sup>[9]</sup>

Tumor growth is caused by an imbalance between cell proliferation and cell death. p21, a well-known cyclin-dependent kinase inhibitor (CDK), activated by p53 or p53 independent pathway, is shown to play an important role in cell cycle progression control, by binding and inhibiting the cyclin/CDK complex.<sup>[10]</sup> Regardless of the pathway

**Address for correspondence:** Prof. Babatunde Moses Duduyemi, Department of Anatomic Pathology, University of Sierra Leone Teaching Hospitals Complex, Freetown, Sierra Leone.  
E-mail: babsdudu@yahoo.com

This is an open access journal, and articles are distributed under the terms of the Creative Commons Attribution-NonCommercial-ShareAlike 4.0 License, which allows others to remix, tweak, and build upon the work non-commercially, as long as appropriate credit is given and the new creations are licensed under the identical terms.

**For reprints contact:** WKHLRPMedknow\_reprints@wolterskluwer.com

**How to cite this article:** Duduyemi BM, Addai EK, Bedu-Addo K. Analysis of p21 expression in cervical carcinoma at a tertiary institution in Ghana: An immunohistochemical study. *Niger J Med* 2023;32:314-8.

**Submitted:** 06-Jul-2023

**Revised:** 07-Aug-2023

**Accepted:** 08-Aug-2023

**Published:** 22-Sep-2023

### Access this article online

Quick Response Code:



**Website:**  
<http://journals.lww.com/NJOM>

**DOI:**  
10.4103/NJM.NJM\_69\_23

employed, the effector functions of p21 are either tumor suppression (apoptosis promotion), acting as proto-oncogenes, or tumor promotion (apoptosis inhibition) by encouraging oncogenesis. p21 action as an activator or inhibitor is in part dependent on its level of expression or genetic background (due to the fact that p21 has the propensity to promote G1/S cyclin/CDK complex). At low and modest expression levels in a normal cell, p21 functions as an activator initiating the cell cycle arrest function, whereas high levels of expression, usually in cancerous cells, play the role of an inhibitor, inhibiting the cell cycle arrest function.<sup>[11]</sup> Using immunohistochemistry (IHC), researchers have discovered that p21 is expressed in a variety of human cancers and is linked to tumor growth and a bad prognosis.<sup>[12,13]</sup>

Even though there is a growing body of evidence supporting p21 expression in cancer in developed countries, there are limited studies performed on p21 expression in cervical cancer in developing countries. The main objective of this study, therefore, is to analyze the expression of p21 cervical cancer and to relate with clinicopathological features.

## MATERIALS AND METHODS

### Ethical approval

Ethical approval was obtained from the Committee on Human Research, Publications, and Ethics, KNUST School of Medicine and Dentistry (CHRPE/AP/314/20) and the Research and Development Unit, Komfo Anokye Teaching Hospital (KATH) (Reg No: RD/CR18/203) on “Molecular profiling of cervical cancer in Kumasi.”

### Study design and tissue samples

A retrospective and descriptive study design was employed to investigate the expression status of p21 protein on formalin-fixed paraffin-embedded (FFPE) cervical cancer tissues that were obtained from patients seen at the KATH for two-year period. The study describes the creation of a tissue microarray (TMA) from 135 cervical tumor cases out of 230 diagnosed cases. Patients’ data including age, histologic type, and tumor grade were abstracted. All consecutive malignant cases seen within the study period were included, whereas cases with missing patient records and missing or damaged tissues were excluded from the study.

### Hematoxylin and eosin slides preparation and review

FFPE tissue blocks were used to create hematoxylin and eosin (H and E) stained slides. The H and E slides were assessed using the Leica DM200 LED microscope (Leica MICROSYSTEMS) in accordance with the requirements of the Royal College of Pathologists and the National Quality Assessment Service. Representative tumor sites and clinicopathological information were noted.

### Tissue microarray construction

TMA recipient tissue blocks were created using the Leica EG1150H Paraffin embedding station, and the tissue cores or discs were punched and introduced using the Automated TMA

machine (TMA Master by 3DHISTECH-2016). Two cylindrical cores (1 mm each) were punched out of the donor blocks using the TMA map as a guide. After inserting the tissue cores into the recipient block, it was placed at the mold/cassette warmer section of the Leica EG1150H Paraffin embedding station for few minutes. This allowed the tissue cores to gently sink further into the recipient tissue blocks. The slices were then incubated overnight at 37 degrees Celsius before IHC testing.

### Immunohistochemical staining

Each recipient TMA block was sliced into 3 µm-thick sections with a microtome and distributed onto Superfrost Plus Slides. The slides were deparaffinized in xylene and rehydrated in a graded series of ethanol (100, 90, and 70%) diluted with Tris-buffered saline. Following that, the slides were washed in distilled water. The slides were then placed in a pressure cooker and treated in citrate buffer for antigen retrieval. Background and nonspecific staining were blocked using peroxidase-methanol solutions and casein solutions, respectively. Immunohistochemical dilutions for p21 were performed according to the manufacturer guidelines (*antibody – p21 CST; clone – WAF1/CIP112D1; dilution – 50; control – Tonsil; company – CST*); and the optimal tissue sections were incubated in the diluted primary antibodies. The sections were then immersed in a secondary antibody conjugated with peroxidase and antiperoxidase before being developed in diaminobenzidine tetrahydrochloride. They were then counterstained in hematoxylin, dehydrated in various percentages of alcohol (70%, 80%, 90%, 95%, and 100%), and mounted with DPX mountant.

### Scoring of immunohistochemistry

In homogeneously stained slides, five high-power fields were selected randomly for the biomarker count. TMA sections were assessed for the presence of positive staining. The tumors were scored based on slight modifications of methods described earlier,<sup>[14]</sup> 0 represented <10% positive cells, 1 represented 10%–40%, 2 represented 40%–70%, and 3 represented ≥70%.

### Statistical analysis

Data analysis was carried out using Statistical Package for the Social Sciences (SPSS) version 26, (IBM, Chicago, IL, USA). Correlations between parameters were assessed using the Chi-square test as Pearson’s correlation coefficient and Fischer’s exact test were applicable. All statistical tests were two sided and considered statistically significant at  $P < 0.05$  with a confidence interval set at 95%.

## RESULTS

Two hundred and thirty cases of cervical cancer were seen in the study period with 135 cases satisfying the inclusion criteria.

The age range was 31–115 years with a mean age of 58.93 years (standard deviation ± 17.88). The median age of 56 years was consistent with the 40–59 years cohort [Table 1]. The age range of 40–59 years emerged as the most burdened group with cervical cancer, comprising the majority of the

cases (38.5%). Squamous cell carcinoma (SCC) was the most common histological type (96.3%) with the nonkeratinizing variant having the highest frequency (53.1%). Other histological types are presented in Table 1. Majority (82.9%) of the patients presented with high-grade tumors (Grades 2 and 3); whereas low grade (Grade 1) was 17.0%.

### Immunohistochemical staining of p21

Among the 108 eligible IHC cases, about two-third (66.7%) stained positive for p21 while 33.3% were negative [Table 2]. Figure 1 illustrates the photomicrographs of the cervical tissue cores that are positively stained for the p21 biomarker with the control.

### Expression status of p21 with clinicopathological features

Statistically, the associations between p21 and the clinicopathological characteristics were not significant ( $P > 0.05$ ). Overexpression of the marker was, however, evident

in 66.7% of cases. p21 was most commonly overexpressed in SCC histological type (64.8%), whereas low expression was found in adenocarcinomas (ADCs) (3.7%) [Table 3].

## DISCUSSION

The distribution of cervical cancer cases in this study aligns with global observations reported and the age group with the highest burden of cervical cancer in this study was consistent with global data on cervical cancer.<sup>[3,15]</sup> This alignment underscores the importance of this study's outcomes and reaffirms the significance of targeted interventions and screening efforts in this specific age group to improve early detection and treatment outcomes.<sup>[16]</sup>

The mean age of 58.9 years was consistent with a number of studies.<sup>[17,18]</sup> However, the documented findings by ICO/IARC and Oguntayo *et al.* were lower mean ages.<sup>[19,20]</sup> Approximately 43.7% of the women were older than 50 years, which is similar to an earlier report.<sup>[18]</sup>

SCC in this study was the most common histologic variant accounting for 96.3%. Similar findings are reported in previous researches,<sup>[17,18]</sup> with SCC averaging 93.8% and 90.1%, respectively. However, a contrasting SCC occurrence of 56.5% was reported.<sup>[21]</sup> This increase could be attributed to several factors, including the significant role of oncogenic HPV infection,<sup>[22]</sup> late screening habits, and the postmenopausal age of the majority of patients.<sup>[18]</sup> The well-established association between high-risk HPV strains and the development of SCC underscores the importance of HPV screening programs. Furthermore, late screening habits and limited access to health care may lead to delayed diagnosis and hinder early intervention, potentially contributing to the higher SCC incidence.<sup>[18]</sup> The finding of a higher prevalence of SCC in postmenopausal women aligns with the notion of hormonal changes and the long-term cumulative effects of HPV infection in promoting cervical cancer.<sup>[23]</sup>

ADC accounted for 3.7% of the 135 patients in this study which is in keeping with earlier reports (5.8% of 1427 cases<sup>[18]</sup> and 5.4% of 1094 cases<sup>[17]</sup>), all in developing countries. In high-income nations, however, improved specimen collection and increased knowledge of ADC precursors among cytopathologists and clinicians have contributed to a further decline in ADC incidence.<sup>[22,24]</sup>

The degree of differentiation of the squamous cell contributes to the aggressiveness of the tumor.<sup>[25]</sup> In this study, the

**Table 1: Distribution of cervical cancer according to age and histological features**

	<i>n</i> (%)
Age groups (years)	
20–39	24 (17.8)
40–59	52 (38.5)
60–79	41 (30.4)
>79	18 (13.3)
Total	135 (100)
Histological type	
SCC	130 (96.3)
ADC	5 (3.7)
Total	135 (100)
SCC variant	
BSCC	6 (4.6)
Keratinizing	55 (42.3)
NK	69 (53.1)
Missing	5
Total	135 (100)
Tumor grade	
Grade 1	23 (17.0)
Grade 2	45 (33.3)
Grade 3	67 (49.6)
Total	135 (100)

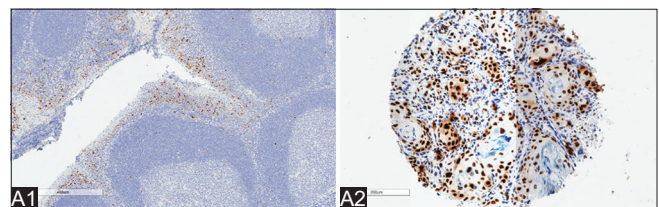
\*All the percentages were calculated on the number of valid cases.

SCC: Squamous cell carcinoma, ADC: Adenocarcinoma, BSCC: Basaloid SCC, NK: Nonkeratinizing

**Table 2: Distribution of cervical cancer according to p21 staining**

Biomarker	<i>n</i> (%)
<b>p21</b>	
Negative	36 (33.3)
Positive	72 (66.7)
Missing	27
Total	135 (100)

\*Missing cases were lost to immunohistochemistry



**Figure 1:** Photomicrograph showing positive immunohistochemical staining of control (A1) and nonkeratinizing squamous cell carcinoma for p21 antibody (A2). p21 Stain 400  $\mu$ m and 200  $\mu$ m, respectively

**Table 3: Association of p21 with clinicopathological features**

Clinicopathological features	p21			$\chi^2$ (Fischer's exact)	P
	Positive (%)	Negative (%)			
Age groups					
20–39	12.0	7.4		5.779	0.125
40–59	29.6	9.3			
60–79	18.5	8.3			
>79	6.5	8.3			
Histological type					
SCC	64.8	32.4		0	0.780
ADC	1.9	0.9			
SCC variant					
BSCC	5.7	0		3.162	0.221
Keratinizing	21.9	13.3			
NK	44.8	20.0			
Histological grade					
Grade one	7.4	3.7		0.831	0.664
Grade two	18.5	12.0			
Grade three	40.7	17.6			

\* $P \leq 0.05$ , considered significant. SCC: Squamous cell carcinoma, ADC: Adenocarcinoma, BSCC: Basaloid SCC, NK: Nonkeratinizing

nonkeratinizing SCC (NKSCC) variant accounted for 53.1% of cervical cancer cases, whereas the KSCC variant accounted for 42.3%. These findings are in line with a similar study (NKSCC 54.74%, KSCC 45.26%),<sup>[25]</sup> but contrast that of Der *et al.*, in Ghana.<sup>[18]</sup> BSCC is a very rare and aggressive form of the SCC variant studied.<sup>[26]</sup> The rarity of this variant has resulted in limited publications on the subject. However, in our study, it was identified as the third-most common SCC variant accounting for 4.4% of the cases. This finding is consistent with a separate study where a similar prevalence of 1.4% was documented.<sup>[18]</sup>

In terms of decreasing frequencies, the tumor grade of this study conforms to and supports a similar trend mostly in developing nations, particularly Africa,<sup>[17,21]</sup> and in other developed countries.<sup>[27]</sup> This has been attributed to be because most patients present with a late stage of the cancer: low or no awareness, predisposing factors such as HIV,<sup>[28]</sup> and postmenopausal age of patients.<sup>[18]</sup>

In this study, the protein p21 was shown to be highly expressed in the majority of the patients (66.67%), agreeing with earlier studies<sup>[29,30]</sup> with contrasting reports from elsewhere.<sup>[31]</sup> The difference in expression could be attributed to the immunostaining approach, tumor scoring method, or clone and dilution of antibody used.<sup>[30]</sup>

The results of this study mirror that reported by previous studies.<sup>[29,30]</sup> A deserving explanation for the disparity in frequencies of p21 expression is attributable to the fact that p21 has a different role in the pathogenesis of SCC, BSCC, and ADC or antibody difference.<sup>[30]</sup>

In this study, there was considerable increase in p21 expression from Grade 1 to Grade 3 with no significant statistical difference. This observation mirrors that of a number of

studies,<sup>[32,33]</sup> but disagrees with the results established by a previous study.<sup>[30]</sup> The pattern of increase could mean that HPV 16 E7 proteins blocked the ability of p21 to inhibit CDK activity and proliferating cell nuclear antigen dependent DNA replication,<sup>[34]</sup> or that p21 or its targets have been mutated or its targets have been sufficiently overexpressed to offset p21.<sup>[29]</sup>

p21 overexpression was thought to be a poor prognostic marker in cervical cancer,<sup>[30]</sup> but has been reported as a positive survival marker in other malignancies.<sup>[35,36]</sup> From this study, p21 in cervical cancer probably has a poor prognostic value since the expression was more in high grade (59.2%) than low grade (7.4%), which is in tandem with an earlier study showed that overexpression of p21 contributed to aggressiveness and invasiveness of the cancer.<sup>[33]</sup>

## CONCLUSION

An overexpression of p21 in this study suggests that it may contribute to antiapoptosis in cervical cancer, thereby leading to tumor progression, aggressive behavior, and poor prognosis.

## Financial support and sponsorship

Nil.

## Conflicts of interest

There are no conflicts of interest.

## REFERENCES

- McGuire S. World cancer report 2014. Geneva, Switzerland: World Health Organization, International Agency for Research on Cancer, WHO Press, 2015. Adv Nutr 2016;7:418-9.
- Parkin DM, Bray F. Chapter 2: The burden of HPV-related cancers. Vaccine 2006;24 Suppl 3:S311-25.
- He WQ, Li C. Recent global burden of cervical cancer incidence and mortality, predictors, and temporal trends. Gynecol Oncol 2021;163:583-92.

4. Cancer Country Profile. Ghana. Available from: <https://www.who.int/publications/m/item/cancer-gha-2020>. [Last accessed on 2023 Jun 15].
5. Bruni L, Diaz M, Barrionuevo-Rosas L, Herrero R, Bray F, Bosch FX, *et al.* Global estimates of human papillomavirus vaccination coverage by region and income level: A pooled analysis. *Lancet Glob Health* 2016;4:e453-63.
6. Wright TC Jr., Stoler MH, Parvu V, Yanson K, Eckert K, Kodsi S, *et al.* Detection of cervical neoplasia by human papillomavirus testing in an atypical squamous cells-undetermined significance population: Results of the Becton Dickinson Onclarity trial. *Am J Clin Pathol* 2019;151:53-62.
7. Walboomers JM, Jacobs MV, Manos MM, Bosch FX, Kummer JA, Shah KV, *et al.* Human papillomavirus is a necessary cause of invasive cervical cancer worldwide. *J Pathol* 1999;189:12-9.
8. Adams AR, Nortey PA, Dorte BA, Asmah RH, Wiredu EK. Cervical human papillomavirus prevalence, genotypes, and associated risk factors among female sex workers in greater Accra, Ghana. *J Oncol* 2019;2019:8062176.
9. Dasari S, Shouri RN, Rajendra W, Valluru L. Effect of concurrent radiochemotherapy and chemotherapy on serum proteins for prospective predictors of patients with HPV induced cervical cancer. *Biomed Pharmacother* 2014;68:315-20.
10. Sherr CJ, Roberts JM. CDK inhibitors: Positive and negative regulators of G1-phase progression. *Genes Dev* 1999;13:1501-12.
11. Morisaki H, Ando A, Nagata Y, Pereira-Smith O, Smith JR, Ikeda K, *et al.* Complex mechanisms underlying impaired activation of CDK4 and CDK2 in replicative senescence: Roles of p16, p21, and cyclin D1. *Exp Cell Res* 1999;253:503-10.
12. Chen M, Huang J, Zhu Z, Zhang J, Li K. Systematic review and meta-analysis of tumor biomarkers in predicting prognosis in esophageal cancer. *BMC Cancer* 2013;13:539.
13. Shamloo B, Usluer S. p21 in cancer research. *Cancers (Basel)* 2019;11:1178.
14. Tarakji B, Kujan O, Nassani MZ. Immunohistochemical expression of p53 in pleomorphic adenoma and carcinoma ex pleomorphic adenoma. *J Cancer Epidemiol* 2010;2010:250606.
15. Awua AK, Sackey ST, Osei YD, Asmah RH, Wiredu EK. Prevalence of human papillomavirus genotypes among women with cervical cancer in Ghana. *Infect Agent Cancer* 2016;11:4.
16. Ebu NI, Amisssah-Essel S, Asiedu C, Akaba S, Pereko KA. Impact of health education intervention on knowledge and perception of cervical cancer and screening for women in Ghana. *BMC Public Health* 2019;19:1505.
17. Titiloye NA, Okai I, Duduyemi BM. Histopathological features of cervical cancer in a tertiary hospital in Kumasi Ghana: A 9 year retrospective study. *J Med Biomed Sci* 2020;7:19-23.
18. Der EM, Adu-Bonsaffoh K, Tettey Y, Kwame-Aryee RA, Seffah JD, Alidu H, *et al.* Clinico-pathological characteristics of cervical cancer in Ghanaian women. *J Med Biomed Sci* 2014;3:27-32.
19. Oguntayo O, Zayyan M, Kolawole A, Adewuyi S, Ismail H, Koledade K. Cancer of the cervix in Zaria, Northern Nigeria. *Ecancermedicalscience* 2011;5:219.
20. ICO/IARC. Human Papillomavirus and Related Cancers, Fact Sheet, p. 1-2. Available from: [https://hpvcentre.net/statistics/reports/GHA\\_FS.pdf](https://hpvcentre.net/statistics/reports/GHA_FS.pdf). [Last accessed on 2023 Jun 15].
21. Ndubuka GI, Ngwogu KO, Ejeta KO, Okafor CW, Ajugo E, Nwosu IO. The occurrence and pattern of uterine cervix lesions in the tropics: The Igbo women of Eastern Nigeria experience. *Int J Forensic Sci Pathol* 2019;6:400-6.
22. Mathew A, George PS. Trends in incidence and mortality rates of squamous cell carcinoma and adenocarcinoma of cervix – Worldwide. *Asian Pac J Cancer Prev* 2009;10:645-50.
23. Roura E, Travier N, Waterboer T, de Sanjosé S, Bosch FX, Pawlita M, *et al.* The influence of hormonal factors on the risk of developing cervical cancer and pre-cancer: Results from the EPIC Cohort. *PLoS One* 2016;11:e0147029.
24. Saito T, Katabuchi H. Annual report of the committee on gynecologic oncology, Japan Society of Obstetrics and Gynecology: Patient annual report for 2013 and treatment annual report for 2008. *J Obstet Gynaecol Res* 2016;42:1069-79.
25. Kumar S, Shah JP, Bryant CS, Imudia AN, Ali-Fehmi R, Malone JM Jr., *et al.* Prognostic significance of keratinization in squamous cell cancer of uterine cervix: A population based study. *Arch Gynecol Obstet* 2009;280:25-32.
26. Grayson W, Cooper K. A reappraisal of “basaloid carcinoma” of the cervix, and the differential diagnosis of basaloid cervical neoplasms. *Adv Anat Pathol* 2002;9:290-300.
27. Ting J, Rositch AF, Taylor SM, Rahangdale L, Soeters HM, Sun X, *et al.* Worldwide incidence of cervical lesions: A systematic review. *Epidemiol Infect* 2015;143:225-41.
28. Izudi J, Adrawa N, Amongin D. Precancerous cervix in human immunodeficiency virus infected women thirty years old and above in Northern Uganda. *J Oncol* 2016;2016:5473681.
29. van de Putte G, Holm R, Lie AK, Tropé CG, Kristensen GB. Expression of p27, p21, and p16 protein in early squamous cervical cancer and its relation to prognosis. *Gynecol Oncol* 2003;89:140-7.
30. Cheung TH, Lo KW, Yu MM, Yim SF, Poon CS, Chung TK, *et al.* Aberrant expression of p21(WAF1/CIP1) and p27(KIP1) in cervical carcinoma. *Cancer Lett* 2001;172:93-8.
31. Ibnat N, Kamaruzman NI, Ashaie M, Chowdhury EH. Transfection with p21 and p53 tumor suppressor plasmids suppressed breast tumor growth in syngeneic mouse model. *Gene* 2019;701:32-40.
32. Aljabery F, Olsson H, Gimm O, Jahnson S, Shabo I. M2-macrophage infiltration and macrophage traits of tumor cells in urinary bladder cancer. *Urol Oncol* 2018;36:159.e19-26.
33. Abbas T, Dutta A. p21 in cancer: Intricate networks and multiple activities. *Nat Rev Cancer* 2009;9:400-14.
34. Funk JO, Waga S, Harry JB, Espling E, Stillman B, Galloway DA. Inhibition of CDK activity and PCNA-dependent DNA replication by p21 is blocked by interaction with the HPV-16 E7 oncoprotein. *Genes Dev* 1997;11:2090-100.
35. Xiangming C, Hokita S, Natsugoe S, Tanabe G, Baba M, Takao S, *et al.* p21 expression is a prognostic factor in patients with p53-negative gastric cancer. *Cancer Lett* 2000;148:181-8.
36. Schmider A, Gee C, Friedmann W, Lukas JJ, Press MF, Lichtenegger W, *et al.* p21 (WAF1/CIP1) protein expression is associated with prolonged survival but not with p53 expression in epithelial ovarian carcinoma. *Gynecol Oncol* 2000;77:237-42.