

Scalp Reconstruction following Excision of Malignant Tumors in Southeastern Nigeria

Obinna Remigius Okwesili, Uchechukwu Johnson Achebe, Okechukwu Oliver Onumaegbu, Wilfred Chukwuemeka Mezue, Mark Chukwunweike Chikani, Ephraim Eziechina Onyia

Department of Surgery, University of Nigeria Teaching Hospital, Ituku-Ozalla, Enugu State, Nigeria

Abstract

Background: Malignant scalp tumors are not common and constitute a small percentage of all scalp tumors. Reconstruction of the scalp defects following oncological resection presents peculiar challenges. **Aim:** The aim of the study is to report our experience in reconstructing scalp defect of varying sizes after the excision of malignant tumours using a variety of techniques. **Materials and Methods:** This was a retrospective review of patients who had scalp reconstruction after oncological resections from June 2010 to May 2014 (four years) at our teaching hospital in the South-east of Nigeria. Data on the demographics, nature of the scalp tumors, site, size of the defects, mode of scalp reconstruction, and outcomes were collected and analyzed. **Results:** Of the 17 patients who had scalp reconstruction, 29.4% of them were men and 70.6% were women (M:F = 5:2). The mean age of the patients was 41.2 ± 4.98 years (range: 19–85 years). The majority of the patients (47.1%) were young adults between 20 and 40 years, and the least involved age group (11.8%) was 13–19 years. The most common etiology of malignant scalp tumors was squamous cell carcinoma (52.9%). The temporal region was the most common site (41.2%) affected. Most of the defects were between 6.1 and 9.0 cm in diameter, followed by defects that were <3 cm in diameter. Neurosurgical assistance was required in 5 (29.4%) patients where the tumor had involved the skull bone. Tumor recurrence was noted in 3 (17.6%) patients within one year of follow-up. **Conclusion:** Scalp reconstruction after oncological resection presents a peculiar esthetic challenge due to the hair-bearing skin of the scalp and the need to maintain the hairline. The use of local flaps from the scalp remains the first and the best option. For very large scalp defects, free flap through microvascular surgery is the preferred option.

Keywords: Malignant scalp tumors, reconstructing scalp defects, scalp reconstruction, tumors of the scalp

INTRODUCTION

Malignant scalp tumors are not common and constitute only about 1%–2% of all scalp tumors.^[1] Squamous cell carcinoma (SCC) and basal cell carcinoma (BCC) are the most common of these malignant tumors.^[2] Reconstruction of some scalp defects following oncological resection is quite challenging.^[2,3] The size, depth, and location of the scalp defects are important factors that influence the preferred method of reconstruction.^[4,5] Only small wounds are managed by direct closure, due to the inelastic galea aponeurosis that makes scalp defects difficult to close.^[6,7] Medium-sized wounds are preferably managed with local flaps, which may be advancement flaps, transposition, or rotation flaps.^[6-8] Split-skin graft (SSG) is an option for closing some of these defects, although it results in alopecia.^[9] Free flaps are frequently used for very large defects that may be complex, although the use of distant pedicled flaps is a less-popular

alternative. Either of these flaps still results in alopecia in the reconstructed area. We report our experience in reconstructing scalp defects of various sizes after the excision of malignant tumors utilizing a variety of techniques.

MATERIALS AND METHODS

This was a retrospective review of patients who had scalp reconstruction after the excision of malignant scalp tumors from June 2010 to May 2014 (four years) at our teaching

Address for correspondence: Dr. Obinna Remigius Okwesili, Department of Surgery, University of Nigeria Teaching Hospital, Ituku-Ozalla, Enugu State, Nigeria.
E-mail: obiokwesili@gmail.com

This is an open access journal, and articles are distributed under the terms of the Creative Commons Attribution-NonCommercial-ShareAlike 4.0 License, which allows others to remix, tweak, and build upon the work non-commercially, as long as appropriate credit is given and the new creations are licensed under the identical terms.

For reprints contact: WKHLRPMedknow_reprints@wolterskluwer.com

How to cite this article: Okwesili OR, Achebe UJ, Onumaegbu OO, Mezue WC, Chikani MC, Onyia EE. Scalp reconstruction following excision of malignant tumors in Southeastern Nigeria. *Niger J Med* 2023;32:309-13.

Submitted: 24-Mar-2023

Revised: 16-Apr-2023

Accepted: 13-Aug-2023

Published: 22-Sep-2023

Access this article online

Quick Response Code:



Website:
<http://journals.lww.com/NJOM>

DOI:
10.4103/NJM.NJM_32_23

hospital in South-east Nigeria. Information was retrieved from the operating theater and medical records. Data were extracted manually from the case notes of the patients and the operating theater records. Information obtained includes patients' demographics, nature of the scalp tumors, site, and size (diameter) of the defects. The methods of reconstruction used for the different sizes of scalp defects were also noted. Diagnoses made based on histopathology reports were obtained. All the surgeries were performed under general anesthesia. A preliminary biopsy was done for the large tumors before definitive resection, and this was used in deciding the resection margin to use. For BCC, resection margins between 5 and 10 mm were used, while margins between 10 and 20 mm were used for SCCs.

All the patients were followed up for at least 6 months. Only seven patients out of the 17 patients were available for one-year follow-up; the rest of them defaulted at varied times afterward.

The sites of the scalp considered were the temporal, parietal, frontal, and occipital regions. Tumors sitting astride two sites were recorded accordingly. The patients were divided into four age groups: 13–19 years (adolescents), 20–40 years (young adults), 41–64 years (middle-aged), and 65 years and above (elderly).

The data obtained from the records were analyzed using the Statistical Package for the Social Sciences (SPSS) version 25 (IBM Corp., Armonk, New York, USA).

RESULTS

A total of 17 patients who had scalp reconstruction following oncological resection during the period reviewed met the inclusion criteria. There were 5 (29.4%) men and 12 (70.6%) women. The mean age of the patients was 41.2 ± 4.98 years (range: 19–85 years). The majority of the patients (47.1%) were young adults between 20 and 40 years. The age group with the smallest number of patients (11.8%) was the 13–19-year age group [Figure 1]. No child was affected by malignant scalp tumors during the period under review.

The histopathologic diagnosis of more than half of the malignant scalp tumors (52.9%) was SCC [Figure 2]. The various parts of the scalp tumors affected are shown in Figure 3. The temporal region (right and left sides inclusive) was the most common site (41.2%) affected by these tumors. Most of the resultant defects following the excision of these tumors were between 6.1 and 9.0 cm in diameter, and next in number are those <3 cm in diameter [Figure 4].

Modes of reconstruction for closing the defects were direct closure, split-skin grafting, use of local flaps from the scalp, and use of distant flaps. Skin grafting was used in closing defects of 3–6 cm and some defects of 6.1–9 cm. Local flaps were also used in reconstructing a few defects of 6.1–9 cm [Figure 5]. Neurosurgical assistance was required in 5 (29.4%) patients where the tumor had eroded the skull. Tumor recurrence was noted in 3 (17.6%) patients within one year of follow-up.

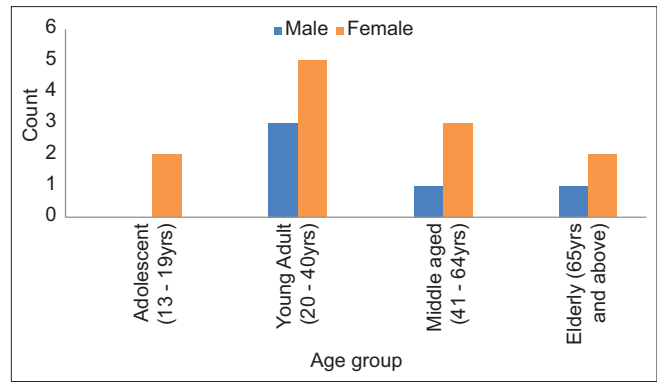


Figure 1: Gender distribution of the patients by age groups

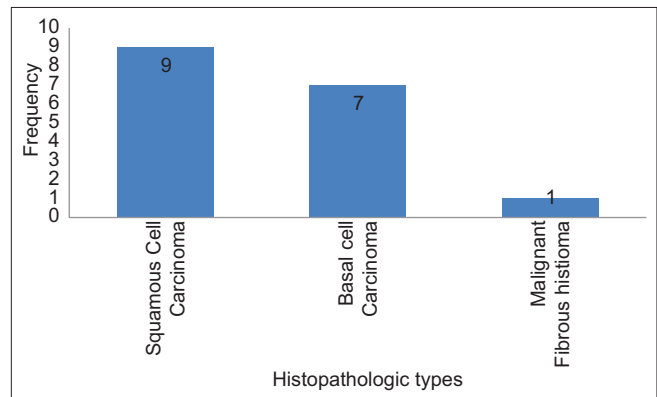


Figure 2: Histopathologic types of the malignant scalp tumors

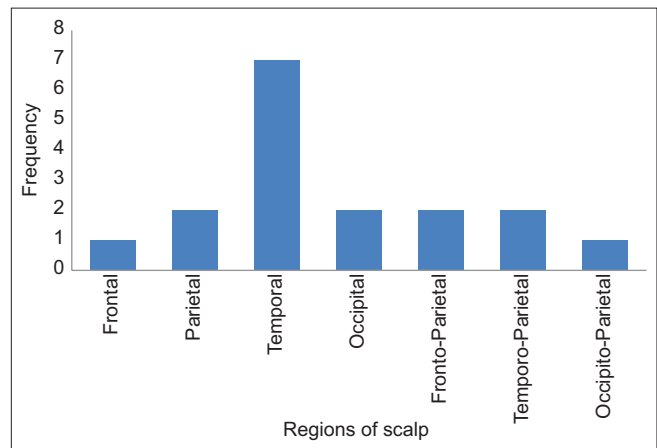


Figure 3: The regions of the scalp affected by malignant tumors

DISCUSSION

The ideal goals of scalp reconstruction are to replace scalp tissue with scalp tissue and not to violate the hairline and sideburns.^[4,10] The use of scalp tissue, when direct closure is possible, or the use of local flaps often gives the best cosmetic result. However, this is not usually feasible in most scalp defects following oncological resection. Undermining the edges of a scalp defect does not significantly increase the feasibility of direct wound closure. We found it more rewarding to score the galea (galeotomies) perpendicular to the direction of movement

required.^[11] Most defects that cannot be closed directly require SSG or local flaps either in single-staged reconstruction or as the first stage in the use of the “crane principle” in reconstruction. Defects too large for local flap coverage or too complex for SSG cover will require free tissue transfer. In some instances, especially where such expertise is available, the method of using a distant pedicled flap for coverage is considered, and it has been used in many recently reported cases.

The scalp defects were classified into small (<3 cm), moderate (3–6 cm), large (6.1–9 cm), and extensive (>9 cm) based on their sizes.^[5] Defects that are <3 cm are usually closed directly [Figure 6] if this does not significantly alter the hairline.^[7] Postexcision scalp defects of 3–6 cm diameter are usually closed using SSGs or local flaps. We used skin grafts [Figure 7] in closing some of these moderate-size defects (11.76%) and a few large defects (17.65%). The advantage of using skin grafts for closing defects created by oncological resection is the fact that

any recurrence of the tumor is detected early.^[8] The sparing of the pericranium during oncological resection is important for the use of SSGs and can only be achieved when there is no local metastasis involving the bone. Tissue expanders can be used in conjunction with SSG to facilitate coverage of the secondary defect with expanded nearby scalp tissue. This option, however, was not acceptable to our patients, in spite of the established better cosmesis after SSG, due to the cost, longer hospital stays, and the “bumps” that would have to be endured with inflation of the tissue expanders before the final surgery.

Defects of 6–9 cm diameter were closed using large pedicled flaps [Figures 5 and 8]. The pedicled flaps design should incorporate one of the five paired major scalp arteries, namely: supratrochlear, supraorbital, superficial temporal, posterior auricular, and occipital arteries. We used pedicled local flaps

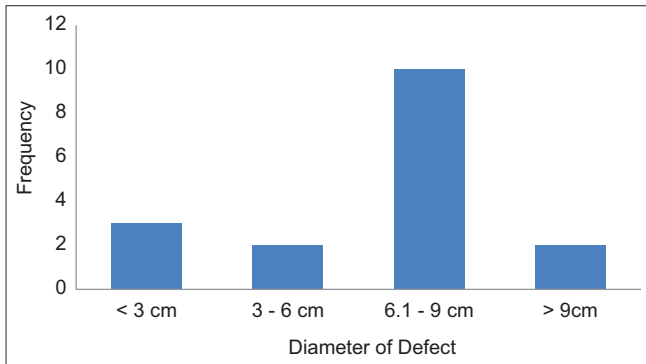


Figure 4: Grouping of the reconstructed defects by their sizes

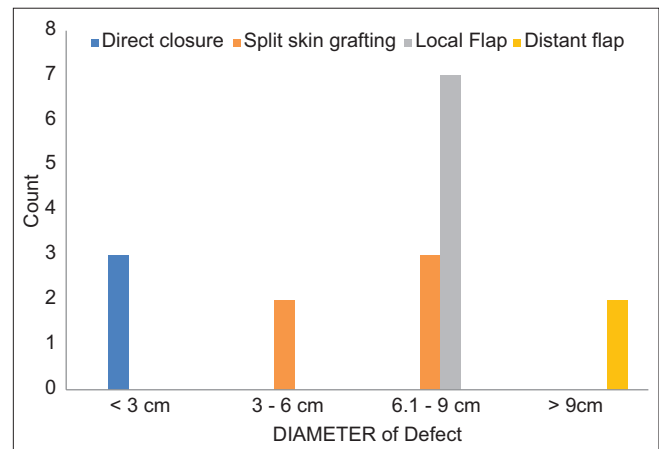


Figure 5: Modes of reconstruction used for the various sizes of the defects

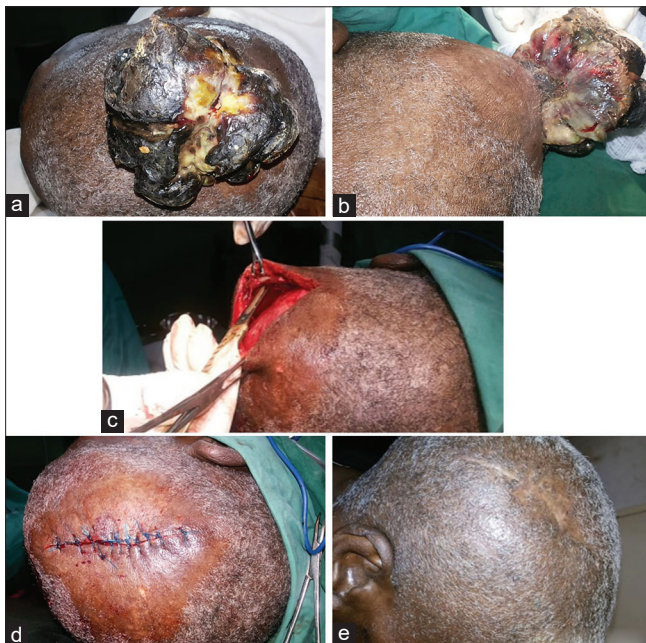


Figure 6: Wound closure by direct apposition of the edges after scoring the galea. (a) Tumor with necrotic tissues, (b) Same tumor with narrow pedicle, (c) Galeal scoring being done, (d) Edges apposed, (e) The scalp a few weeks later

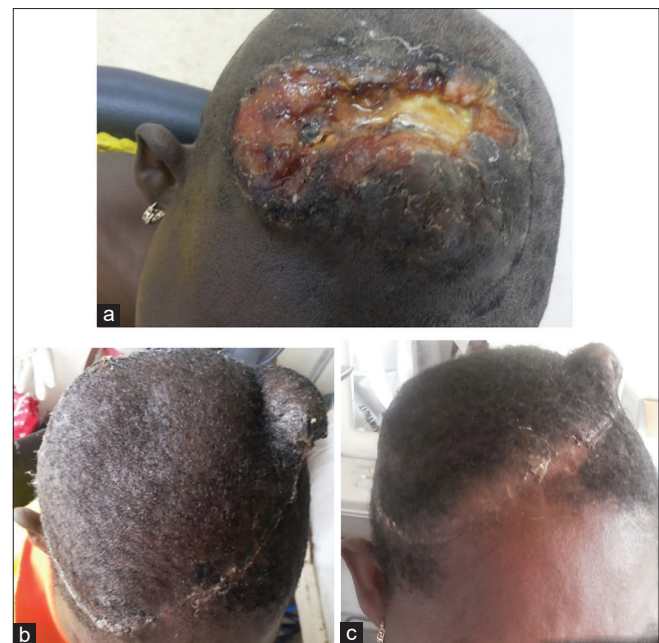

Figure 7: Scalp reconstruction with local flap after tumor excision. (a) Wide based tumor, (b) Wide local flap used for covering defect, (c) Frontal view after flap cover

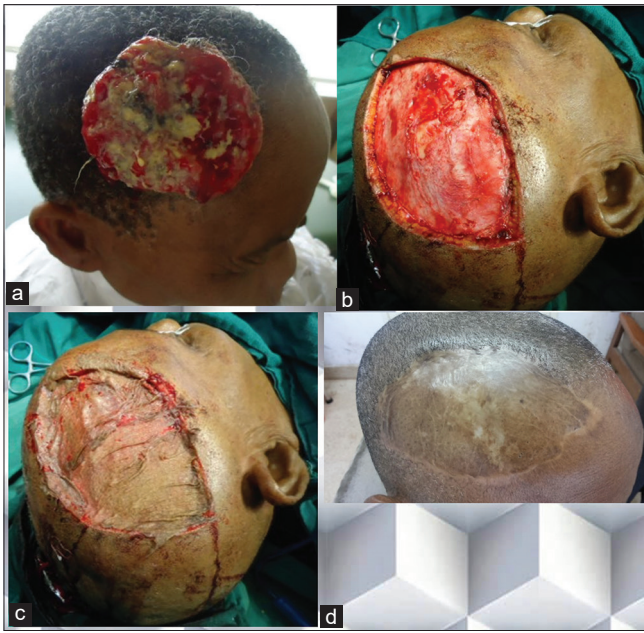


Figure 8: Scalp reconstruction with skin grafting after tumor excision. (a) Squamous cell carcinoma, (b) Tumor excised with pericranium intact, (c) Skin graft applied, (d) The grafted site a few months after

to cover the majority of the large scalp defects; however, we closed a few of them with SSGs [Figure 5]. Even in situations where pedicled flaps were utilized, we still had to employ SSG for the secondary defects. Other options for closing these large scalp defects are galeal flaps.

The crane principle is another important option in scalp defects that involved the hairless frontal area [Figure 9]. The principle involves raising part of the pedicled flap used in covering a defect and returning it to the secondary defect, leaving tissue on the defect that can then take SSG. It can be invaluable in the reconstruction of combined scalp and forehead defects. It was described by Todd Skoog as a method for scalp reconstruction;^[12] however, it was Millard who gave the procedure its name^[13] and explained the underlying physiology using animal studies.^[12]

Microvascular tissue is used for large and extensive defects. This has remained the preferred choice in most complex head and neck reconstructions. It has the advantage of providing well-vascularized tissue, where the scalp had been previously treated by radiotherapy.^[6,8] Alternatives to the use of free flaps include the O-Z flap, a 2-flap rotation flap that has been used successfully for large scalp defects,^[7] distant pedicled flaps,^[14,15] and radial forearm flap. We used the pedicled radial forearm flap for two of our patients who had large defects.

SCC was the most common cause of malignant scalp tumor (52.9%) in this study, followed by BCC, which comprised 41.2% of the tumors. In a study by Diop *et al.*^[16] in Dakar, Senegal, SCC (57%) was also the most common malignant tumor of the scalp, followed by BCC (21.4%), similar to the findings in this present study. Another similar finding was that of Costa *et al.*, in 2016^[8] in St. Louis, Missouri,

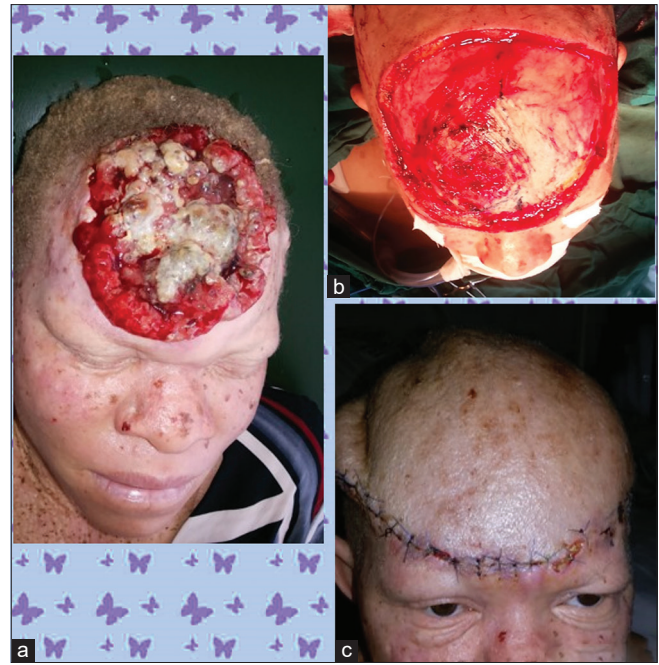

Figure 9: First-stage reconstruction of postexcision scalp defect using a local flap that would be replaced with a skin graft. (a) Tumor fixed to the skull, (b) Excision with removal outer table of skull, (c) Defect covered with local flap

United States, where SCC was also the most common cause of scalp tumor, followed by BCC. A study from Poland, however, reported that BCC was the most common histopathologic type of malignant scalp tumors, followed by SCC.^[17] In the study by Otoh *et al.*,^[18] in Northeastern Nigeria, all carcinomas combined constitute 55.6% of all scalp tumors, and they were not separated into SCC and BCC. Other malignant scalp tumors that were mentioned in the Dakar study include lymphoma, hidradenocarcinoma, and dermatofibrosarcoma of Darier–Ferrand.^[16] Scalp plexiform neurofibrosarcoma^[19] and scalp melanoma^[20] have also been reported in two Nigerian tertiary hospitals.

Complications noted in the series include partial skin graft loss in the recipient site and tumor recurrence in three patients. All the patients were followed up for at least one year. Two of the three patients with tumor recurrence had this at the regional lymph nodes (preauricular group), while the other had it at the primary site (scalp). These, notably, did not receive adjuvant radiotherapy postoperative by reason of lack of funds. The role of radiotherapy, however, remained difficult to assess from this limited series, particularly since a few patients who failed to receive adjuvant radiotherapy did not develop any recurrence within the follow-up period.

Limitations

There were limitations to this study. One of these is the small sample size, although it is comparable to the numbers in similar studies. Increasing the period of the study could have increased the sample. Another limitation is the short period of follow-up since all the patients were not followed up for one year.

CONCLUSION

Scalp reconstruction after oncological resection presents a peculiar esthetic challenge due to the hair-bearing skin of the scalp and the need to maintain the hairline. The use of local flaps from the scalp has remained the first and best option. For very large scalp defects, free flap through microvascular surgery is the preferred modality. Older techniques such as the crane principle and pedicled distant flaps have remained relevant even in this modern era. Skin grafting is also a good option, especially when used temporarily and subsequently excised with the aid of tissue expanders.

DECLARATION OF PATIENT CONSENT

The authors certify that they have obtained all appropriate patient consent forms. In the form, the patient(s) has/have given his/her/their consent for his/her/their images and other clinical information to be reported in the journal. The patients understand that their names and initials will not be published and due efforts will be made to conceal their identity, but anonymity cannot be guaranteed.

Financial support and sponsorship

Nil.

Conflicts of interest

There are no conflicts of interest.

REFERENCES

1. Prodinge CM, Koller J, Laimer M. Scalp tumors. *J Dtsch Dermatol Ges* 2018;16:730-53.
2. Boro S, Bannoth S, Rahman T, Das AK, Das A, Das K, *et al.* Patient reported outcomes of scalp and forehead reconstruction for defects following oncological resections (North-East Indian tertiary cancer Centre study). *Indian J Otolaryngol Head Neck Surg* 2022;74:449-55.
3. Tecce MG, Othman S, Mauch JT, Nathan S, Tilahun E, Broach RB, *et al.* Complex oncologic resection and reconstruction of the scalp: Predictors of morbidity and mortality. *Arch Craniofac Surg* 2020;21:229-36.
4. Jang HU, Choi YW. Scalp reconstruction: A 10-year experience. *Arch Craniofac Surg* 2020;21:237-43.
5. Begum UR, Karthikeyan G, Selvaraj A. Evolving a system of classification for scalp defects and methods of reconstruction. *Int J Sci Stud* 2019;7:14-8.
6. Ehrl D, Brueggemann A, Broer PN, Koban K, Giunta R, Thon N. Scalp reconstruction after malignant tumor resection: An analysis and algorithm. *J Neurol Surg B Skull Base* 2020;81:149-57.
7. Cao AC, Carey RM, Shah M, Chorath K, Brody RM, Cannady SB, *et al.* Use of the O-Z flap as an alternative to free tissue transfer for reconstruction of large scalp defects. *World J Otorhinolaryngol Head Neck Surg* 2022;8:355-60.
8. Costa DJ, Walen S, Varvares M, Walker R. Scalp rotation flap for reconstruction of complex soft tissue defects. *J Neurol Surg B Skull Base* 2016;77:32-7.
9. Bas S, Oner C, Eren HI, Hacikerim Karsidag S, Yilmaz A. Reconstruction of complex scalp defects in different locations: Suggestions for puzzle. *Sisli Etfal Hastan Tip Bul* 2021;55:349-58.
10. Christopoulos G, Deraje V, Mbaidjol Z, Kannan RY. The "snail flap": A rotation flap in scalp reconstruction. *Plast Reconstr Surg Glob Open* 2020;8:e2599.
11. Legbo JN, Shehu BB. Managing scalp defects in sub-Saharan Africa. *East Afr Med J* 2004;81:87-91.
12. Kadry HM, Taha AA. Crane principle revisited. *Plast Reconstr Surg Glob Open* 2020;8:e2741.
13. Lu Y, Chang KC, Chang CN, Chang DH. Reconstruction of a secondary scalp defect using the crane principle and a split-thickness skin graft. *BMC Surg* 2021;21:41.
14. Ranjan K, Venkataramu V, Achanti HP, Khemka S, Shenoy AM, Dandekar M. The role of pedicled latissimus dorsi flap in scalp defect reconstruction following tumour excision. *Indian J Otolaryngol Head Neck Surg* 2021;73:129-32.
15. Mahieu R, Colletti G, Bonomo P, Parrinello G, Iavarone A, Dolivet G, *et al.* Head and neck reconstruction with pedicled flaps in the free flap era. *Acta Otorhinolaryngol Ital* 2016;36:459-68.
16. Diop A, Diallo M, Ndiaye MT, Seck B, Diadie S, Diatta BA, *et al.* Epidemiological and anatomoclinical features of scalp tumors in black Africans. *Pan Afr Med J* 2019;34:98.
17. Chlebicka I, Stefaniak AA, Gawdzik A, Rygał A, Matusiak Ł, Szepletowski JC. Scalp lesions referred for surgical procedures: Single-center 5-year experience in Southwestern Poland. *In Vivo* 2020;34:2733-8.
18. Otoh EC, Johnson NW, Danfillo IS, Adeleke OA, Olasoji HA. Primary head and neck cancers in North Eastern Nigeria. *West Afr J Med* 2004;23:305-13.
19. Chukwuanukwu TO, Ukachukwu AK, Etukokwu KC, Afiadigwe EE, Apakama AI, Anyabolu AE, *et al.* Scalp plexiform neurofibrosarcoma with intrathoracic fibrosarcoma: A case report. *Cureus* 2022;14:e27853.
20. Zarami AB, Satumari NA, Ahmed M. Scalp melanoma diagnosed by fine needle aspiration cytology in a tertiary health center. *Case Rep Oncol Med* 2015;2015:605906.