

# Large Epidural Haematoma in an Infant Following a Minor Fall

Abass Oluwaseyi Ajayi<sup>1</sup>, Maryam Edun-Ajayi<sup>2</sup>

<sup>1</sup>Department of Surgery, Division of Neurosurgery, Ahmadu Bello University Teaching Hospital, <sup>2</sup>Department of Anaesthesia, Ahmadu Bello University Teaching Hospital, Zaria, Nigeria

## Abstract

Traumatic brain injury is a relatively rare occurrence in the paediatric population; among the paediatric population, infants are less affected than older children. Epidural haematoma (EDH) in children is also uncommon, and when it does occur, it rarely follows a minor mechanism. This article aims to report the diagnosis and operative management of an 8-month-old infant who presented with EDH following a minor fall and to review the current literature on this life-threatening condition. An 8-month-old female infant was admitted with altered consciousness associated with lucid interval and one episode of generalised tonic-clonic seizures. She had an admitting Glasgow Coma Score (GCS) of 12. A computerised tomography scan showed a large EDH necessitating surgical evacuation. The patient had an uneventful postoperative recovery, with Glasgow Outcome Score of 5 at discharge and 6-month follow-up. Due to the rare incidence, diagnostic and management challenges posed by EDH among infants, we have decided to share the operative management of a large EDH in an infant following minor trauma, using improvised instruments to add to the body of knowledge on this rare condition.

**Keywords:** Epidural haematoma, infant, operative

## INTRODUCTION

Epidural haematoma (EDH) in infants is a rare presentation in paediatric trauma. Although paediatric EDH accounts for between 2% and 4% of all cases of paediatric head injuries, infantile EDH is even rarer.<sup>[1]</sup> Due to the challenges of communication posed by infants and difficulties with clinical assessment, identification of head injury, especially following minor trauma, is difficult for them. Unconsciousness might be confused as a state of sleep by the caregivers, delaying presentation. Choice of an appropriate assessment tool for consciousness, use of computerised tomography (CT) scan with its attendant risk in children, and finally, decision-making for nonoperative or operative treatment and appropriate tools for surgery are challenges that should be considered while managing these patients.<sup>[1-4]</sup>

We, therefore, present the case of an infant who presented with massive EDH following a minor fall and review the current literature on this condition.

## CASE REPORT

An 8-month-old female infant who presented 6 h posttrauma with altered consciousness. She lost consciousness immediately

following the fall, regained full consciousness for 3 h, then lapsed into unconsciousness again. She also had one episode of tonic-clonic seizures lasting 5 min which spontaneously aborted, following a fall from a height of 50 cm from a couch while playing in the sitting room. She had no bleeding from craniofacial orifices, vomiting, or limb weakness and non-accidental trauma, namely, symmetrical bruises, previous scars, unexplained fractures, etc.

Postresuscitation GCS (modified) was E4 V3 M5 12/15. She had anisocoria with right pupil 5 mm sluggishly reactive and left 3 mm reactive, she had right upper lid ptosis. There were no features of other cranial nerve palsies. Vitals and other systemic examinations were normal.

Packed cell volume was 31% serum electrolytes and creatinine was normal.

**Address for correspondence:** Dr. Abass Oluwaseyi Ajayi, Department of Surgery, Division of Neurosurgery, Ahmadu Bello University Teaching Hospital, Zaria, Nigeria.  
E-mail: abassajayi@gmail.com

This is an open access journal, and articles are distributed under the terms of the Creative Commons Attribution-NonCommercial-ShareAlike 4.0 License, which allows others to remix, tweak, and build upon the work non-commercially, as long as appropriate credit is given and the new creations are licensed under the identical terms.

**For reprints contact:** WKHLRPMedknow\_reprints@wolterskluwer.com

**How to cite this article:** Ajayi AO, Edun-Ajayi M. Large epidural haematoma in an infant following a minor fall. *Niger J Med* 2023;32:219-21.

**Submitted:** 28-Jan-2023

**Revised:** 27-Mar-2023

**Accepted:** 14-Apr-2023

**Published:** 14-Jul-2023

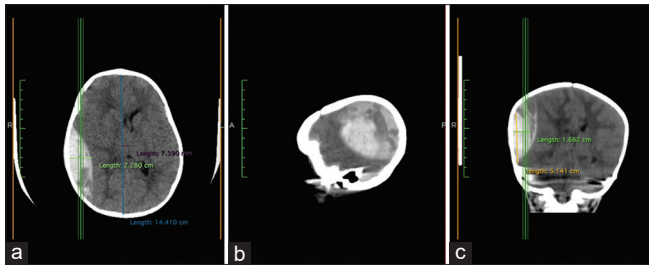
### Access this article online

Quick Response Code:



**Website:**  
<http://journals.lww.com/NJOM>

**DOI:**  
10.4103/NJM.NJM\_10\_23



**Figure 1:** The CT scan described above (a) Axial cut (b) sagittal (c) coronal. CT: Computerised tomography

### Imaging findings

CT Scan [Figure 1. Above] revealed a massive right parietotemporal epidural haematoma (22mm thick) with 7mm midline shift. There was also obliteration of the right ambient cistern, and diffuse cerebral edema.

### Intraoperative findings

She had a right parietal subperiosteal haematoma [Figure 2a] overlying a 4 cm linear parietal skull fracture. Burr holes were made with size 22 blades mounted on Bard-Parker handles and craniotomy [Figure 2b] was done using 1 mm Kerrison's rongeurs. Approximately 80 ml of EDH [Figure 2c] was evacuated and dura tenting was done. There was no obvious dural tear and underlying brain was pulsating post evacuation

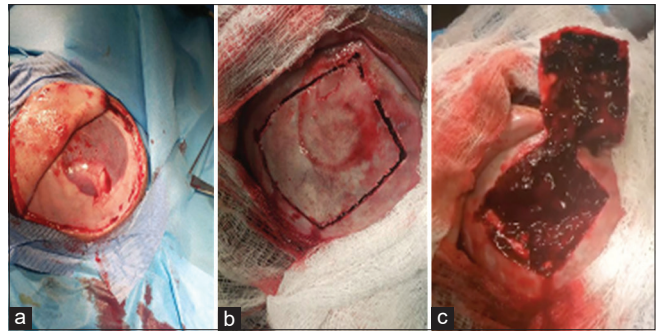
She was discharged on 5<sup>th</sup> postoperative day following a good postoperative recovery, with GCS was 15 at discharge and complete resolution of symptoms. The patient was followed up for 6-months post-discharge and has remained stable with a Glasgow Outcome Score of 5 and achieving all her milestones.

### DISCUSSION

Traumatic brain injury in children is a potentially life-threatening condition; in addition to this risk is the fact that it poses a diagnostic challenge because symptoms may be nonspecific and vary depending on the age and severity of the injury.<sup>[1,2,5,6]</sup>

Paediatric head injury accounts for a small percentage of head trauma, a US study puts the incidence of paediatric TBI at 1.5 million per year,<sup>[7]</sup> and EDHs account for only 1%–4% of these.<sup>[5]</sup> Of the cases of EDH, infantile EDHs are quite rare.<sup>[3,4,8]</sup> A study by Ciurea *et al.* showed no male–female predilection and an average age of 10 years, the most common site was temporoparietal, as in our case report and fall accounted for the most common etiology.<sup>[2]</sup>

The most common clinical features include excessive crying, somnolence, and seizures, and others include cephalohaematoma, limb weakness, etc.<sup>[2,4,7,9,10]</sup> The classical lucid interval is uncommon in babies and, unlike in our patient, usually associated with poor prognosis.<sup>[4]</sup> Pallor is an important clinical finding that must be sought in these babies due to their low blood volume and risk of accumulation of blood in a cephalohaematoma or the epidural bleed.<sup>[2]</sup>



**Figure 2:** (a) A right parietal subperiosteal haematoma overlying a 4 cm linear parietal fracture, (b) The craniotomy and evacuated subperiosteal haematoma (c) The large epidural haematoma of approximately 80 ml

EDHs may occur following minor falls from heights <1m, as in the index case, this may be quite misleading and may delay diagnosis.<sup>[2,4,5]</sup> Other etiologies include road traffic crashes and nonaccidental injury. The paediatric Glasgow Coma Score at presentation has been proven to predict the possible outcome, so has the traumatic infant neurological (TIN) score, in the series by Ciurea *et al.*, a TIN score of 10 was associated with a 100% risk of mortality.

CT scan is the appropriate diagnostic tool in this group of patients, notwithstanding the risk of radiation and possible requirement of sedation during the acquisition of images and other confounding factors affecting CT use in children. Various protocols have been drawn by various countries to attempt to reduce the amount of unnecessary CT scans done the Canadian Assessment of Tomography for Childhood Head Injury, Canada, the children's head injury algorithm for the prediction of important clinical events from the UK, and the prediction rule for the identification of children at very low risk of clinically important traumatic brain injury developed by the Paediatric Emergency Care Applied Research Network from the US.<sup>[9]</sup>

Treatment options could be nonoperative or operative, the choice of which depends on the clinical state, CT finding, and surgeons' preference. Various studies have strongly recommended urgent surgical management for patients in a coma (GCS score <9) with anisocoria and for those with a haematoma larger than 30 cm<sup>[1]</sup> in size, regardless of the patient's Glasgow Coma Scale (GCS) score.<sup>[11–14]</sup> Surgical options include a craniotomy and clot evacuation, and in some cases, needle aspiration.<sup>[2,3,6,8,15]</sup>

The outcome depends on the severity of the injury, timing of presentation, and intervention. Generally, the outcome in children is better than adults.<sup>[1,11–14]</sup>

### CONCLUSION

EDH is a rare, life-threatening condition in the paediatric age group with diagnostic challenges. Early and prompt evaluation and appropriate decision-making are important for a favorable outcome. The use of improvised instruments in the absence

of a paediatric craniotomy is encouraged in resource-poor settings to promote global surgery.

### Declaration of patient consent

The authors certify that they have obtained all appropriate patient consent forms. In the form, the patient(s) has/have given his/her/their consent for his/her/their images and other clinical information to be reported in the journal. The patients understand that their names and initials will not be published and due efforts will be made to conceal their identity, but anonymity cannot be guaranteed.

### Financial support and sponsorship

Nil.

### Conflicts of interest

There are no conflicts of interest.

## REFERENCES

1. Baş NS, Karacan M, Doruk E, Karagoz Guzey F. Management of traumatic epidural haematoma in infants younger than one year: 50 cases – Single center experience. *Pediatr Neurosurg* 2021;56:213-20.
2. Ciurea AV, Tascu A, Brehar FM, Nuteanu L, Rizea R. A life threatening problem in infants: Supratentorial epidural haematoma. *J Med Life* 2009;2:191-5.
3. Heyman R, Heckly A, Magagi J, Pladys P, Hamlat A. Intracranial epidural haematoma in newborn infants: Clinical study of 15 cases. *Neurosurgery* 2005;57:924-9.
4. Ciurea AV, Kapsalaki EZ, Coman TC, Roberts JL, Robinson JS 3<sup>rd</sup>, Tascu A, *et al.* Supratentorial epidural haematoma of traumatic etiology in infants. *Childs Nerv Syst* 2007;23:335-41.
5. Binder H, Majdan M, Tiefenboeck TM, Fochtmann A, Michel M, Hajdu S, *et al.* Management and outcome of traumatic epidural haematoma in 41 infants and children from a single centre. *Orthop Traumatol Surg Res* 2016;102:769-74.
6. Smets KJ, Vanhauwaert D. Treatment of cranial epidural haematoma in a neonate by needle aspiration of a communicating cephalhaematoma. *Eur J Pediatr* 2010;169:617-9.
7. Fische JN, Luberti AA, Master CL, Robinson RL, Grady MF, Arbogast KB, *et al.* After-hours call centre triage of paediatric head injury: Outcomes after a concussion initiative. *Pediatr Emerg Care* 2016;32:149-53.
8. Josephsen JB, Kemp J, Elbabaa SK, Al-Hosni M. Life-threatening neonatal epidural haematoma caused by precipitous vaginal delivery. *Am J Case Rep* 2015;16:50-2.
9. Babl FE, Lyttle MD, Bressan S, Borland M, Phillips N, Kochar A, *et al.* A prospective observational study to assess the diagnostic accuracy of clinical decision rules for children presenting to emergency departments after head injuries (protocol): The Australasian Paediatric Head Injury Rules Study (APHIRST). *BMC Pediatr* 2014;14:148.
10. Figaji AA. Paediatric head injury-an opportunity to make a difference in the global burden of disease. *Childs Nerv Syst* 2017;33:1649-50.
11. Teichert JH, Rosales PR Jr., Lopes PB, Enéas LV, da Rocha TS. Extradural haematoma in children: Case series of 33 patients. *Pediatr Neurosurg* 2012;48:216-20.
12. Jamous MA, Abdel Aziz H, Al Kaisy F, Eloqayli H, Azab M, Al-Jarrah M. Conservative management of acute epidural haematoma in a paediatric age group. *Pediatr Neurosurg* 2009;45:181-4.
13. Emejulu JK, Uche EO, Nwankwo EU. The challenges of managing acute extradural haematoma in a Nigerian neurosurgical center--still a long way to go. *World Neurosurg* 2014;82:969-73.
14. Mageri R, Anderson DG, Graziano F, Meccio F, Visocchi M, Iacopino DG. Conservative versus surgical management of post-traumatic epidural haematoma: A case and review of literature. *Am J Case Rep* 2015;16:811-7.
15. Bartkowska-Śniatkowska A, Jończyk-Potoczna K, Zielińska M, Rosada-Kurasińska J. Adverse reaction to ceftriaxone in a 28-day-old infant undergoing urgent craniotomy due to epidural haematoma: Review of neonatal biliary pseudolithiasis. *Ther Clin Risk Manag* 2015;11:1035-41.