

# Double Midgut Volvulus in Pregnancy: A Case Report of a Rare Intestinal Obstruction

Aishat Ahmed<sup>1</sup>, Henry Emanashi Onyebaushi<sup>2</sup>, Wada Philips Sani<sup>1</sup>, Lazarus Ameh<sup>1</sup>, Bilal Sulaiman<sup>1</sup>

Departments of <sup>1</sup>Obstetrics and Gynaecology and <sup>2</sup>Surgery, University of Abuja Teaching Hospital, Abuja, Nigeria

## Abstract

Intestinal obstruction secondary to volvulus is uncommon in pregnancy. Women with volvulus in pregnancy may present with vomiting, epigastric pain, and constipations which may mimic physiological changes in pregnancy or other common disorders such as malaria in pregnancy. In addition, there may be challenges with investigations such as ultrasound, X-ray, and magnetic resonance imaging which may not be readily available in low-resource settings, thereby further delaying the diagnosis. We report the case of a young woman who presented with epigastric pain and abdominal distention at 36-week gestational age. Urgent ultrasound scan revealed a viable gestation at 35 weeks with grossly distended bowels and increased peristalsis. A diagnosis of intestinal obstruction in pregnancy was made. She had an exploratory laparotomy and emergency Caesarean section. She was delivered of a live female baby and was found to have fibrous adhesions between a segment of the terminal ileum, the uterus and the right appendages, the terminal ileum and proximal jejunum were also twisted, respectively, and a strip segment of ileum was gangrenous. Adhesiolysis, detorsion of the two volvulus, and resection and anastomosis of the bowel were done. Ten-day post exploration, she developed a complete wound dehiscence which was immediately repaired and she was eventually discharged home after eight days. She was seen at the postnatal and surgical outpatient clinics on two occasions at two and six-week postoperation, respectively, with no complaint and her wound had healed. She was discharged from the outpatient clinic by the 6<sup>th</sup> week post surgery.

**Keywords:** Acute abdomen, double midgut volvulus, intestinal obstruction, pregnancy

## INTRODUCTION

Volvulus occurs when there is an abnormal twisting of a segment of the intestine around its own mesentery.<sup>[1]</sup> It is a common cause of bowel obstruction in the non obstetric population but rarely occurs in pregnancy. The incidence of intestinal obstruction in pregnancy is reported to be 1:1500–1:66431 deliveries.<sup>[2]</sup> Intestinal obstruction is usually life threatening and is associated with high maternal and fetal morbidity and mortality.<sup>[2]</sup> Some of the common causes of intestinal obstruction in pregnancy include appendicitis, intussusception, adhesions, malignancies, and volvulus.<sup>[2-4]</sup> Volvulus can occur in most sites of the gastrointestinal tract; however, midgut volvulus accounts for 25% of all cases in the general population while it occurs in about 3% of pregnancies.<sup>[1]</sup> Some of the risk factors for volvulus include advanced age, high-fiber diet, medications altering intestinal motility, associated neurological disease with altered intestinal motility, previous surgeries, constipation, pregnancy, diabetes mellitus, and associated neurological diseases such as

dementia and schizophrenia.<sup>[5,6]</sup> Due to relaxin, produced in pregnancy and upward displacement of the bowel by the gravid uterus, there is decreased bowel peristalsis and a possible malrotation and eventual volvulus.<sup>[1]</sup> Its nonspecific symptoms in pregnancy often lead to delayed presentation and missed diagnosis.<sup>[2]</sup> A high index of suspicion together with the use of modern imaging techniques and prompt surgical interventions is necessary to prevent a catastrophic outcome.<sup>[3]</sup>

In the past 30 years, only few cases of midgut volvulus in pregnancy were reported.<sup>[1]</sup> Although there are cases of intestinal obstruction in pregnancy reported in Nigeria,<sup>[7-9]</sup> literature search did not reveal any report of midgut volvulus in

**Address for correspondence:** Dr. Bilal Sulaiman,  
Department of Obstetrics and Gynaecology, University of Abuja Teaching  
Hospital, Abuja, Nigeria.  
E-mail: sulaimanbilal2@gmail.com

This is an open access journal, and articles are distributed under the terms of the Creative Commons Attribution-NonCommercial-ShareAlike 4.0 License, which allows others to remix, tweak, and build upon the work non-commercially, as long as appropriate credit is given and the new creations are licensed under the identical terms.

**For reprints contact:** WKHLRPMedknow\_reprints@wolterskluwer.com

**How to cite this article:** Ahmed A, Onyebaushi HE, Sani WP, Ameh L, Sulaiman B. Double midgut volvulus in pregnancy: A case report of a rare intestinal obstruction. *Niger J Med* 2023;32:215-8.

**Submitted:** 30-Dec-2022

**Revised:** 03-Mar-2023

**Accepted:** 31-Mar-2023

**Published:** 14-Jul-2023

### Access this article online

Quick Response Code:



**Website:**  
<http://journals.lww.com/NJOM>

**DOI:**  
10.4103/NJM.NJM\_134\_22

pregnancy. Therefore, we present this case to draw the attention of practicing physicians and surgeons to the possibility of double midgut volvulus in pregnancy and some of the challenges associated with its management.

## CASE REPORT

A 28-year-old gravida 3 para 2 + 0 (2 alive) woman at 36 weeks of gestation was referred to our hospital as a case of suspected intestinal obstruction in pregnancy. She complained of epigastric pain for seven days and abdominal distention for five days. The epigastric pain started gradually and later became generalised. It was colicky and non-radiating; there was no relieving or aggravating factor. She was not a known peptic ulcer disease patient. The abdominal distension started two days after the epigastric pain. It was generalised and associated with pain. There was anorexia, constipation, and vomiting during the six days before presentation. The vomitus was projectile, of large volume, non bloody, initially containing recently ingested meal but subsequently appeared to contain fecal matter. She vomited 8–10 times per day before presentation. She booked at a health facility with no adverse event until the onset of present symptoms. She was regular on her antenatal care visits and routine medications. There was no prior history of surgery and her previous pregnancies were uneventful.

Examination at presentation showed that she was afebrile (36.8°C), not pale, anicteric, but in respiratory distress with flaring of alar nasi and some dehydration. The partial pressure of oxygen ranged between 95% and 97% in room air. The pulse rate was 104 beats/min, regular and of moderate volume, blood pressure was 110/70 mmHg, and the heart sounds were first and second only. Her respiratory rate was 34 cycles/min and the chest was clear clinically.

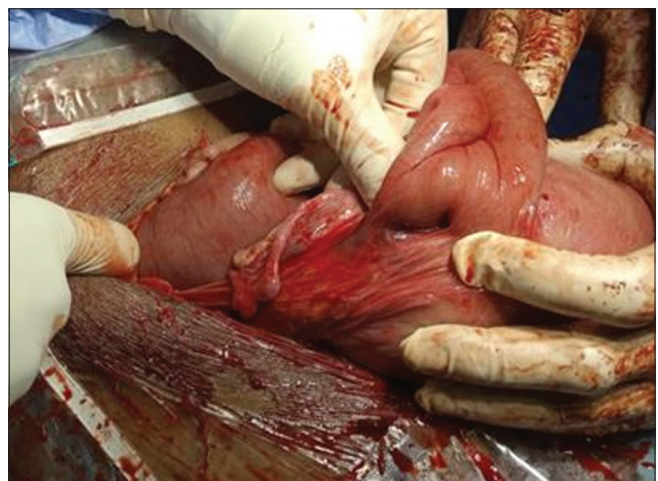
The abdomen was grossly distended; there was guarding, rebound tenderness with difficulty in palpating intraabdominal organs due to marked tenderness. The bowel sounds were hyperactive while percussion was not performed due to marked tenderness.

A diagnosis of intestinal obstruction in pregnancy was made. Immediate resuscitation was commenced. She was started on nil per oral. A urethral catheter and nasogastric (NG) tube were passed for urine output monitoring and gastric decompression, respectively. Fifty milliliters of concentrated urine was drained through the urine bag while the NG tube yielded two liters of bilious effluent. Samples were taken for investigations and results were as follows: packed cell volume of 33% and haemoglobin concentration was 11 g/dl, the white blood cell count was  $13.4 \times 10^9/L$ , while the platelet count was  $180 \times 10^9/L$ . The serum urea, electrolyte, and creatinine were within the normal limits. The serological screenings for hepatitis B and HIV were both negative and the urinalysis was normal. Ultrasound scan demonstrated fluid-filled distended bowel loops with increased abdominal gas and bowel peristalsis with no ascites, the liver, both

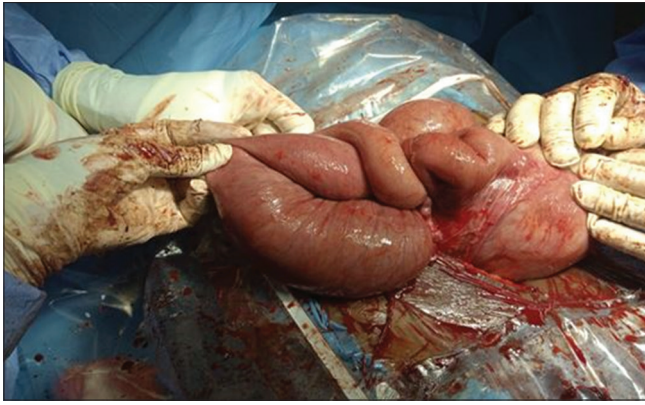
kidneys, spleen, pancreas, and urinary bladder were within the normal limits. There was a singleton intrauterine live fetus in longitudinal lie with breech presentation at 35 weeks and 3 days. The estimated fetal weight was 2.4 kg, the liquor volume was adequate, and the placenta was posteriorly located. The conclusion of the ultrasound scan was that of features of intestinal obstruction and a viable singleton fetus at 35 weeks and 3 days. Prophylactic intravenous antibiotics were commenced after the initial investigation samples were taken. She was co-managed with the surgical team as a case of intestinal obstruction in pregnancy. She was worked up for an emergency exploratory laparotomy and Caesarean section.

She had an exploratory laparotomy and emergency Caesarean section. First, emergency Caesarean section was done and she was delivered a female baby with nuchal cord, by the breech with APGAR scores of six and eight in the first and fifth minutes, respectively. After the Caesarean section, the abdominal cavity was explored and the following were found: fibrous adhesions between 10-cm segment of the terminal ileum (50 cm from the ileocecal junction) and the uterus, right fallopian tube, and broad ligament. The terminal ileum was twisted approximately 270° on its mesentery near the point of adhesions [Figures 1 and 2]. There was also twisting of the proximal jejunum and ileum (a second volvulus) at 150 cm from the ileocecal junction. There was a strip segment of gangrenous ileum in the volvulus. While attempting to untwist the second volvulus, the ileum was perforated [Figure 3] and three liters of fecal matter was evacuated from the site of perforation. She had adhesiolysis, detorsion of small bowel volvulus with resection, and anastomosis and repair of ileal perforation. Peritoneal lavage was done with warm saline and abdominal drain was inserted. The estimated blood loss was 1.7 L and she had two units of blood transfused intraoperatively.

She developed high-grade fever that ranged from 38.5°C to 39.7°C, with associated restless and irrational talk, 72 h postoperatively. She also developed purulent discharge from



**Figure 1:** Twisted and distended bowel adhered to the right lateral uterine wall



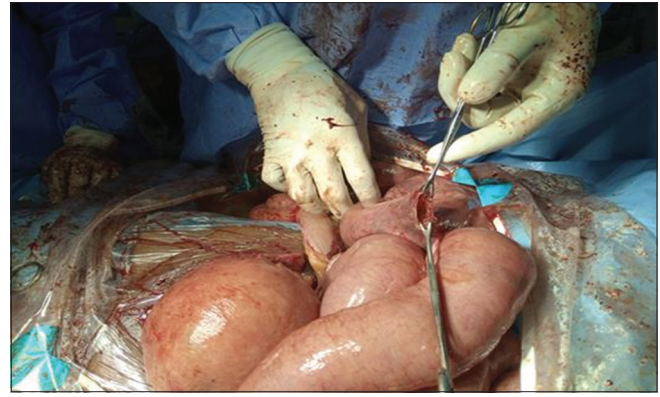**Figure 2:** Adhered and twisted bowel with proximal distention

the drain and operation site on the sixth-day postoperation. Alternate sutures were removed and she had complete wound dehiscence on day 10 postoperation following removal of the remaining sutures. She was resuscitated with oxygen and intravenous fluids and subsequently had an emergency laparotomy. Pelvic abscess was discovered at laparotomy but uterine and intestinal sutures were intact. She had a lavage of the peritoneal cavity and closure of the abdomen with tension sutures. Postoperatively, her clinical condition was satisfactory and she was discharged home eight days after the second surgery. Two-week postdischarge, she presented to the postnatal and surgical outpatient clinics with no complaint. The wound was well apposed, clean, and dry. She was then seen four weeks later with no complaint. There was no problem with the surgical scar. Her baby was immunised to date and she was discharged from the postnatal clinic and referred to family planning clinic.

## DISCUSSION

Intestinal obstruction in pregnancy was first reported by Houston in 1830 and is still uncommon. The most common causes are adhesions (60%), volvulus (25%), intussusception (5%), carcinomas (3.5%), and hernia (1.5%). Cases of intestinal obstruction in pregnancy have been reported in Nigeria; most of them are due to intussusception.<sup>[7-9]</sup> No case of volvulus in pregnancy is reported in Nigeria.

Intestinal volvulus usually presents in the second and third trimesters.<sup>[1]</sup> This is because the rapidly enlarging gravid uterus distorts the anatomical location of the intra-abdominal viscera mainly between 16–20 and 32–36 weeks of gestational life.<sup>[10-13]</sup> Furthermore, relaxin, a hormone which is released during pregnancy increases tissue pliability and decreases motility of the gastrointestinal tract.<sup>[1]</sup> Both of these factors when combined in individuals already susceptible to volvulus predispose to midgut volvulus in pregnancy. Despite this higher propensity in the third trimester, as in the case presented, there have been reports of this complication developing in early pregnancy as well as the puerperium. Sherer and Abulafia described a case of postpartum volvulus after caesarean delivery.<sup>[14]</sup>



**Figure 3:** Perforated bowel noticed during untwisting of the second volvulus

The clinical presentation of midgut volvulus in pregnancy usually consists of a triad of generalised abdominal pain, bilious vomiting, and constipation.<sup>[1]</sup> There is usually an overlap with common symptoms during pregnancy which together with its low incidence often leads to delay in diagnosis and definitive treatment.<sup>[1]</sup> Our patient presented with a triad of complaints and symptoms.

Prompt diagnosis relies on sound clinical assessment (history and examination) and effective use of laboratory and radiological investigations. A hesitation to pursue radiological investigations in pregnancy has been cited as a major barrier in achieving a definite diagnosis.<sup>[1]</sup>

Radiological investigations such as ultrasonography and magnetic resonance imaging (MRI) have been reported to be safe in pregnancy with no associated risk to the fetus and as such can be used to aid diagnosis.<sup>[15]</sup> Ultrasound and MRI can show dilated loops of bowel and the characteristic “whirlpool sign” demonstrating mesenteric torsion in addition to closed loop obstruction with transition points.<sup>[15,16]</sup> Ultrasonography is widely used to aid the diagnosis of intestinal obstruction although its accuracy is operator dependent. Furthermore, the ultrasound rays are affected by air or gas within the bowel. Our patient presented with distended bowel due to obstruction. This may have affected the diagnosis made by the radiologist, in the case presented. Our patient did not have MRI because of its unavailability in our facility, cost, and time factors.

Other modalities that rely on ionising radiation such as abdominal X-ray and computed tomography have also been used in the diagnosis of volvulus.<sup>[16]</sup> With an abdominal X-ray, the evidence of dilated small bowel with multiple air-fluid levels should heighten the suspicion of intestinal obstruction. It is said to be confirmatory if a “bent inner tube” sign or a “coffee bean” sign are seen.<sup>[15,16]</sup> Despite being the most readily available form of radiological imaging, abdominal X-ray is seldom used due to the fear of radiation exposure to the fetus.<sup>[1]</sup> However, evidence abounds that the amount of radiation exposure to the fetus is negligible (0.00007 rad).<sup>[16]</sup> Therefore, when the benefit outweighs the risk, an X-ray can be done on pregnant woman.



The management of midgut volvulus in pregnancy involves a multidisciplinary approach. The basis of therapy is early surgical intervention after resuscitation. Surgery should be performed through a midline vertical laparotomy to have sufficient exposure because of the enlarged uterus.<sup>[17]</sup> The entire bowel should be examined for intestinal viability and other areas of obstruction.<sup>[17]</sup> Surgical interventions may include adhesiolysis, detorsion, and segmental resection with anastomosis. If there are areas of gangrene, resection of such segments either as primary or as two-stage procedure is recommended depending on the patient's health status.<sup>[17]</sup> Short gut syndrome is a recognised complication of extensive bowel resection, in which the patient would require life-long total parenteral nutrition with associated significant short- and long-term morbidity.<sup>[1]</sup>

Other maternal complications include strangulation, gangrene, perforation, peritonitis, sepsis, and recurrent volvulus.<sup>[18]</sup> While fetal complications include, preterm delivery, birth asphyxia, neonatal sepsis, and intrauterine fetal death.<sup>[18]</sup> The mortality rate of women with midgut volvulus in pregnancy is significantly higher (3–15%) when compared to the general population. It is a surgical emergency and if not diagnosed early carries a high mortality rate for both mother (6%–20%) and fetus (20%–26%).<sup>[18,19]</sup>

Intestinal volvulus can be managed conservatively in cases with mild-to-moderate symptoms, especially if it occurs in early gestation or remote from term. In severe cases, exploratory laparotomy with or without Caesarean section can be done to save the life of the mother and her fetus. Caesarean section was done in the case presented because the pregnancy has reached viability with no added benefit of continuing the pregnancy in the face of potential complications from the volvulus. Our patient suffered complete wound dehiscence despite the antibiotics and blood transfusion she received. This could be prevented with adequate peritoneal lavage and use of potent antibiotics. The dehiscence was immediately repaired with tension sutures and the baby did not suffer any complication.

Midgut volvulus in pregnancy is a rare and difficult-to-diagnose clinical entity. It is associated with high morbidity and mortality, both for the mother and fetus, because of delayed diagnosis. A high index of clinical suspicion is required in pregnant women with signs and symptoms of bowel obstructions. Early diagnosis and timely surgical intervention in a multidisciplinary manner are necessary to minimize the maternal and fetal morbidity and mortality.

### Declaration of patient consent

The authors certify that they have obtained all appropriate patient consent forms. In the form the patient(s) has/have given his/her/their consent for his/her/their images and other clinical information to be reported in the journal. The patients understand that their names and initials will not be published

and due efforts will be made to conceal their identity, but anonymity cannot be guaranteed.

### Financial support and sponsorship

Nil.

### Conflicts of interest

There are no conflicts of interest.

### REFERENCES

- Chong E, Liu DS, Strugnelli N, Rajagopal V, Mori KK. Midgut Volvulus: A rare but fatal cause of abdominal pain in pregnancy-how can we diagnose and prevent mortality? *Obstet and Gynaecol Int* 2020;2185290. Available at: <https://doi.org/10.1155/2020/2185290>. [Last accessed on 2022 Dec 02].
- Lodhia J, Magoma J, Tendai J, Msuya D, Suleiman J, Chilonga K. Sigmoid volvulus in pregnancy: A case report. *J Med Case Rep* 2021;15:554.
- Serafeimidis C, Waqainabete I, Creaton A, Vakamacawai E, Kumar R. Sigmoid volvulus in pregnancy: Case report and review of literature. *Clin Case Rep* 2016;4:759-61.
- Kolusari A, Kurdoglu M, Adali E, Yildizhan R, Sahin HG, Kotan C. Sigmoid volvulus in pregnancy and puerperium: A case series. *Cases J* 2009;2:9275.
- Wismayer R. Factors influencing outcome of sigmoid volvulus in Northern Uganda: A prospective observational study. *East Cent Afr J Surg* 2016;12:85-97.
- Surriah MH, Bakkour AM. The clinical study and surgical management of the sigmoid volvulus. *J Arab Board Health Spec* 2019;20:29-36.
- Abdul MA, Yusufu LM, Haggai D. Intussusception in pregnancy: Report of a case. *Niger J Surg Res* 2004;6:61-3.
- Osime OC, Onakewhor J, Irowa OO. Intussusception in pregnancy – A rarely considered diagnosis. *Afr J Reprod Health* 2010;14:145-8.
- Udigwe GO, Eleje GU, Ihekwoaba EC, Udegbonam OI, Egeonu RO, Okwuosa AO. Acute intestinal obstruction complicating abdominal pregnancy: Conservative management and successful outcome. *Case Reports Obstet Gynecol* 2016;2576280. Available at: <https://doi.org/10.1155/2016/2576280>. [Last accessed on 2023 Feb 03].
- Connolly MM, Unti JA, Nora PF. Bowel obstruction in pregnancy. *Surg Clin North Am* 1995;75:101-13.
- Biswas S, Gray KD, Cotton BA. Intestinal obstruction in pregnancy: A case of small bowel volvulus and review of the literature. *Am Surg* 2006;72:1218-21.
- Singla SL, Kadian YS, Goyal A, Sharma U, Kadian N. Caecal volvulus in pregnancy: Is delay in diagnosis avoidable? *Asian J Surg* 2005;28:52-4.
- Cong Q, Li X, Ye X, Sun L, Jiang W, Han Z, *et al.* Small bowel volvulus in mid and late pregnancy: Can early diagnosis be established to avoid catastrophic outcomes? *Int J Clin Exp Med* 2014;7:4538-43.
- Sherer DM, Abulafia O. Postcaesarean small bowel volvulus. Case report and review of the literature. *Gynecol Obstet Invest* 2001;51:69-72.
- Kouki S, Fares A, Alard S. MRI whirlpool sign in midgut volvulus with malrotation in pregnancy. *JBR-BTR* 2013;96:360-1.
- Yang Q, Zhao F, Qi J, Su L. The comparison of accuracy and practicability between ultrasound and spiral CT in the diagnosis of intestinal obstruction: A protocol for systematic review and meta-analysis. *Medicine (Baltimore)* 2021;100:e23631.
- Mattsson S, Leide-Svegborn S, Andersson M. X-ray and molecular imaging during pregnancy and breastfeeding-when should we be worried? *Radiat Prot Dosimetry* 2021;195:339-48.
- Khan MR, Ur Rehman S. Sigmoid volvulus in pregnancy and puerperium: A surgical and obstetric catastrophe. Report of a case and review of the world literature. *World J Emerg Surg* 2012;7:10.
- Webster PJ, Bailey MA, Wilson J, Burke DA. Small bowel obstruction in pregnancy is a complex surgical problem with a high risk of fetal loss. *Ann R Coll Surg Engl* 2015;97:339-44.