

# Anterior Segment and Ocular Adnexal Lesions in Patients with Human Immunodeficiency Virus Infection and Acquired Immunodeficiency Syndrome at a Tertiary Hospital in Southwestern Nigeria

Yewande Olunmi Babalola<sup>1</sup>

<sup>1</sup>Department of Ophthalmology, University of Ibadan/University College Hospital, Ibadan, Nigeria

## Abstract

**Background:** Ocular manifestation of human immunodeficiency virus and acquired immunodeficiency syndrome (HIV/AIDS) affects various ocular structures including the anterior segment and ocular adnexae and may be a cause of ocular morbidity. The aim of the study is to determine the pattern of lesions affecting the anterior segment and ocular adnexae in patients diagnosed with HIV/AIDS whether on highly active antiretroviral therapy or not and confirmed positive for retroviral disease by western blot attending an antiretroviral therapy clinic in Southwestern Nigeria. It is a prospective, cross-sectional study on anterior segment and ocular adnexae lesions in patients with HIV/AIDS. **Materials and Methods:** A total of 318 consecutive patients with the confirmation of a diagnosis of HIV/AIDS attending the antiretroviral therapy clinic within the study period from 2009 to 2010 had visual acuity evaluation, a detailed ocular examination by slit-lamp biomicroscopy, and binocular indirect ophthalmoscopy. The data generated were analysed using SPSS (Statistical Package for the Social Sciences) version 16. Ethical clearance was obtained from the hospital research ethics committee. **Results:** Two hundred and ninety-five (92.8%) patients of the 318 recruited had anterior segment manifestations, whereas ocular adnexal lesions were present in 134 (42.1%) patients. Multiple ocular pathology of the anterior segment and ocular adnexal was present in some of the respondents recruited. There were more female respondents. One hundred and twenty-three patients (38.7%) recruited for the study were in the 40–49 years of age group with a mean age of 47.2 years (SD = 9.42 years). The most common anterior segment lesion was corneal opacity in 18 patients (5.6%), and the most common ocular adnexal lesion was pingueculum in 56 respondents (17.6%). Other HIV/AIDS-associated adnexal lesions present include hypertrichosis in 25 patients (7.9%), herpes zoster ophthalmicus (HZO) in 13 (4.1%), and squamous cell carcinoma of the conjunctiva in 4 (1.3%) patients. The most common HIV-associated anterior segment pathology was HZO-associated keratouveitis seen in four patients (1.3%) and herpes simplex keratitis in one patient (0.3%). Conjunctival microangiopathy was the most common HIV-associated ocular adnexal lesion. The relationship between viral load values and lesions involving both anterior segment and ocular adnexal disease was statistically significant as these patients tended to have higher viral loads when compared with those without lesions ( $P < 0.05$ ). **Conclusion:** Anterior segment and ocular adnexal lesions were frequent in patients with HIV/AIDS attending a tertiary health institution in urban Nigeria. HIV/AIDS-defining ocular illnesses including HZO, conjunctival microangiopathy, and ocular surface squamous cell neoplasia are not uncommon in these patients. Potentially debilitating ocular disorders may be avoided by instituting periodic ocular examinations.

**Keywords:** Anterior segment, conjunctival microangiopathy, corneal opacity, highly active antiretroviral therapy, human immunodeficiency virus and acquired immunodeficiency syndrome, hypertrichosis, keratouveitis, ocular adnexa

## INTRODUCTION

Human immunodeficiency virus and acquired immunodeficiency syndrome (HIV/AIDS) remains of major public health importance since its discovery in 1981.<sup>[1]</sup> Worldwide, 37.7 million are presently living with HIV/AIDS, of which 20.6

**Address for correspondence:** Dr. Yewande Olunmi Babalola, Department of Ophthalmology, University of Ibadan/University College Hospital, Ibadan, Nigeria. E-mail: yewandeb@gmail.com

This is an open access journal, and articles are distributed under the terms of the Creative Commons Attribution-NonCommercial-ShareAlike 4.0 License, which allows others to remix, tweak, and build upon the work non-commercially, as long as appropriate credit is given and the new creations are licensed under the identical terms.

**For reprints contact:** WKHLRPMedknow\_reprints@wolterskluwer.com

**How to cite this article:** Babalola YO. Anterior segment and ocular adnexal lesions in patients with human immunodeficiency virus infection and acquired immunodeficiency syndrome at a tertiary hospital in Southwestern Nigeria. Niger J Med 2023;32:63-8.

**Submitted:** 15-Dec-2022

**Revised:** 20-Feb-2023

**Accepted:** 26-Feb-2023

**Published:** 25-Apr-2023

### Access this article online

#### Quick Response Code:



**Website:**  
www.njmonline.org

**DOI:**  
10.4103/NJM.NJM\_128\_22

million (54.6%) reside in sub-Saharan Africa.<sup>[2]</sup> In Nigeria, presently, about 1.7 million people are living with HIV/AIDS.<sup>[3]</sup> It is a multisystemic disease with a variety of complications which may involve the ocular structures.<sup>[4]</sup> A vast number of these ocular manifestations could be visually debilitating. Varying prevalence of these ocular manifestations ranging from 23.73% in China to 39% in India has been reported.<sup>[5,6]</sup>

HIV/AIDS ophthalmic manifestations involving the anterior segment and ocular adnexae include herpes zoster ophthalmicus (HZO), molluscum contagiosum, blepharitis, keratoconjunctivitis sicca, conjunctival microangiopathy, squamous cell carcinoma (SCC) of the lids, and conjunctiva and Kaposi's sarcoma.<sup>[7,8]</sup> HZO and SCC are also classified as HIV/AIDS-defining illnesses. Different studies both worldwide and locally have reported various prevalence of these ocular disorders involving the anterior segment and ocular adnexae.<sup>[9-12]</sup> In a study of vitreoretinal manifestations in this same study population, presumed ocular toxoplasmosis was the most common finding.<sup>[13]</sup>

## MATERIALS AND METHODS

A prospective, hospital-based cross-sectional study of HIV/AIDS patients attending the antiretroviral therapy clinic of a tertiary health institution in the southwest region of Nigeria was carried out for six months from August 2009 to January 2010. All patients who satisfied the inclusion criteria which include HIV-positive patients confirmed by Western Blot Technique and attended the antiretroviral therapy clinic and consented to participate in the study were included, while those who were unwilling to give consent and HIV diagnosis was yet to be confirmed were excluded. The antiretroviral clinic is the major antiretroviral therapy clinic serving HIV/AIDS patients in the southwest axis of Nigeria. The sample size was calculated using the Leslie-Kish formula. Three hundred and eighteen patients were recruited for the study. The relevant information such as the CD4 count, viral load, and stage of the disease was retrieved from the patient files. All ocular examinations were carried out at the eye clinic. Ethical approval was obtained from the hospital research ethics committee of the hospital (UI/EC/10/0008).

A structured interviewer-administered questionnaire was used for the collection of relevant data, detailed ocular examinations, and retrieval of the CD4+, and viral load values from the patients' records were carried out. The ocular examination consisted of visual acuity measurement, pen torch and slit-lamp biomicroscopy of the anterior segment, fundus biomicroscopy with a 78D Volk lens binocular indirect ophthalmoscopy after pupillary dilation, and applanation tonometry. The structured interviewer-administered questionnaire was completed for all the participants by a trained research assistant. The CD4+ and viral load values were duly retrieved from patient files.

The ocular examination and procedures to be carried out were explained to all patients. All ocular examinations were carried out by the author, and cases that required specialist

management were reviewed by the appropriate ophthalmic subspecialty. Pupillary dilatation with phenylephrine 2.5%/tropicamide 1% combination eye drops for detailed examination of the fundus was done in all patients. The anterior segment and ocular adnexal manifestations were compared to the most recent viral load and CD4 count at the time of examination where available.

The relevant patient information was assessed and included age, gender, the best-corrected visual acuity, pen torch and slit-lamp examination findings, funduscopy findings and applanation tonometry values, CD4 count, and viral load values. Statistical analysis was performed with SPSS software (Statistical Package for the Social Sciences version 16, Chicago, Illinois, USA). To analyse the association, Chi-square test application was done to the data wherever possible, and  $P < 0.05$  was considered statistically significant and calculated at 95% confidence interval.

## RESULTS

Two hundred and twenty-five females and 93 males making a total of 318 patients were recruited into the study. The female-to-male ratio was 2:1. The mean age was 47.2 years, and 123 of the patients were in the 40–49-year age group [Table 1].<sup>[13]</sup> There was a statistically significant association between the age and sex of the patients who participated in the study ( $p < 0.05$ ). The most common occupation was trading and this accounted for 47% of all recruited patients [Table 2].<sup>[13]</sup> Secondary school level education accounted for 40.6% of the educational status level as seen in 129 of the patients. Two hundred and

**Table 1: Demographic data of patients with human immunodeficiency virus and acquired immunodeficiency syndrome**

Age group	Male, n (%)	Female, n (%)	Total, n (%)
20-29	6 (6.5)	27 (12.0)	33 (10.4)
3-39	19 (20.4)	79 (35.1)	98 (30.8)
40-49	38 (40.9)	85 (37.8)	123 (38.7)
50-59	22 (23.6)	28 (12.4)	50 (15.7)
60-69	8 (8.6)	6 (2.7)	14 (4.4)

**Table 2: Occupation of patients with human immunodeficiency virus and acquired immunodeficiency syndrome**

Occupation	Male, n (%)	Female, n (%)	Total, n (%)
Trader	26 (28.0)	125 (55.6)	151 (47.5)
Artisans	20 (27.95)	54 (24.05)	75 (23.6)
Civil servant	14 (18.3)	29 (12.9)	43 (13.6)
Driver	18 (19.35)	1 (0.4)	18 (5.7)
Student	4 (4.3)	5 (2.2)	9 (2.8)
Unemployed	2 (2.2)	5 (2.2)	7 (2.2)
Military/paramilitary	4 (4.3)	2 (0.9)	6 (1.9)
Farmer	3 (3.2)	3 (1.3)	6 (1.9)
Clergy/Imam	2 (2.2)	1 (0.4)	3 (0.9)

twelve (66.7%) respondents were married followed by the widowed who were 36 (11.6%), most of whom were female.

Multiple sexual partners through the heterosexual route (54.7%) was the most common risk factor for HIV/AIDS infection in 174 patients followed by the use of unsterilised objects for barbing, shaving, and skin piercing in 115 (36.2%) patients and history of sexually transmitted diseases in 31 (9.7%) respondents. Nearly 67.4% of respondents were from monogamous marital setups. A total of 277 (87.1%) patients were on highly active antiretroviral therapy (HAART), whereas 41 (12.9%) were nontreatment eligible as at the time of the study. Sixty-five per cent of these patients had been on HAART for three years or above. One hundred and eighty-eight patients (71.3%) and 109 (40.4%) of respondents had CD4+ cell count  $\geq 400$   $\text{cm}^3$  and viral loads  $\leq 200$  copies, respectively.

The most common presenting complaint was blurring of vision followed by itching, photophobia, and sudden vision loss. There was a statistically significant relationship between the CD4+ count and itching  $p=0.04$ . Patients with itching had higher mean CD4+ counts of 473.9  $\text{cmm}^3$  in comparison to the value of 354  $\text{cmm}^2$  in those without. Three hundred and three patients (95.3%) had visual acuity  $>6/18$  in both eyes, while there were six eyes (0.94%) with visual acuity of no light perception. One hundred and ninety-six patients in whom investigation values could be retrieved from the case notes had viral load values  $<200$  copies and CD4+ counts  $>400$   $\text{cmm}^3$ , respectively. The mean CD4+ count of 401.5  $\text{cmm}^3$  for those with conjunctival microangiopathy was higher in comparison to 367.2  $\text{cmm}^3$  in those without. In those with pingueculum, the mean CD4 count was 389.8  $\text{cmm}^3$ , while in those without, it was 365.5  $\text{cmm}^3$ . Viral load values of  $\leq 200$  copies were present in 76.9% of patients and CD4+ counts  $\geq 400$   $\text{cmm}^3$  in 78.3% of those with investigation results available in the patient notes.

One hundred and sixty-five patients (52%) were at Stage 3 disease according to the World Health Organisation clinical classification of HIV/AIDS infection. The HIV-1 strain was the most common in the study and was present in 313 patients, whereas the HIV-2 strain was found in 2 (1%) and a combination of both HIV – 1 and 2 strains was seen in another two (1%) patients. Systemic comorbidities in the respondents include hypertension present in 32 patients (10%), whereas six patients (2%) were diabetic. Two patients were on treatment for liver disease secondary to drug reactions from HAART. Patients on HAART had more ocular diagnosis in both the anterior segment and the ocular adnexa.

A total of fifty-nine anterior segment and 335 ocular adnexa diagnoses respectively was present in the study population. The most common anterior segment finding was corneal opacity in 18 patients (5.6%), followed by anterior uveitis in 9 (2.8%) of the study patients [Table 3]. Pingueculum was the most common ocular adnexal finding in 139 patients (43.7%), followed by conjunctival

**Table 3: Anterior segment lesions in patients with human immunodeficiency virus and acquired immunodeficiency syndrome**

Ocular diagnosis	HAART, n (%)	Non-HAART, n (%)	Total, n (%)
Corneal opacities	17 (28.8)	1 (1.7)	18 (30.5)
Anterior uveitis	5 (8.5)	4 (6.8)	9 (15.3)
Complicated cataract	6 (10.2)	0	6 (10.2)
Senile cataract	5 (8.5)	0	5 (8.5)
HZO keratouveitis	4 (6.7)	0	4 (6.7)
Iris nevus	3 (5.1)	1 (1.6)	4 (6.7)
Tuberculous uveitis	3 (5.1)	0	3 (5.1)
Conjunctival nevus	3 (5.1)	0	3 (5.1)
Bacterial conjunctivitis	2 (3.4)	0	2 (3.4)
Pseudophakia	2 (3.4)	0	2 (3.4)
Dry eye	1 (1.7)	0	1 (1.7)
Herpes simplex keratitis	1 (1.7)	0	1 (1.7)
Corneal foreign body	1 (1.7)	0	1 (1.7)
Total	53 (89.9)	6 (10.1)	59 (100)

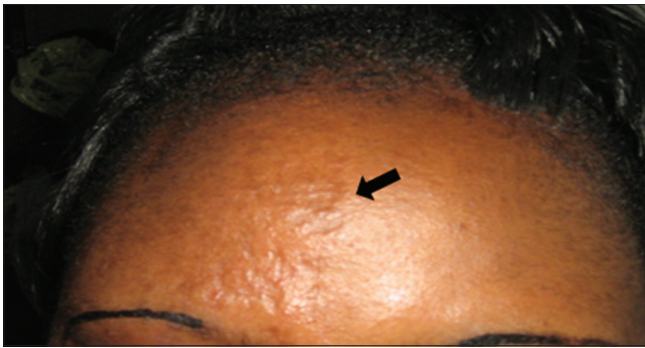HZO: Herpes zoster ophthalmicus, HAART: Highly active antiretroviral therapy

**Table 4: Ocular adnexal manifestations of patients with human immunodeficiency virus and acquired immunodeficiency syndrome**

Ocular diagnosis	HAART, n (%)	Non-HAART, n (%)	Total, n (%)
Pingueculum	122 (36.4)	17 (5.1)	139 (41.5)
Conjunctival microangiopathy	40 (11.9)	16 (4.8)	56 (16.7)
Pterygium	39 (11.6)	4 (1.2)	43 (12.8)
Allergic conjunctivitis	12 (3.6)	11 (3.3)	23 (6.9)
Lid papilloma	27 (8.1)	1 (0.3)	28 (8.4)
Hypertrichosis/trichomegaly	20 (5.9)	5 (1.5)	25 (7.4)
Herpes zoster ophthalmicus	13 (3.9)	1 (0.3)	14 (4.2)
SCC	4 (1.2)	0	4 (1.2)
Cyst of moll	1 (0.3)	0	1 (0.3)
Entropion	1 (0.3)	0	1 (0.3)
Phthisis bulbi	1 (0.3)	0	1 (0.3)
Total	280 (83.5)	55 (16.5)	335 (100)

HAART: Highly active antiretroviral therapy, SCC: Squamous cell carcinoma

microangiopathy in 56 (17.6%) [Table 4]. Conjunctival microangiopathy was the most frequent HIV/AIDS-associated ocular pathology, followed by hypertrichosis/trichomegaly in 25 (7.9%) and HZO [Table 3] in 14 (4.4%) patients [Figure 1]. Four (1.3%) of patients presented with features of HZO keratouveitis, whereas one patient had a diagnosis of herpes simplex keratitis. Tuberculous uveitis was present in 3 (0.9%) [Figure 2]. Eleven (3.5%) patients had cataracts, of which six were complicated and secondary to other ocular conditions such as uveitis. Anterior uveitis was present in nine patients (2.8%). Multiple ocular pathology of both the anterior segment and ocular adnexal was present. This was responsible for the number of these ocular disorders being higher than the total number of patients recruited for the study.



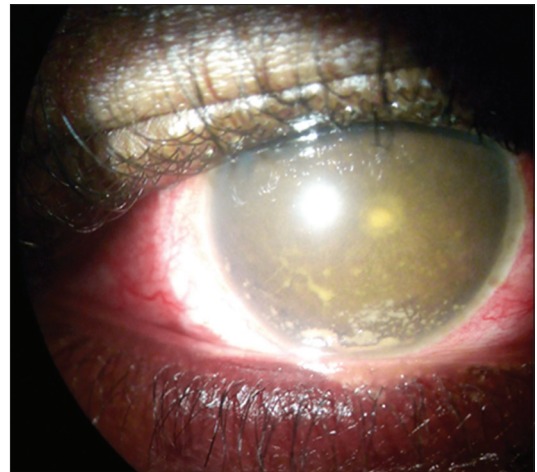
**Figure 1:** Scars on the right frontal area (black arrow) supplied by the ophthalmic branch of the trigeminal nerve secondary to healed herpes zoster ophthalmicus

## DISCUSSION

Ocular disorders involving the anterior segment occurred in 92.8% of the total number of patients studied, whereas ocular adnexa lesions was present in 42.1% of patients. A similar study in Nigeria and Ethiopia gave a preponderance of anterior segment/ocular adnexa lesions which is lower than the findings of these studies.<sup>[7,9]</sup> In Asia, lower occurrences of both anterior segment and ocular adnexal lesions were noted in comparison to our findings and those from other parts of Africa.<sup>[10,11]</sup> Regarding the ocular manifestations of HIV/AIDS in ophthalmic practice in general, greater focus is on the visually debilitating lesions which commonly affect the posterior segment. Differences in the geographical location may be a contributory factor to the varying occurrences of these ocular lesions.

Pingueculum and conjunctival microangiopathy were the most ocular adnexa lesions similar to the findings in other localities in Nigeria including Benue and Port Harcourt. Differing from our findings, dry eye and blepharitis were the more prevalent findings in Ethiopia and Thailand.<sup>[7,9,11,12]</sup> Only a single respondent in our study had features of dry eye syndrome. This was in variance with recent studies in Enugu and Katsina with the prevalence of 14.5% and 25.5%, respectively.<sup>[14,15]</sup> Dry eye is known to be common in Asians, and the prevalent climate of these regions may also be a factor for this higher prevalence.<sup>[11]</sup>

Sludging of blood in the vessels, segmental dilatation, and narrowing of the vessels were the common features of conjunctival microangiopathy seen. Patients with low CD4 + counts of  $<200 \text{ mm}^3$  are thought to be more prone to the development of conjunctival microangiopathy.<sup>[16]</sup> Lid papilloma was a common finding in the ocular adnexa. They were small in diameter and measured approximately  $0.1 \text{ mm} \times 0.1 \text{ mm}$  and were asymptomatic. These papillomas were not found in similar studies relating to ocular manifestations of HIV/AIDS. Hence, they may be innocuous or incidental findings. Contrary to other studies, molluscum contagiosum which was a relatively frequent finding in other parts of the world was not present in any of



**Figure 2:** The anterior segment photograph of a patient with seclusio pupillae, complicated cataract, and granulomatous uveitis secondary to tuberculosis

the respondents in this index study.<sup>[7,11]</sup> This nonexistence may be due to warm and humid environments being a risk factor for its occurrence.

The prevalence of hypertrichosis and trichomegaly was 7.9% and contrasted to similar local studies in which no case of either hypertrichosis or trichomegaly was documented. A patient with Stage 4 disease, recently diagnosed with HIV/AIDS and yet to be commenced on HAART, had hypertrichosis in coexistence with HIV retinopathy. Hypertrichosis and HIV retinopathy may occur in severely immunosuppressed patients with advanced disease and those yet to commence antiretroviral therapy. Zidovudine has been implicated as a possible etiology of hypertrichosis and nail pigmentation.<sup>[17,18]</sup> This may be a side effect of therapy though it is not feasible identifying the culpable antiretroviral agent in as much as they are combination therapy and are formulated in a single tablet for easy drug compliance.

HZO is a common HIV/AIDS-defining illness. HZO was present in 4.4% of the study patients. The prevalence in Ibadan was similar in comparison to other studies with the prevalence of 2% in Makurdi, 2.7% in Port Harcourt, 3.2% in Katsina, 3.3% in Lagos, and 6.25% in Benin but much lower than the prevalence of 48% in Onitsha.<sup>[7,12,14,19-21]</sup> An attributable factor for this is that all patients in this cohort were enrolled from the antiretroviral therapy clinic in comparison to the majority of these other studies which involved patients presenting to the eye clinic with ocular complaints. The study in Onitsha in particular included all patients with a positive HIV test seen at the eye clinic over a six-year period; hence, this could account for the high prevalence of HZO at 48%.<sup>[21]</sup>

Presumed SCC was seen in 1.3% of all respondents and accounted for 1.2% of all ocular adnexal diagnoses. The diagnosis of SCC was confirmed in a single patient who had an excision biopsy with the confirmation of diagnosis by histopathology. The prevalence of SCC in this study was

lower than studies in Lagos with 3.8%, Port Harcourt with 2.9%, and Owo with 25% but higher than that of Benin city with the prevalence of 0.2%.<sup>[12,19,20,22]</sup> Exposure to ultraviolet light is a known risk factor for SCC; hence, the hot climate in the southwest may be an additional risk factor. An increased occurrence of SCC is associated with HIV/AIDS in Africa compared to the developed world; studies in Asia and the United States had no occurrences of SCC.<sup>[11,23]</sup> This may be ascribable to the delayed presentation and commencement of therapy in patients in a developing country like Nigeria in comparison to more industrialised economies with better access to health care and treatment.

Anterior uveitis of varying etiology ranged from idiopathic to herpes zoster and tuberculosis with a prevalence of 2.8%. The classical signs of uveitis were absent in the most of the seemingly idiopathic cases with the only visual complaint being mild blurring of vision in the presence of anterior chamber cells. HIV-associated idiopathic anterior uveitis is an entity with mild-to-moderate inflammation in the absence of active retinitis described in patients with CD4+ counts <50 cells/mm<sup>3</sup>.

Although Rifabutin and cidofovir are known causes of anterior uveitis in HIV/AIDS, none of the patients diagnosed with uveitis was on these drugs.<sup>[24]</sup>

Cataracts were present in 11 patients, five of which were senile while the remaining six were complicated with uveitis features. Uveitic cataracts are not unexpected in HIV/AIDS as intraocular inflammation is a common occurrence in HIV/AIDS. Our prevalence of 3.5% was similar to the findings in Onitsha but lower than in Makurdi.<sup>[7,21]</sup> Two patients were pseudophakic and had their eye surgeries performed at the eye department of our hospital. These two patients did not disclose their retroviral status preoperatively. As screening for HIV/AIDS is not routinely done for cataract surgery, the retroviral infection was not detected.

Corneal opacities or scars were present in 5.7% of the study population and were not a finding in other local and international studies. It was also the most common anterior segment diagnosis. A possible differential is posterior intracorneal opacities which usually occurs bilaterally and is present at the corneal periphery.<sup>[25]</sup> The majority of the corneal opacities in the patients were unilateral and may be secondary to healed keratitis or trauma. Contrary to the findings in other studies, none of our patients had features of molluscum contagiosum which was a relatively frequent ocular adnexal finding in other parts of the world.<sup>[7,11]</sup>

One hundred and eighty-eight (71.3%) and 109 (40.4%) of the patients studied had CD4+ cell count  $\geq 400$  cm<sup>3</sup> and viral loads  $\leq 200$  copies, respectively. This is a pointer that several of the study patients had a good response to HAART and fairly good immunity against opportunistic infections and other HIV-associated infections. It also emphasises the beneficial effect of affordable treatment in the reduction and prevention

of the complications of HIV/AIDS. The limitation of the study was the unavailability of CD4 count and viral load values for all respondents in the study.

## CONCLUSION

Anterior segment and ocular adnexal lesions constitute a significant proportion of ocular manifestations of HIV/AIDS in Nigeria. Prompt referral to the ophthalmologists for review is essential when patients present with symptoms of ocular disorders. This would aid in limiting preventable blindness from HIV/AIDS-associated ocular disorders.

## Financial support and sponsorship

Nil.

## Conflicts of interest

There are no conflicts of interest.

## REFERENCES

- Barré-Sinoussi F, Chermann JC, Rey F, Nugeyre MT, Chamaret S, Gruest J, *et al.* Isolation of a T-lymphotropic retrovirus from a patient at risk for acquired immune deficiency syndrome (AIDS). *Science* 1983;220:868-71.
- UNAIDS Global HIV/AIDS Statistics Fact Sheet. Available from: <https://www.unaids.org/en/resources/fact-sheet>. [Last assessed on 2022 Nov 15].
- StatistaFacts. Available from: <https://www.statista.com/statistics/1128675/people-living-with-hiv-receiving-treatment-in-nigerians>. [Last assessed on 2022 Nov 15].
- Holland GN, Gottlieb MS, Yee RD, Schanker HM, Pettit TH. Ocular disorders associated with a new severe acquired cellular immunodeficiency syndrome. *Am J Ophthalmol* 1982;93:393-402.
- Luo J, Jing D, Kozak I, Huiming Z, Siying C, Yezhen Y, *et al.* Prevalence of ocular manifestations of HIV/AIDS in the highly active antiretroviral therapy (HAART) era: A different spectrum in Central South China. *Ophthalmic Epidemiol* 2013;20:170-5.
- Hothi HS, Gohil NR, Parekh NV, Patel SS. A prevalence study of ocular manifestations in HIV positive patients on highly active anti-retroviral therapy. *Int J Of Com Med Pub Health* 2019;6:2950-4.
- Bologi A, Ojabo CO. Ocular adnexal and anterior segment manifestations of HIV/AIDS patients as seen at the HIV clinic, 45 Nigerian Airforce Hospital Makurdi, Benue State, Nigeria. *Niger J Ophthalmol* 2010;17:50-4.
- Biswas J, Sudharshan S. Anterior segment manifestations of human immunodeficiency virus/acquired immune deficiency syndrome. *Indian J Ophthalmol* 2008;56:363-75.
- Bekele S, Gelaw Y, Tessema F. Ocular manifestation of HIV/AIDS and correlation with CD4+cells count among adult HIV/AIDS patients in Jimma town, Ethiopia: A cross sectional study. *BMC Ophthalmol* 2013;13:20.
- Sharma M, Chauhan A, Sharma G, Chauhan V. Ocular manifestations in patients attending antiretroviral therapy centre at a tertiary care hospital in Himachal Pradesh, India. *Indian J Med Res* 2018;147:496-500.
- Singalavanija T, Ausayakhun S, Tangmonkongvoragul C. Anterior segment and external ocular disorders associated with HIV infections in the era of HAART in Chiang Mai university hospital, a prospective descriptive cross sectional study. *PLoS One* 2018;13:e0193161.
- Arowolo M, Awoyesuku EA, Pedro-Egbe CN. Ocular diseases in HIV-positive patients in a tertiary hospital in Nigeria. *Int J Trop Dis Health* 2019;39:1-9.
- Babalola YO, Oluleye TS, Ashaye AO. Vitreoretinal manifestations of human immunodeficiency virus infection and acquired immunodeficiency syndrome in patients attending an antiretroviral therapy clinic in Nigeria: A cross sectional study. *J. Clin Sci* 2022;19:73-9.
- Abdurrahman H, Eze UA, Suleman YS, Aba ER, Samaila E.

- Prevalence and determinants of HIV related eye in patients attending anti-retroviral therapy clinic in Katsina State, Nigeria. *Ophthalmol Res* 2023;18:45-55.
15. Chime AA, Eze UA, Onwubiko SN, Udeh NN, Chime MO, *et al.* Ocular manifestations and socio-demographic factors among adults on highly active anti-retroviral therapy (HAART) in Enugu, Nigeria. *JAMMR* 2022;34:396-404.
  16. Sudharshan S, Nair N, Curi A, Banker A, Kempen JH. Human immunodeficiency virus and intraocular inflammation in the era of highly active antiretroviral therapy – An update. *Indian J Ophthalmol* 2020;68:1787-98.
  17. Almagro M, del Pozo J, García-Silva J, Martínez W, Castro A, Fonseca E. Eyelash length in HIV-infected patients. *AIDS* 2003;17:1695-6.
  18. Sahai J, Conway B, Cameron D, Garber G. Zidovudine-associated hypertrichosis and nail pigmentation in an HIV-infected patient. *AIDS* 1991;5:1395-6.
  19. Onakoya AO, Odeyemi MG, Aribaba OT, Akinsola FB. Ocular findings in acquired immunodeficiency syndrome patients in Lagos, Nigeria. *Niger J Hosp Med* 2012;22:52-7.
  20. Osahon AI, Onunu AN. Ocular disorders in patients infected with the human immunodeficiency virus at the University of Benin teaching hospital, Benin City, Nigeria. *Niger J Clin Pract* 2007;10:283-6.
  21. Nwosu NN. HIV/AIDS in ophthalmic patients: The Guinness eye centre Onitsha experience. *Niger Postgrad Med J* 2008;15:24-7.
  22. Omolase CO, Komolafe OO, Ayodeji OO, Omolase BO, Akinwalere AK, Majekodunmi MY. Ocular manifestations in HIV/AIDS patients in a Nigerian community. *S Afr Fam Pract* 2012;456:455-58.
  23. Waddell KM, Lewallen S, Lucas SB, Atenyi-Agaba C, Herrington CS, Liomba G. Carcinoma of the conjunctiva and HIV infection in Uganda and Malawi. *Br J Ophthalmol* 1996;80:503-8.
  24. Testi I, Agarwal A, Agrawal R, Mahajan S, Marchese A, Miserochi E, *et al.* Drug-induced uveitis in HIV patients with ocular opportunistic infections. *Ocul Immunol Inflamm* 2020;28:1069-75.
  25. Thorne JE, Shah KH, Brown DM, Holland GN, Jabs DA. Posterior intracorneal opacities in patients with HIV infection. *Ocul Immunol Inflamm* 2005;13:25-31.