

Histopathologic Profile of Bone and Joint Lesions in a Tertiary Health Institution in Southeast Nigeria: A Nine-year Review

Ifeoma Florence Ezejiofor¹, Olaniyi Olaejirinde Olaofe², Ogochukwu Ifeanyi Ezejiofor³, C. O. Ukah¹, Nnamdi Sergius Ozor¹, Chukwuemeka Nonyelum Osonwa¹

¹Department of Anatomic Pathology and Forensic Medicine, Nnamdi Azikiwe University, Awka, ²Department of Dermatology, Nnamdi Azikiwe University Teaching Hospital, Nnewi, ³Department of Morbid Anatomy and Forensic Medicine, Obafemi Awolowo University Teaching Hospitals Complex, Ile-Ife, Osun State, Nigeria

Abstract

Background: The human skeletal system is composed of all the bones, joints, cartilage, ligaments, and tendons. The lesions of this system were thought to be uncommon in our environment and like lesions in any other part of the body are better managed when early presentations and correct diagnosis are made. The paucity of research on these lesions has prompted the need to study the topic. **Aims:** We aimed to study the bone and joint lesions, with a view to determining the most common types, the most involved sites of the body, the sex, and the age of presentations. **Materials and Methods:** This was a retrospective study carried out at the Histopathology Department of Nnamdi Azikiwe University Teaching Hospital, Nnewi, Nigeria, from 2011 to 2019. **Results:** Eighty-four cases of bone and joint lesions were diagnosed in the study period, and they had a slight male preponderance with a M: F ratio of 1.4:1 and a mean age of 38.7 ± 22.0 years. Nonneoplastic lesions were more common 58.3% (49/84) than neoplastic tumours 41.7% (35/84). Benign tumours were however more common 27.4% (23/84) than malignant tumours 14.3% (12/84). Nonneoplastic lesions and benign tumours were seen in the first and second decades of life while malignant tumours occurred in the third and fourth decades. Of the 84 lesions, 47 cases were bone lesions while 37 were joint lesions. Osteomyelitis was the most common nonneoplastic bone lesion (7/47; 14.9%) while osteochondroma and giant cell tumours were the most common and only benign bone tumours seen and accounted for 14.9% (7/47) of cases each. Metastatic bone diseases (5/47; 10.6%) and osteosarcoma (4/47; 8.5%) were the most common malignant bone tumours, with osteosarcoma being the most common primary bone malignant tumours (4/7; 57.1%). Ganglion cysts were the most common lesions in all accounting for 23.8% (20/84) and the most common nonneoplastic (20/49; 40.8%) and joint lesions (20/37; 54.1%). Nodular tenosynovitis was the most common benign joint tumour and accounted for 10.8% (4/37) of cases; there is no malignant joint tumour. Skull was the most common anatomic site for bone lesions while the humerus was the most common anatomic site for bone tumours whereas wrist was the most common site for joint lesions. **Conclusion:** Nonneoplastic bone and joint lesions were more common than neoplastic lesions in our environment, with ganglion cysts being the most common joint lesions while osteomyelitis, osteochondroma, and giant cell tumours were the most common bone lesions. There is no malignant joint tumour observed in this study.

Keywords: Bone lesions, histopathology, joint lesions, Southeast Nigeria

INTRODUCTION

The human skeletal system is the internal framework of the human body composed of all the bones, joints, cartilage, ligaments, and tendons and altogether weighs 20% of total body weight.^[1] Each of these components of skeletal system can present with myriad of pathologies.

Spectrum of bone pathologies ranged from metabolic diseases, Paget's diseases (osteitis deformans), fracture, osteomyelitis, bone infarct and necrosis, tumours, cystic lesions, metastatic to miscellaneous lesions.^[1-3] These lesions have a slight male preponderance and may affect children,

adults, or elderly persons.^[4] They may present with pain, palpable mass, or by restricting the movement of the part involved.^[1-4] Bone lesions may sometimes be asymptomatic or present with unspecific signs and symptoms mimicking

Address for correspondence: Dr. Ifeoma Florence Ezejiofor,
Department of Anatomic Pathology and Forensic Medicine, Nnamdi Azikiwe
University, Awka, Nigeria.
E-mail: ogify68@yahoo.com

This is an open access journal, and articles are distributed under the terms of the Creative Commons Attribution-NonCommercial-ShareAlike 4.0 License, which allows others to remix, tweak, and build upon the work non-commercially, as long as appropriate credit is given and the new creations are licensed under the identical terms.

For reprints contact: WKHLRPMedknow_reprints@wolterskluwer.com

How to cite this article: Ezejiofor IF, Olaofe OO, Ezejiofor OI, Ukah CO, Ozor NS, Osonwa CN. Histopathologic profile of bone and joint lesions in a tertiary health institution in Southeast Nigeria: A nine-year review. *Niger J Med* 2023;32:15-22.

Submitted: 30-Oct-2022

Revised: 06-Feb-2023

Accepted: 17-Feb-2023

Published: 25-Apr-2023

Access this article online

Quick Response Code:



Website:
www.njmonline.org

DOI:
10.4103/NJM.NJM_110_22

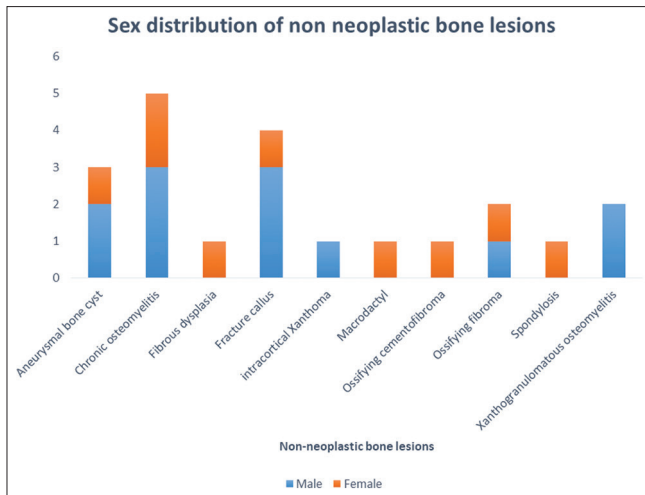


Figure 1: Histologic types and gender distributions of nonneoplastic bone lesions

each other clinically.^[1-4] Patient with Ewing's sarcoma may present with fever and increase erythrocyte sedimentation rate mimicking the diagnosis of osteomyelitis.^[1-4] These lesions therefore, would require other investigative tools, especially histology to confirm the diagnosis.^[1-4] Some aetiologies of nonneoplastic bone lesions are unknown, while some are strongly associated with multiple factors such as repeated traumatic stress, viral, bacterial or fungal infections, hormonal increase or deficiencies, and inherited syndromes or diseases.^[1-3] Little information is available concerning the aetiology and epidemiologic features of benign bone tumours, but malignant bone tumours can develop *de novo* or arise from somatic mutations, while some are associated with risk factors such as irradiation, chemotherapy, and foreign bodies.^[1-3,5] More so, some skeletal malignancies can arise from preexisting benign bone lesions such as Paget's disease, enchondromatosis, osteochondromatosis, fibrous dysplasia, or bone infarct.^[1-3,5] Globally, bone sarcomas account for 0.2%–0.5% of all malignancies, and the adjusted incidence rate for all bone and joint malignancies is 0.9 per 100,000 persons per year, while the five-year overall survival rate is 67.9%.^[5] However, the incidence of benign bone tumours is higher than primary malignant bone lesions.^[5] The primary malignant bone tumour incidence is slightly higher in males than females (10/million/year vs. 8/million/year), and it shows bimodal distribution in the second decade of life and in ages older than 60 years.^[5] Although, primary bone neoplasms and tumour-like conditions are rare worldwide.^[2,3,6] Nevertheless, bone tumours have been identified to be on the rise in Africa, England, and other parts of the world with its tendency to affect young children and adolescents.^[7-9] In spite of small percentage of primary bone malignancies, they are responsible for morbidity and mortality in young patients.^[5] It is therefore of utmost importance to expand research on these lesions in order to detect specific molecular changes, or clonal chromosomal aberrations to prompt accurate diagnosis and prevent

advanced stage of presentations in order to curb morbidity and mortality associated with these lesions.

Joint pathologies are few in relation to bone lesions and include ganglia, Baker's cyst, carpal tunnel syndrome, arthritis, tumours, and tumour-like conditions.^[2,3] Among these lesions, ganglion cysts were common tumefactive deformities associated with repeated trauma and occur near joints, especially in the volar wrist, while osteoarthritis is the most common joint disease caused by secondary degenerative changes due to aging process and exacerbated by repeated trauma.^[2,3] Other arthritides include rheumatoid arthritis, infectious arthritis, and gout while the joint tumours include mainly localised nodular tenosynovitis or diffuse pigmented villonodular tenosynovitis and rarely synovial chondromatosis and synovial hemangioma with their extremely rare malignant counterpart.^[2,3]

Significantly, there is a dearth of information on these lesions at Nnamdi Azikiwe University Teaching Hospital (NAUTH), Nnewi, Nigeria. This study is therefore aimed at providing the baseline data in NAUTH for further research as well as determining the frequency and morphological patterns of musculoskeletal lesions in our institution.

MATERIALS AND METHODS

Setting

NAUTH is a federal teaching hospital located in Nnewi – a major economic hub with many manufacturing companies and one of the three major cities in Anambra state located in the southern part of the state about 22 km southeast of Onitsha. As a referral centre, it provides tertiary-level health care for patients within Anambra state as well as neighboring cities and states. Anambra state is one of the five south-eastern states of Nigeria, with a population of 4,055,048 and population density of 840/km² according to the 2006 census.^[10] Its boundaries are formed by Delta state to the west, Imo and River states to the south, Enugu state to the east, and Kogi state to the north.

Method

This was a retrospective study which spanned over a nine-year period and involved 84 lesions comprising 47 bone lesions and 37 joint lesions diagnosed in the Histopathology Department of NAUTH, Nnewi, Nigeria, from January 2011 to December 2019. Laboratory request forms and duplicate copies of histologic reports were retrieved and relevant clinical information and histological type of the lesions were extracted. The exclusion criteria include inadequate records ranging from unrepresentative tissue, incomplete clinical details of age, and gender. All lesions of hematopoietic and odontogenic origins were also excluded from this study. Bone biopsy was performed by either percutaneous method with drill or open surgical biopsy. The bony tissues were put for decalcification in 10% nitric acid. They were then sectioned and mounted on glass slide and stained with routine histochemical stain (hematoxylin and eosin). The

slides were reviewed by the authors using multi-headed light microscope (CARL ZEISS®).

Data analysis

Data were analysed using statistics software Statistical Package for the Social Sciences (SPSS) Incorporated, version 21 Chicago, Illinois, USA. Quantitative continuous variables such as age were summarised using mean and standard deviation while categorical variables such as sex were summarised using percentage. Results were presented in tables and charts. Pearson's Chi-square was used to test the association between two categorical variables, and $P < 0.05$ was considered statistically significant.

RESULTS

A total of 84 lesions were analysed, and it accounted for 1.2% (84/7324) of all surgical specimens received in the laboratory within the study period. 58.3% (58.3%; 49/84) were male and 41.7% (35/84) were female giving a male-to-female ratio of 1.4:1 with a mean age of 38.7 ± 22.0 years. The age range of persons that presented with the lesions in this study was 1–80 years. Most cases were seen in the age group of 1–20 years (29 cases, 34.5%) and the least cases were seen in the age group above 70 years (two cases, 2.4%). Out of the 84 lesions analysed, 47 cases were bone lesions while 37 were joint lesions. The nonneoplastic bone lesions 25.0% (21/84) and joint 33.3% (28/84) were more common comprising 58.3% (49/84) of all the lesions under study. The male-to-female ratio of nonneoplastic bone lesions shows a slight male preponderance of 1.2:1 [Figure 1] while that of joint lesions shows a slight female predilection with a M: F ratio of 1:1.2.

The total neoplastic lesions seen in this study were 41.7% (35/84), which included 27.4% (23/84) of benign tumours and 14.3% (12/84) of malignant tumours.

Fourteen (14/23; 60.9%) cases were benign bone tumours and they showed a marked male preponderance with a M: F ratio of 3.3:1 while nine (39.1%; 9/23) cases were benign joint tumours and they showed a slight male preponderance with a M: F ratio of 1.3:1.

There was no malignant joint lesion seen in this study, and all malignant cases were bone lesions. They constituted 14.3% (12/84) of all the lesions and had an equal male-to-female ratio.

The age range of the bone lesions was 2–80 years. Of the 47 cases of bone lesions, 31 (37.0%) cases were male and 16 (19.0%) cases were female giving a M: F ratio of 2:1. Nonneoplastic lesions were 21 (44.7%) cases out of 47 bone lesions. These nonneoplastic lesions occurred more in the age groups of 21–40 years (31.8%; 7/22) with a slight male preponderance and a male-to-female ratio of 1.4:1. Among the cases, osteomyelitis which included chronic osteomyelitis and xanthogranulomatous osteomyelitis was most common accounting for 33.3% (7/21) of all nonneoplastic bone lesions and 8.3% (7/84) of all lesions under study. It had a male-to-female ratio of 2:1. Five out of seven cases were seen in the age groups above 40 years. The second most common nonneoplastic bone lesion was fracture callus accounting for 19.0% (4/21) of all nonneoplastic bone lesions and 4.8% (4/84) of all the lesions under study followed by fibroma and aneurysmal bone cyst with (3.6%; 3/84) each while congenital macrodactyly, fibrous dysplasia, intracortical xanthoma, and spondylosis were the least represented with 1.2% (1/84) each [Table 1].

Twenty-six (55.3% 26/47) cases of neoplastic bone lesions were seen in this study and accounted for 31.0% (26/84) of all the lesions and constituted 74.3% (26/35) of all the neoplasms under review. Fourteen (53.8%; 14/26) cases were benign tumours while 12 (46.2%; 12/26) cases were

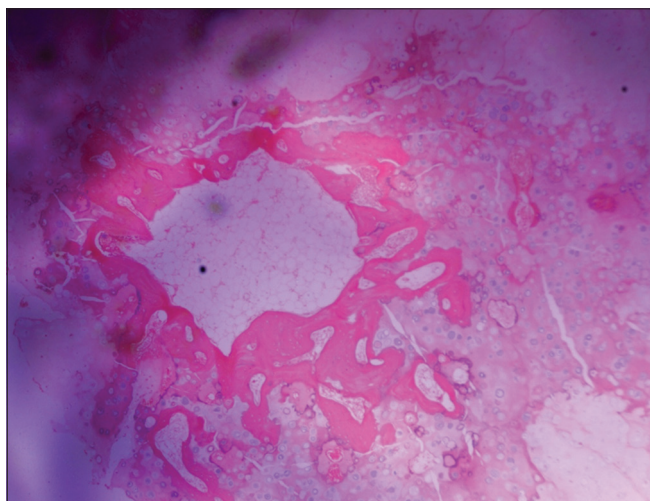


Figure 2: Photomicrograph of osteochondroma shows cap, composed of mature hyaline cartilage overlying bone with central portion having marrow elements

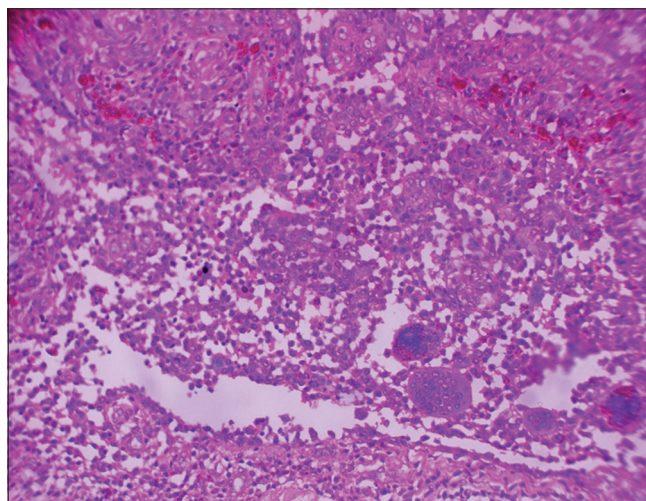


Figure 3: Photomicrograph of pigmented villonodular tenosynovitis shows variable admixture of osteoclast-like giant cells and stromal cells with hemosiderin-laden macrophages in areas

Table 1: Gender and percentage distributions of the lesions of bone and joint

Histopathologic types (n)	Frequency		
	Male, n (%)	Female, n (%)	Total, n (%)
Nonneoplastic bone lesions			
Aneurysmal bone cyst (3)	2 (2.4)	1 (1.2)	3 (3.6)
Chronic osteomyelitis (5)	3 (3.6)	2 (2.4)	5 (6.0)
Fibrous dysplasia (1)	0	1 (1.2)	1 (1.2)
Fracture callus (4)	3 (3.6)	1 (1.2)	4 (4.8)
Intracortical xanthoma (1)	1 (1.2)	0	1 (1.2)
Macroductyly (1)	0	1 (1.2)	1 (1.2)
Cement-ossifying fibroma (1)	0	1 (1.2)	1 (1.2)
Ossifying fibroma (2)	1 (1.2)	1 (1.2)	2 (2.4)
Spondylosis (1)	0	1 (1.2)	1 (1.2)
Xanthogranulomatous osteomyelitis (2)	2 (2.4)	0	2 (2.4)
Neoplastic			
Benign			
Giant cell tumour (7)	5 (6.0)	2 (2.4)	7 (8.3)
Osteochondroma (7)	6 (7.1)	1 (2.1)	7 (8.3)
Malignant			
Chondroblastic osteosarcoma (2)	1 (1.2)	1 (1.2)	2 (2.4)
High-grade osteosarcoma (2)	0	2 (4.2)	2 (2.4)
Chondrosarcoma (1)	1 (1.2)	0	1 (1.2)
Ewing sarcoma/PNET (2)	2 (2.4)	0	2 (2.4)
Metastatic adenocarcinoma (2)	2 (2.4)	0	2 (2.4)
Metastatic SCC (3)	2 (2.4)	1 (1.2)	3 (3.6)
Sub-total of bone lesions	31 (37.0)	16 (19.0)	47 (56.0)
Nonneoplastic joint lesions			
Ganglion cyst (20)	8 (9.5)	12 (14.3)	20 (55.6)
Tophaceous gout arthritis (3)	3 (3.6)	0	3 (3.6)
Hypertrophic synovium (1)	0	1 (1.2)	1 (1.2)
Rheumatoid nodule (1)	0	1 (1.2)	1 (1.2)
Synovial cyst (3)	2 (2.4)	1 (1.2)	3 (3.6)
Benign			
Nodular tenosynovitis (4)	2 (2.4)	2 (2.4)	4 (4.8)
Synovial hemangioma (3)	2 (2.4)	1 (1.2)	3 (3)
Synovial angiomyolipoma (1)	0	1 (1.2)	1 (1.2)
Lipoma arborescens (1)	1 (1.2)	0	1 (1.2)
Malignant (nil)	0	0	0
Sub-total of joint lesions	18 (21.4)	19 (22.6)	37 (44.0)
Total	49 (58.3)	35 (42.0)	84 (100.0)

PNET: Peripheral neuroectodermal tumour, SCC: Squamous cell carcinoma

malignant bone tumours. The benign tumours occurred more in younger age group with a peak age between 1 and 20 years and less frequent after the age of 40 years with a marked male preponderance (M: F = 3.3:1). The 14 cases of benign bone tumours included just osteochondroma [Figure 2] (50.0%; 7/14) and giant cell tumours [Figure 3] (50.0%; 7/14) and accounted for 29.8% (14/47) of all bone lesions and 40.0% (14/35) of all the neoplasm. Both benign bone tumours

had marked male predilections. Giant cell tumours occurred more in the age groups of 20–60 years while osteochondroma occurred more at younger ages of 1–20 years. Malignant bone tumours constituted the remaining bone neoplasms and had 46.2% (12/26). It accounted for 34.3% (12/35) of all the neoplasms and 100.0% (12/12) of all malignant tumours. The majority of cases were found within the age group of 21–40 and above 60 years with an equal male: female ratio of 1:1 [Table 2].

Out of 12 cases of malignant bone tumours, metastatic bone diseases and osteosarcomas were the most common malignancies with 5/84 and 4/84, respectively. Osteosarcomas were however the most common primary bone malignancy seen in this study. Others were chondrosarcoma (1) and Ewing sarcoma/PNET (2).

Skull was the most common anatomic site for all bone lesions with 14.9% (7/47) followed by the humerus with 12.8%. However, humerus was the most common anatomic site for bone tumours with 19.2% (5/26) followed by femur and tibia with 3/26 (11.5%) each [Table 3].

The age range of the joint lesions was 1–76 years. Joint lesions had slight female preponderance with a male-to-female ratio of 1:1.2. There were 37 cases of joint lesions in this study, out of which 28 cases were nonneoplastic. Among the nonneoplastic joint lesions, ganglion cyst was far more common and constituted 71.4% (20/28) of cases and 23.8% (20/84) of all lesions with a M: F ratio of 1:1.5. It occurred in all age groups.

The remaining nine (9/37; 24.3%) cases were neoplastic joint lesions which included only benign tumours. There was no malignant joint tumour seen in this research. Nodular tenosynovitis was the most common benign joint tumours and accounted for 44.4% (4/9) of all joint tumours and 11.4% (4/35) of all the tumours. It occurred at both young and old ages.

Wrist was the most common anatomic site of the joint lesions (25.0%; 13/37) followed by fingers and elbow with 13.5% (5/37) of cases each and the least represented site was spine with only one (2.7%) case [Table 4]. Ganglion cyst was the only joint lesion at the wrist. The second most common location of ganglion cyst was the foot with four cases.

DISCUSSION

Skeletal tumours and tumour-like lesions are comparatively uncommon when compared with wide array of lesions in histopathology.^[4,6,10] There are few published articles of these lesions in South-east Nigeria. Bone lesions often pose diagnostic challenges to pathologists owing to lack of other auxiliary investigative tools in most resource-poor settings.^[4,6,10] However, with increasing bone tumours in Africa, England, and other parts of the world, accurate diagnosis is essential in its management.^[7–9] Clinical data, and radiology aid in accurate diagnosis, but histopathological evaluations are paramount

Table 2: Age-wise distributions of the lesions of bone and joint

Histopathologic types (<i>n</i>)	Age groups							Total
	0-10	11-20	21-30	31-40	41-50	51-60	>60	
Nonneoplastic bone lesions								
Aneurysmal bone cyst (3)	1	1	1	-	-	-	-	3
Chronic osteomyelitis (5)	1	-	-	1	-	1	2	5
Fibrous dysplasia (1)	-	1	-	-	-	-	-	1
Fracture callus (4)	-	-	1	-	-	1	2	4
Intracortical xanthoma (1)	-	-	-	-	-	1	-	1
Macroductyly (1)	1	-	-	-	-	-	-	1
Cemento-ossifying fibroma (1)	-	-	1	-	-	-	-	1
Ossifying fibroma (2)	1	-	-	-	1	-	-	2
Spondylosis (1)	-	-	-	-	-	-	1	1
Xanthogranulomatous osteomyelitis (2)	-	-	-	-	2	-	-	2
Benign tumours								
Giant cell tumour (7)	1	1	3	0	1	1	-	7
Osteochondroma (7)	3	3	1	-	-	-	-	7
Malignant tumours								
Chondroblastic osteosarcoma (2)	2	-	-	-	-	-	-	2
High-grade osteosarcoma (2)	-	-	-	2	-	-	-	2
Chondrosarcoma (1)	-	-	-	-	-	-	1	1
Ewing sarcoma/PNET (2)	1	1	-	-	-	-	-	2
Metastatic adenocarcinoma (2)	-	-	-	-	-	1	1	2
Metastatic SCC (3)	-	-	1	-	1	-	1	3
Sub-total, <i>n</i> (%)	11	7	8	3	5	5	8	47 (60.0)
Nonneoplastic joint lesions								
Ganglion cyst (20)	4	4	2	2	1	3	4	20
Tophaceous gout arthritis (3)	-	-	-	-	-	2	1	3
Hypertrophic synovium (1)	-	-	-	-	-	1	-	1
Rheumatoid nodule (1)	1	-	-	-	-	-	-	1
Synovial cyst (3)	-	-	-	-	2	-	1	3
Benign tumours								
Nodular tenosynovitis (4)	-	1	-	1	-	1	1	4
Synovial Hemangioma (3)	1	-	1	-	1	-	-	3
Synovial angiomyolipoma (1)	-	-	-	1	-	-	-	1
Lipoma arborescens (1)	-	-	1	-	-	-	-	1
Malignant (nil)								
Sub-total, <i>n</i> (%)	6	5	4	4	4	7	7	37 (40.0)
Total, <i>n</i> (%)	16	12	12	7	9	12	15	84 (100.0)

PNET: Peripheral neuroectodermal tumour, SCC: Squamous cell carcinoma

in confirming the diagnosis. Histopathology also helps in predicting the prognosis based on cytomorphological criteria as well as in staging the tumours to aid the surgeon in planning limb salvage surgery for early malignant or benign bone lesions.^[1-3] It is therefore of utmost importance to highlight these lesions in other to provide awareness so as to prevent morbidity and mortality associated with advanced stage of presentations of these lesions.

In this study, a total of 84 lesions were reviewed which included 47 (47/84; 56.0%) cases of bone and 37 (37/84; 44.0%) cases of joint lesions. The bone lesions were far more common than joint lesions in our study, this may be attributed to nonbiopsies of most joint lesions, especially osteoarthritis associated with aging, which usually undergo conservative treatment with prescribed or traditional medications. Of the 47 bone lesions,

31 (37.0%) cases were male and 16 (19.0%) cases were female giving a M: F ratio of 2:1. The gender ratio was similar in observations in most parts of Nigeria: Zaria (M: F = 1.5:1), Lagos (M: F = 1.5:1), and Ile-Ife (M: F = 1.3:1) and other parts of the world such as North America (Mexico City) (M: F = 1.6:1); Iran (M: F = 1.5:1); in Gujarat, India (M: F = 1.5:1); and Mahabubnagar, India (M: F = 1.2:1).^[4,6,10-14] The age range of bone lesions in this study was 2–80 years with majority of cases (55.3%) seen within the 2–30 years' age group. This was also in keeping with most studies. The age range in Zaria, North West Nigeria, was 4–72 years with 75% of cases seen within 11–20 years and Jos, North Central Nigeria, also had an age range of 3–75 years with majority of cases seen in younger age group while Lagos had an age range of 7.5–62 years with a peak age at 11–20 years.^[10,11,15] Studies

Table 3: Anatomic distributions of the lesions of bones

Histological types (<i>n</i>)	Locations												Total
	Skull	Shoulder	Humerus	R/U	Foot	Femur	T/F	Spine	Sternum	Knee	Leg	Bone marrow	
Bone lesions													
Aneurysmal bone cyst (3)	-	-	-	-	1	-	1					1	3
Chronic osteomyelitis (5)	1	2	-	-		-	1					1	5
Fibrous dysplasia (1)	-	-	-	-	1	-	-						1
Fracture callus (4)	2	-	-	-		-	-	1		1			4
Intracortical xanthoma (1)	-	-	-	-		-	-					1	1
Macroductyly (1)	-	-	-	-	1	-	-						1
Cement-ossifying fibroma (1)	1	-	-	-		-	-						1
Ossifying fibroma (2)	2	-	-	-		-	-						2
Spondylosis (1)	-	-	-	-		-	-	1					1
Xanthogranulomatous osteomyelitis (2)	-	-	-	-	1	-	-					1	2
Benign tumours													
Giant cell tumour (7)	-	-	-	3	1	-	1					2	7
Osteochondroma (7)	-	1	3	-		2	1						7
Malignant tumours													
Chondroblastic osteosarcoma (2)	-	-	2	-		-	-						2
High-grade osteosarcoma (2)	-	-	-	-		-	-				2	-	2
Chondrosarcoma (1)	-	1	-	-		-	-						1
Ewing sarcoma/PNET (2)	1	-	-	-		1	-						2
Metastatic adenocarcinoma (2)	-	-	-	-		-	-	1	1				2
Metastatic SCC (3)	-	-	1	-		-	-	1	1				3
Total	7	4	6	3	5	3	4	4	2	1	2	6	47

PNET: Peripheral neuroectodermal tumour, SCC: Squamous cell carcinoma, R/U: Radius & Ulna, T/F: Tibia & Fibula

Table 4: Anatomic distributions of the lesions of joint

Histological types (<i>n</i>)	Locations								Total
	Finger	Knee	Wrist	Foot	Ankle	Elbow	Spine	Bone marrow	
Nonneoplastic lesions									
Ganglion cyst (20)		1	13	4	1		1		20
Tophaceous gout arthritis (3)	1					2			3
Hypertrophic synovium (1)								1	1
Rheumatoid nodule (1)						1			1
Synovial cyst (3)		1				2			3
Benign									
Nodular tenosynovitis (4)	4								4
Synovial hemangioma (3)		2			1				3
Synovial angiomyolipoma (1)		1							1
Lipoma arborescens (1)					1				1
Malignant (nil)									0
Total	5	4	13	4	3	5	1	1	37

outside Nigeria also had similar reports, Hathila *et al.* in Gujarat, India, reported that bone lesions were more common in younger age group (11–30 years), and it constituted 58.2% of all cases, while in Iran study, the age range was 4–84 years with peak age within 5–25 years.^[4,14]

Twenty-six (55.3%) cases out of 47 bone lesions in this study were neoplastic tumours, while 44.7% (21/47) were nonneoplastic bone lesions. Neoplastic lesions were found to be more common than nonneoplastic lesions, which is in conformity with studies done by Mohammed and Isa in Zaria;

Aina *et al.* in Ile-Ife, South West Nigeria; Settakorn *et al.* in Thailand; Kethireddy *et al.*; and Hathila *et al.* in India.^[4,6,10,12,16]

In our study, we also observed that benign bone tumours (14/26) were more common than malignant counterpart (12/26). Benign bone tumours constituted two-third (53.8%; 14/26) of all bone tumours in our study. This finding agreed with studies within and outside Nigeria: Jos (66.7%), Lagos (53.7%); Mahabubnagar, India (89.2%); Iran (50.0%); and Mexico City (71.6%), but several other reports including studies from Zaria, Ile-Ife, maintained higher percentage of malignant bone tumours.^[6,10-16] A study in Ile-Ife, South West Nigeria, reported 50.0% of malignant bone tumours and 28.0% of benign and 22.0% of tumour-like lesions while Zaria, North West Nigeria, reported 39.4% malignant bone tumours and 38.6% of benign tumours with 22.0% tumour-like lesions.^[10,11] Giant cell tumour and osteochondroma were the most common benign neoplastic tumours seen in this study. This is in tandem with most studies within and outside Nigeria.^[10-16]

Primary bone tumours were, however, more common than secondary tumours. The total primary bone tumours in our study were 80.0% (21/26) with only five cases of metastatic bone disease. This agreed with most studies.^[10,11,13,14] Out of 26 bone tumours seen in this study, 12 cases were malignant bone tumours constituting 46.2% with osteosarcomas and metastatic bone diseases being the most common bone malignancies in our study. Most studies reported osteosarcoma as the most common bone malignancy followed in some studies by metastatic bone diseases.^[4,6,10-16] In the United Kingdom, around 560 new cases of bone sarcomas are diagnosed yearly.^[17] In Italy, an average of 1.3 new malignant bone tumours are diagnosed per 100,000 males/year and 1.1 per 100,000 females/year.^[5] The overall incidence rate for bone and joint malignancy in the United States is 0.9 per 100,000 persons per year.^[5] Trinidad and Tobago has an incidence of 1.125 per 100,000 populations annually, while Cameroon has an average incidence of 27 tumours a year or two per one million inhabitants.^[18,19]

Among the nonneoplastic bone lesions in this study, osteomyelitis was the most common lesion accounting for 33.3% (7/21) followed by fracture callus (4/21; 19.0%). It occurred more common in ages above 40 years (5/7; 71.4%) with a M: F ratio of 2:1. This is similar to a report by Kethireddy *et al.* in India who reported chronic osteomyelitis as the most common nonneoplastic bone lesion comprising 38.9% followed by tuberculous osteomyelitis (22.2%) but differs from a study by Hathila *et al.* also in India who reported tuberculosis as the most common nonneoplastic condition followed by chronic osteomyelitis.^[4,5]

Skull was the most common anatomic site for all bone lesions with 14.9% (7/47) followed by the humerus (12.8%). However, humerus was the most common anatomic site for bone tumours in our study, with 19.2% (5/26) followed by femur and tibia with (12.0%) 3/47 each. Nevertheless, other studies reported

femur followed by tibia, then humerus as the most common location for bone tumours.^[4,6,13,14] However, Mohammed and Isa in Zaria reported face as the most common site for bone tumours and tumour-like lesions similar to our study.^[10]

Our study also observed 37 cases of joint lesions, out of which 28 cases were nonneoplastic and 9 cases were all benign neoplastic tumour, no malignant joint lesion was seen. Ganglion cyst (20/28) was the most common joint lesion, and occurred in all age groups with wrist as the most common anatomic site followed by foot. Nodular tenosynovitis (4/9) was the most common benign joint tumour. These observations agreed with Horvai and Weidner *et al.* who reported that ganglion was much more common than joint neoplasm and it occurred commonly at the wrist.^[2,3] They also concluded that the primary neoplasms of the joint are rare and usually benign, with the malignant counterpart being extremely uncommon.^[2,3]

CONCLUSION

Skeletal lesions are uncommon in our environment and involve mostly bone and joint with associated cartilages and tendons. It has slight male predominant in bony lesions and vice versa for joint lesions, with nonneoplastic lesions being the most common followed by benign tumours. We also noted that joint malignancies are extremely rare while bone malignancies are majorly osteosarcoma and metastasis with associated morbidity and mortality. We, therefore, recommend a prompt biopsy of any skeletal lesion to make early and accurate diagnosis and initiate immediate treatment to prevent advanced presentation.

Acknowledgment

Special appreciation to Ezech Ebere. E for her assistance in the data entry for this work. We also appreciate the histopathology laboratory records staff for their assistance in the provision of all necessary records used in the preparation of this work.

Financial support and sponsorship

Nil.

Conflicts of interest

There are no conflicts of interest.

REFERENCES

1. Maclean FM, Fiona S, Bovee JV. Joint, bone non-neoplastic and bone tumours. In: Sternberg SS, Millis SE, Carter D, editors. *Sternberg Diagnostic Surgical Pathology*. 7th ed. Philadelphia: Lippincott Williams and Wilkins; 2022. p. 675-846.
2. Horvai A. Bones, joints, and soft tissue tumours. In: Kumar V, Abbas AK, Sausto N, Aster JC, editors. *Robbins and Cotran Pathologic Basis of Disease*. 9th ed. Philadelphia: Elsevier Saunders; 2015. p. 1179-218.
3. Weidner N, Lin YG, Kyriakos M. Joint and bone pathology. In: Weidner N, Cote RJ, Suster S, Weiss LM, editors. *Modern Surgical Pathology*. 2nd ed. Philadelphia: Elsevier Saunders; 2009. p. 1784-828.
4. Hathila RN, Mehta JR, Jha BM, Saini PK, Dudhat RB, Shah MB. Analysis of bone lesions in tertiary care centre – A review of 79 cases. *Int J Med Sci Public Health* 2013;2:1037-40.
5. Franchi A. Epidemiology and classification of bone tumours. *Clin Cases Miner Bone Metab* 2012;9:92-5.
6. Kethireddy S, Raghu K, Chandra Sekhar KP, Babu YS, Dash M.

- Histopathological evaluation of neoplastic and non-neoplastic bone tumours in a teaching hospital. *J Evol Med Dent Sci* 2016;5:6371-4.
7. Obalum DC, Eyesan SU, Ogo CN, Enweluzo GO. Multicentre study of bone tumours. *Niger Postgrad Med J* 2010;17:23-6.
 8. Omololu AB, Okolo CA, Ogunlade SO, Oyebadejo TY, Adeoye AO, Ogunbiyi JO, *et al.* Primary malignant bone tumours in Ibadan, Nigeria: An update. *Afr J Med Med Sci* 2009;38:77-81.
 9. Pearce MS, Parker L, Windebank KP, Cotterill SJ, Craft AW. Cancer in adolescents and young adults aged 15-24 years: A report from the North of England young person's malignant disease registry, UK. *Pediatr Blood Cancer* 2005;45:687-93.
 10. Mohammed A, Isa HA. Pattern of primary tumours and tumour-like lesions of bone in Zaria, northern Nigeria: A review of 127 cases. *West Afr J Med* 2007;26:37-41.
 11. Obalum DC, Giwa SO, Banjo AF, Akinsulire AT. Primary bone tumours in a tertiary hospital in Nigeria: 25 year review. *Niger J Clin Pract* 2009;12:169-72.
 12. Aina OJ, Adelusola KA, Orimolade AE, Akinmade A. Histopathological pattern of primary bone tumours and tumour-like lesions in Ile-Ife, Nigeria. *Pan Afr Med J* 2018;29:193.
 13. Baena-Ocampo Ldel C, Ramirez-Perez E, Linares-Gonzalez LM, Delgado-Chavez R. Epidemiology of bone tumours in Mexico City: Retrospective clinicopathologic study of 566 patients at a referral institution. *Ann Diagn Pathol* 2009;13:16-21.
 14. Solooki S, Vosoughi AR, Masoomi V. Epidemiology of musculoskeletal tumours in Shiraz, south of Iran. *Indian J Med Paediatr Oncol* 2011;32:187-91.
 15. Ode MB, Misauno MA, Nwadiaro HC, Onche II, Shitta AH, Amupitan I. Pattern and distribution of primary bone tumours in Jos Nigeria. *IOSR J Dent Med Sci* 2014;13:09-12.
 16. Settakorn J, Lekawanvijit S, Arpornchayanon O, Rangdaeng S, Vanitanakom P, Kongkarnka S, *et al.* Spectrum of bone tumours in Chiang Mai University Hospital, Thailand according to WHO classification 2002: A study of 1,001 cases. *J Med Assoc Thai* 2006;89:780-7.
 17. ESMO/European Sarcoma Network Working Group. Bone sarcomas: ESMO Clinical Practice Guidelines for diagnosis, treatment and follow-up. *Ann Oncol* 2014;25 Suppl 3:iii113-23.
 18. Ramdass MJ, Mooteeram J, Beharry A, Mencia M, Barrow S. An 8-year analysis of bone tumours in a Caribbean island. *Ann Med Surg (Lond)* 2015;4:414-6.
 19. Bahebeck J, Atangana R, Eyenga V, Pisoh A, Sando Z, Hoffmeyer P. Bone tumours in Cameroon: Incidence, demography and histopathology. *Int Orthop* 2003;27:315-7.