

Oral Histopathological Diagnosis: A 6-Year Audit at a Tertiary Hospital in Gombe, North-East Nigeria

Babatunde Oludare Fakuade¹, Efetobo Victor Orikpete², Obitade Sunday Obimakinde³, Aliyu Ibrahim Lawan⁴, Olufemi Gbenga Omitola²

¹Department of Dental/Maxillofacial Surgery, Federal Teaching Hospital, ⁴Department of Histopathology, Federal Teaching Hospital, Gombe State University, Gombe, ²Department of Oral Pathology and Oral Biology, Faculty of Dentistry, College of Health Sciences, University of Port Harcourt, ³Department of Oral and Maxillofacial Surgery, Ekiti State University, Ekiti State University Teaching Hospital, Ekiti, Nigeria

Abstract

Background: Tissue biopsy is an established method of diagnosis which helps in establishing the various types of lesions. However, contrasting findings may exist depending on facility, personnel available, and geographical region. **Aim:** To carry out a six-year audit of oral lesions diagnosed through histopathology in our institution. **Materials and Methods:** This was a retrospective review of all histopathologically diagnosed oral lesions within a six-year period. Information retrieved from the patients' record and analyzed were age, sex, occupation, site, and histological diagnosis. Descriptive statistics of frequency, percentage, mean, and standard deviation were presented. **Results:** Two hundred and forty-two oral biopsies consisting of 130 females and 112 males were performed during the study period. Patients age ranged from 1 to 82 years with a mean of 30.2 ± 17.6 years. Lesions were mostly located on the mandible and were mainly benign in nature. The most common benign lesion was ameloblastoma, whereas the most common malignant lesion was squamous cell carcinoma. **Conclusion:** The prevalence and pattern of presentation of oral lesions in our center are similar to the previous reports from Nigeria and other parts of the world. There is a need to increase the awareness about oral health and availability of oral histopathological services in our center to improve utilization.

Keywords: Audit, histopathology, oral

INTRODUCTION

Biopsies are important for the establishment of abnormal growth and diagnosis of oral lesions.^[1] The orofacial structures consist of different types of tissues which include connective tissue, muscle, bone, cartilage, salivary glands as well as the teeth, which are unique to the mouth. These tissues when subjected to different pathologic conditions will require histopathological diagnosis.

Histological diagnosis of oral lesions is done by trained oral pathologists in well-established centers in Nigeria, but scarcity of personnel in this specialty, in our centre and other facilities have yielded the role of interpretations of oral biopsies to nonoral pathologists. It is a known fact that in established centres, prior to the engagement of oral pathologist, confirming any empirical diagnosis was done by the general pathologist.^[2] It has also been reported that due to scarcity of oral pathologists in sub-Saharan Africa, the dependence on the general pathologist for interpretation of oral histopathological slides will still persist.^[3-6]

There is a variation in the reported prevalence of oral lesions in different parts of the world. This has been attributed to exposure to different etiologic factors and different cultural and environmental factors.^[7-9] Thus, there is a need to establish the pattern for a particular environment, as this can be an aid to clinicians when formulating a clinical diagnosis. Previous reports mostly from centers in southern Nigeria and foreign literature were studies which include patients of all age groups.^[2,8-12] However, there is dearth of oral histopathology studies from Northern Nigeria. To the best of our knowledge, there is no report from the north-eastern Nigeria where our institution is located.

Address for correspondence: Dr. Babatunde Oludare Fakuade, Department of Dental/Maxillofacial, Federal Teaching Hospital, Gombe, Nigeria.
E-mail: ketretees31@gmail.com

This is an open access journal, and articles are distributed under the terms of the Creative Commons Attribution-NonCommercial-ShareAlike 4.0 License, which allows others to remix, tweak, and build upon the work non-commercially, as long as appropriate credit is given and the new creations are licensed under the identical terms.

For reprints contact: WKHLRPMedknow_reprints@wolterskluwer.com

How to cite this article: Fakuade BO, Orikpete EV, Obimakinde OS, Lawan AI, Omitola OG. Oral histopathological diagnosis: A 6-year audit at a tertiary hospital in Gombe, North-East Nigeria. *Niger J Med* 2022;31:681-5.

Submitted: 13-Nov-2022

Revised: 24-Dec-2022

Accepted: 02-Jan-2023

Published: 28-Feb-2023

Access this article online

Quick Response Code:



Website:
www.njmonline.org

DOI:
10.4103/NJM.NJM_117_22

The aim of this study was therefore to determine the prevalence and pattern of presentation of histologically diagnosed oral lesions in Federal Teaching Hospital Gombe. We believe this will add to the existing body of knowledge on this subject.

MATERIALS AND METHODS

This was a retrospective review of all cases of orofacial lesions diagnosed through histopathology at the Federal Teaching Hospital Gombe over a six-year period from January 2016 to December 2021. The diagnosis were made by the general pathologists in the hospital because there is no resident oral pathologist in the center. Approval for the study was obtained from our institution’s Ethical Board before the commencement of the study. Archival records of all the patients were obtained and the following information was extracted from the patients’ records: Age, sex, occupation, site of lesions, and histological diagnosis. Each lesion was determined to either be benign or malignant. The various lesions were then categorized in seven broad diagnostic groups: odontogenic tumors, salivary gland tumors, connective tissue tumors, epithelial tumors, orofacial cystic lesions, fibrous lesions, and inflammatory/reactive lesions. The data obtained were inputted into Microsoft EXCEL spreadsheet and analysed with Statistical Package for Social Sciences (SPSS) IBM SPSS Statistics for Windows, Version 26.0. (Armonk, NY: IBM Corp). Descriptive statistics of frequency, percentage, mean, and standard deviation were presented.

RESULTS

This study showed that a total of 242 participants had orofacial lesions which were biopsied for histologic diagnosis. Of these, there were 130 (53.7%) females giving a female-to-male (F: M) ratio of 1.2:1. The patients’ age ranged from 1 to 82 years, with a mean age of 30.2 ± 17.6 years. The distribution of the studied participants based on gender across defined age groups indicate that the proportion of those aged 11–20 years constituted 59 (24.4%), it was followed by those aged 21–30 years, 57 (23.6%) and 29 (11.9%) involving those aged 41–50 years.[Table 1] Stratification based on occupations indicates that 65 (26.8%) were homemakers, 76 (31.4%) were students while 15 (6.2%) were civil servants [Figure 1]. Majority of the study participants were from the Hausa (36.4%) and Fulani tribes (26.7%) [Figure 2].

The most common site of presentation of the lesions was the mandible with 98 (38.9%). The next most common sites are the maxilla 59 (24.4%), followed by the palate with 23 (9.5%). The sites with the least lesions were the scalp 2 (0.8%) and the upper lip 1 (0.4%). The site distribution of the lesions is as shown in Table 2.

Benign lesions were 193 (79.8%) while 49 (20.2%) lesions were malignant [Figure 3]. The commonest lesions were the odontogenic tumors with 51 cases, representing 21.1% of all the lesions [Figure 4]. Among the odontogenic tumors,

ameloblastoma represented the single most common lesion with 35 cases, this accounted for 14.5% of all the lesions and 68.6% of the odontogenic tumors. The next most common individual lesions were pleomorphic adenoma, squamous cell carcinoma, and ossifying fibroma with 19 cases each. The connective tissue

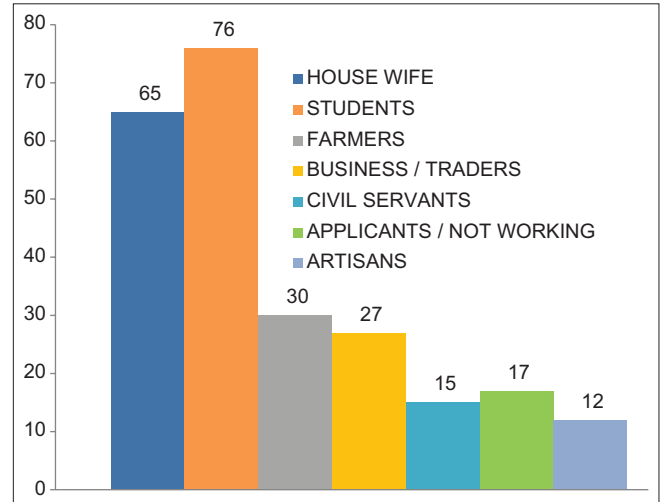


Figure 1: Distribution of patients in this study by occupation

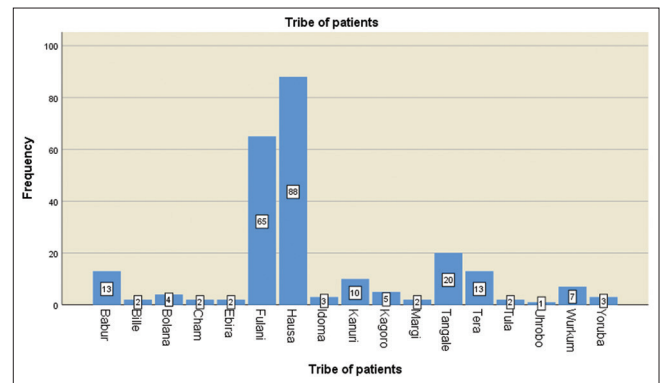


Figure 2: Distrubution of the various tribes of the study participants

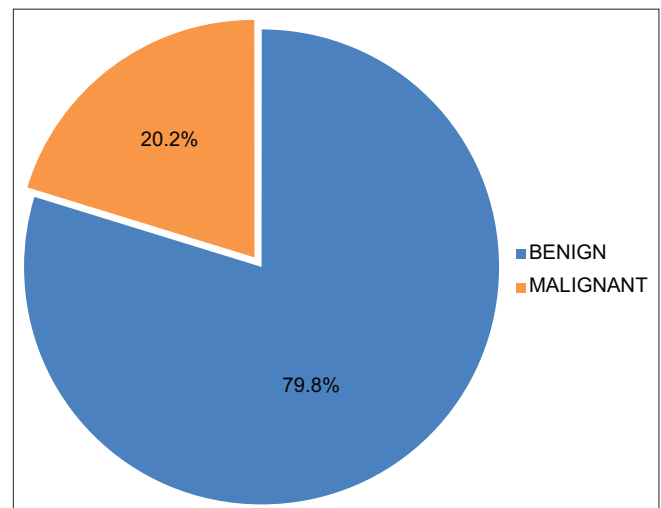


Figure 3: Nature of the lesions encountered in this study

Table 1: Age and gender distribution of patients

Age group (years)	Female, n (%)	Male, n (%)	Frequency, n (%)
1-10	15	13	28 (11.6)
11-20	31	28	59 (24.4)
21-30	27	30	57 (23.6)
31-40	23	13	36 (14.9)
41-50	20	9	29 (11.9)
≥51	14	19	33 (13.6)
Total	130 (53.7)	112 (46.3)	242 (100.0)

Table 2: Site distribution of the lesions

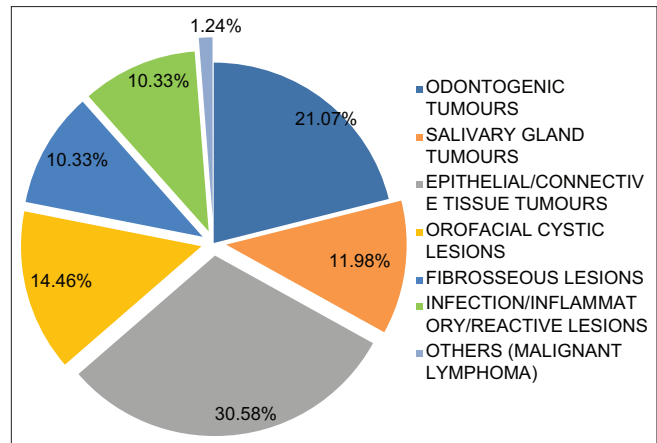
Site	Frequency, n (%)
Mandible	94 (38.9)
Maxilla	59 (24.4)
Palate	23 (9.5)
Cheek	15 (6.2)
Floor of the mouth	11 (4.5)
Submandibular area	11 (4.5)
Tongue	11 (4.5)
Parotid gland	10 (4.1)
Upper lip	5 (2.1)
Scalp	2 (0.8)
Lower lip	1 (0.4)
Total	242 (100.0)

lesions with 47 (19.4%) cases were the second most common group behind the odontogenic tumors. Other groups of lesions seen in the order of frequencies were cystic lesions (36, 14.8%), salivary gland tumors (29, 11.9%), epithelial lesions (27, 11.1%), fibro-osseous lesions (25, 10.2%) and infection, inflammatory and reactive lesions (25, 10.2%) [Table 3].

DISCUSSION

In this study, 242 oral biopsies were done within the six-year study period giving an average of about 40 oral biopsies per year. This is low as compared to previous reports by Omitola *et al.*^[10] (Port Harcourt), Akinyamoju *et al.*^[2] (Ibadan) both in Nigeria and foreign studies by Oliveira *et al.*^[3] (Brazil) and Ali *et al.*^[13] (Saudi Arabia).^[2,3,10,13] The reason for this low rate of utilization of oral biopsy service in our center may be due to any of the following reasons: lack of resident oral pathologist,^[7] poor awareness of the availability of oral histopathology service in the community, paucity of funds and general poor awareness of oral health in the state, culminating in a relative fewer number of people from adjoining centers that is supposed to bring samples, thereby boosting the FTH samples, as seen in bigger centers like Port Harcourt and Ibadan, respectively.

The proportion of females in this study is higher than that of males, this is similar to the observation of Akinyamoju *et al.* and Ali *et al.*^[2,13] but differs from that of Omitola *et al.* and Chidzonga *et al.*,^[10,14] who reported male predominance. Having a female predominance in this study and that of Ali

**Figure 4: Histological class of the lesions in this study**

et al.^[13] which were done in regions where culturally, there are restrictions to free movements of women, can affirm or lay credence to the general belief that females tend to take care of their health more than males. The mean age of 30.2 years reported in this study is similar to 30.9 years reported by Omitola *et al.*^[10] but lower than 34.9 years reported by Ali *et al.*, 36.7 by Akinyamoju *et al.* and 38.0 reported by Moridani *et al.*^[2,9,13] Furthermore, oral lesions were most predominantly seen within the 2nd and 3rd decades of life, this is similar to the observation of Akinyamoju *et al.*^[2] who reported 3rd decade but differs from the 5th decade reported by Takashima and Etges.^[15] The reason for these differences may be due to the pattern of utilization of the oral biopsy services and exposure to the etiological factors in the different communities.

The mandible was the most common site for these lesions, an observation that has been reported by others.^[2,9,10] The reason for the mandibular predominance of orofacial lesions is not known, however, Takashima and Etges^[15] reported a maxillary predominance in their study.

Benign lesions were the most frequently diagnosed lesions in this study. This is similar to the findings of most other studies.^[2,3,9-13] The reason for this observation is not clear, but it may reflect the true prevalence of these lesions in the community.

The most common group of lesions diagnosed in this study was odontogenic tumors. This differs from the study of Akinyamoju *et al.* and Moridani *et al.*^[2,9] who reported reactive lesions as their most common lesions. This finding may reflect the pattern of utilization of oral diagnostic services in different parts of Nigeria and the world. While it will take reactive lesions for people to seek oral health care in areas where there is good awareness of oral lesions, it takes disfigurement from a big lesion usually associated with odontogenic tumors for others to seek care. The single most common lesion reported in this study was ameloblastoma representing 14.5% of all lesions and 68.6% of odontogenic tumors. This is similar to the findings of Akinyamoju *et al.* in Ibadan, Omitola *et al.* in Port

Table 3: Histological types of the various lesions encountered in this study

Class of lesion	Histological diagnosis	Frequency, n (%)
Odontogenic tumours	Ameloblastoma	35
	Odontogenic myxoma	5
	Ameloblastic fibroma	4
	Adenomatoid odontogenic tumour	2
	Odontoma	2
	Ameloblastic carcinoma	3
	Subtotal	51 (21.1)
Salivary gland tumours	Pleomorphic adenoma	19
	Mucoepidermoid carcinoma	5
	Adenocystic carcinoma	2
	Polymorphous low grade adenocarcinoma	2
	Carcinoma ex-pleomorphic adenoma	1
	Subtotal	29 (11.9)
Connective tissue tumours	Fibroma	15
	Heamangioma	6
	Lipoma	6
	Neurofibroma	6
	Schwanoma	1
	Osteoma	1
	Osteosarcoma	6
	Rhadomyosarcoma	3
	Fibrosarcoma	2
	Liposarcoma	1
	Subtotal	47 (19.4)
Epithelial tumours	Papilloma	5
	Neuroectodermal tumour of infancy	1
	Squamous cell carcinoma	19
	Melanoma	1
	Metastatic carcinoma	1
Subtotal	27 (11.3)	
Orofacial cystic lesions	Dentigerous cyst	12
	Radicular cyst	4
	Calcifying odontogenic cyst	1
	Ranula	10
	Dermoid/epidermoid cyst	8
Subtotal	35 (14.5)	
Fibroosseous lesions	Ossifying fibroma	19
	Fibrous dysplasia	6
	Subtotal	25 (10.3)
Inflammatory/reactive lesions	Inflammatory lesion	13
	Pyogenic granuloma	12
	Subtotal	25 (10.3)
Others	Malignant lymphoma	3
	Subtotal	3 (1.2)
	Grand total	242 (100.0)

Harcourt and Bassey *et al.* in Calabar all in Nigerian.^[2,10,16] This differs from findings from outside Nigeria were lesions like fibrous epulis, fibrous hyperplasia, and inflammatory fibrous hyperplasia were more frequently reported.^[7,15,17] This may be due to the prevalence of odontogenic tumors especially ameloblastoma among black Africans.

The prevalence of cystic lesions in this study was 14.8%. This falls within the reported prevalence of 0.8%–49% for these lesions.^[16,18] Dentigerous cyst was the most commonly reported cyst. This is similar to what has been reported in Kano and Port Harcourt in Nigeria^[19,20] also in Kenyan and Indian populations.^[21,22] Ossifying fibroma was the most common fibrous osseous lesion diagnosed in our center. This agrees with previous reports from Nigeria and Ghana^[23-25] but differs from the observation from the Western world where fibrous dysplasia was the prevalent fibroosseous lesion.^[26] This reason for the difference in prevalence is not known.

As regards malignant lesions, the prevalence of 20.2% reported in this study is higher than 13.7% reported by Bassey *et al.*^[16] in a similar study in Calabar but lower than 25.6% reported in Ibadan, Nigeria^[2] and far lower than 67.3% reported in Muhimbili and Mulago located in East Africa.^[27] It is known that the prevalence of malignant lesions varies from one region to another, and this depends on the exposure to different etiological agents found in that region. This may be the reason for the observed differences. Squamous cell carcinoma was the most common malignant lesion in this series, and agrees with report of other studies from Nigeria.^[2,16,28]

Among the participants reviewed over the period of this study, Hausa has the highest number while the Fulani tribe follows in rank. This might be due to the region of study and due to the fact that these are the two leading tribes within the region where this study was conducted.

CONCLUSION

The prevalence and pattern of presentation of orofacial lesions reported in this study is similar to what has been reported from other parts of Nigeria and some other parts of the world. Lesions are more common in females and on the mandible and are mainly benign in nature and present mainly in the second and third decades of life. Ameloblastoma is the most common lesion overall while squamous cell carcinoma is the most common malignant lesion.

Recommendation

There is a need to increase the awareness of oral health and availability of oral biopsy services in the center to improve the utilization of the service and in the prompt holistic health management in the community. There is need for the hospital management to employ the service of a core specialist in oral histopathology for upscale oral diagnosis.

Financial support and sponsorship

Nil.

Conflicts of interest

There are no conflicts of interest.

REFERENCES

- Regezi JA. Odontogenic cysts, odontogenic tumors, fibroosseous, and giant cell lesions of the jaws. *Mod Pathol* 2002;15:331-41.

2. Akinyamoju AO, Adeyemi BF, Adisa AA, Okoli CN. Audit of oral histopathology service at a Nigerian tertiary institution over a 24-year period. *J Health Sci* 2017;27:383-9.
3. Oliveira e Silva KR, Siqueira AL, Caldeira PC, de Abreu MH, de Aguiar MC. Profile of usage of a reference diagnostic service on oral pathology: A 10-year evaluation. *BMC Health Serv Res* 2014;14:653.
4. Adeyi OA. Pathology services in developing countries – The West African experience. *Arch Pathol Lab Med* 2011;135:183-6.
5. Rambau PF. Pathology practice in a resource-poor setting: Mwanza, Tanzania. *Arch Pathol Lab Med* 2011;135:191-3.
6. Benediktsson H, Whitelaw J, Roy I. Pathology services in developing countries: A challenge. *Arch Pathol Lab Med* 2007;131:1636-9.
7. Franklin CD, Jones AV. A survey of oral and maxillofacial pathology specimens submitted by general dental practitioners over a 30-year period. *Br Dent J* 2006;200:447-50.
8. Jones AV, Franklin CD. An analysis of oral and maxillofacial pathology found in adults over a 30-year period. *J Oral Pathol Med* 2006;35:392-401.
9. Moridani SG, Shaahsavari F, Adeli MB. A 7-year retrospective study of biopsied oral lesions in 450 Iranian patients. *RSBO* 2014;11:118-24.
10. Omitola OG, Obiorah CC, Amakiri CN. Oral biopsy services in Port Harcourt: A review of a year experience. *Port Harcourt Med J* 2010;4:270-7.
11. Wan A, Savage NW. Biopsy and diagnostic histopathology in dental practice in Brisbane: Usage patterns and perceptions of usefulness. *Aust Dent J* 2010;55:162-9.
12. Orikpete EV, Iyogun CA, Omitola OG. Clinicopathologic analysis of biopsied oro-facial lesions seen in children in a tertiary health centre in Port Harcourt: An 11-year review. *J Biosci Med* 2020;8:1-8.
13. Ali AA, Suresha CS, Al-Tamimi D, Al-Nazrc M, Atassi RA, Al-Rayese I, *et al.* A survey of oral and maxillofacial biopsies in the Eastern Province of Saudi Arabia: A 10 years' retrospective study. *J Oral Maxillofac Surg Med Pathol* 2013;25:393-8.
14. Chidzonga MM, Lopez VM, Portilla Alvarez AL. Orofacial biopsies: A survey of 1,723 cases seen over a 10 year period. *Cent Afr J Med* 1996;42:102-8.
15. Takashima MR, Etges A. Epidemiological survey of biopsy performed in a residency program in bucco maxillofacial surgery. *Rev Gaúcha Odontol* 2012;60:337-42.
16. Bassey GO, Osunde OD, Anyanechi CE. Maxillofacial tumors and tumor-like lesions in a Nigerian teaching hospital: An eleven year retrospective analysis. *Afr Health Sci* 2014;14:56-63.
17. Tay AB. A 5-year survey of oral biopsies in an oral surgical unit in Singapore: 1993-1997. *Ann Acad Med Singapore* 1999;28:665-71.
18. Mosadomi A. Tumors, cysts and allied lesions of the jaws and oral mucosa in Lagos, Nigeria, 1969-74. *Int J Oral Surg* 1975;4:219-24.
19. Iyogun CA, Sule AA, Omitola OG. Relative prevalence of odontogenic cysts and tumours in Kano; Northern Nigeria. *J Dent Oral Health* 2017;3:071.
20. Iyogun CA, Orikpete EV, Mbagwu AA, Omitola OG. Odontogenic cyst in Port Harcourt, Nigeria: A 10-year retrospective study. *Niger J Dent Res* 2020;5:1-6.
21. Butt FM, Ogeng'o J, Bahra J, Chindia ML. Pattern of odontogenic and nonodontogenic cysts. *J Craniofac Surg* 2011;22:2160-2.
22. Ramachandra S, Shekar PC, Prasad S, Kumar KK, Reddy GS, Prakash KL, *et al.* Prevalence of odontogenic cysts and tumours: A retrospective clinico-pathological study of 204 cases. *SRM J Res Dent Sci* 2014;5:170-3.
23. Iyogun CA, Darisu N, Omitola OG, Sule AA. Pattern of fibro-osseous lesions of jaws in Port Harcourt: South-South Nigeria. *Ann Med Health Sci Res* 2018;8:186-8.
24. Sule AA, Iyogun CA, Adeyemi TE. Pattern of fibro-osseous lesions of the jaws in Kano, Northern Nigeria. *J Dent Oral Health* 2017;3:1-3.
25. Abdulai AE, Gyasi RK, Iddarissu MI. Benign fibroosseous lesions of the facial skeleton: Analysis of 52 cases seen at the Korle Bu Teaching Hospital. *Ghana Med J* 2004;38:96-100.
26. Eversole LR. Craniofacial fibrous dysplasia and ossifying fibroma. *Oral Maxillofac Surg Clin North Am* 1997;9:625-42.
27. Kamulegeya A, Kalyanyama BM. Oral maxillofacial neoplasms in an East African population a 10 year retrospective study of 1863 cases using histopathological reports. *BMC Oral Health* 2008;8:19.
28. Fakuade BO, Omitola OG, Iyogun CA. Primary malignant oro-facial tumors: A 14-year experience in a tertiary health institution in Gombe, North-East Nigeria. *IOSR J Dent Med Sci* 2018;17:50-4.