

# A Giant Maxillary Odontogenic Myxofibroma Occurring with Pulmonary Mycetoma: A Rare Case Report and Review of Literature

Ayodele Gbenga Akomolafe<sup>1</sup>, Adewale Francis Adejobi<sup>2</sup>, Taofeek Akin Akinniyi<sup>1</sup>, Abiodun Saheed Olatunji<sup>1</sup>, Adewale Charles Adeyemi<sup>1</sup>, Sola Moshood Egunjobi<sup>1</sup>

<sup>1</sup>Department of Oral and Maxillofacial Surgery, Obafemi Awolowo University Teaching Hospital Complex, <sup>2</sup>Department of Oral and Maxillofacial Surgery, Faculty of Dentistry, Obafemi Awolowo University, Ile-Ife, Nigeria

## Abstract

Odontogenic myxoma can present with variable clinical and radiological appearance; therefore, it should be considered in the differential diagnosis of radiolucent and mixed radiolucent–radiopaque lesions of both jaws in all age groups. Whether it can be classified as a myxofibroma or strictly myxoma depends on the amount of collagen it contains, as myxomas generally present as a mucoid ground substance with little collagen. We report a case of myxofibroma of the maxilla, a rare, though benign but locally aggressive odontogenic tumor. Our patient presented as an asthenic, chronically ill-looking, pale, dehydrated but acyanosed young woman. She presented on account of a six-month history of rapidly progressive large mass of the maxilla with extensive destruction of the maxillary bone and displacement of the associated teeth. There was associated history of spontaneous bleeding and intermittent pain. The mass was initially biopsied and diagnosed as desmoplastic fibroma. Chest radiographic findings revealed thin-walled cavitory lesions with characteristic air-crescent signs which was suggestive of left-sided pulmonary mycetoma. The maxillary lesion was treated by surgical excision with peripheral ostectomy. The literature review was done using search engine PubMed, Google Scholar, and Scopus with the following keywords: “Odontogenic myxofibroma,” “odontogenic fibromyxoma,” “odontogenic myxoma” “myxofibroma of the maxilla,” “myxofibroma of the mandible,” “myxofibroma of the jaw,” “fibromyxoma of the jaw” “case report on myxofabroma” and “case series on myxofibroma.” Articles where the amount of fibrous and myxoid tissue were not quantified were excluded from the study.

**Keywords:** Maxilla, odontogenic myxofibroma, pulmonary mycetoma

## INTRODUCTION

Odontogenic myxofibroma (MF) was first described by Virchow in 1863 as a rare benign, locally aggressive tumor that destroys jaw bone and infiltrates the surrounding tissues.<sup>[1]</sup> The lesion is a variant of odontogenic myxoma (OM).<sup>[2]</sup> OM comprises about 3%–6% of all odontogenic tumors and MF account for only a minor percentage of OM, with an incidence of 0.05/1,000,000.<sup>[3,4]</sup>

OM affects more female than male with a predilection for the posterior segment of the mandible. Most of the cases were reported in the second to third decade of life, rarely seen in children and adults.<sup>[4]</sup> MF may be asymptomatic, but as the lesion enlarges, it presents as slowly progressive facial swelling with cortical plate expansion and malocclusion. Other less common features include pain and paresthesia.<sup>[4,5]</sup>

Radiographically, MF presents as either unilocular or multilocular radiolucent lesion usually with a well-defined border. Furthermore, terminologies such as “honeycomb,” “soap bubbles,” “ground glass,” and “tennis racquet threads” have been used to describe the lesion in the literature.<sup>[4]</sup>

The gross appearance of odontogenic MF is mostly unencapsulated, well-delineated masses that can be rubbery,

**Address for correspondence:** Dr. Ayodele Gbenga Akomolafe, Department of Oral and Maxillofacial Surgery, Obafemi Awolowo University Teaching Hospital Complex, Ile-Ife, Nigeria. E-mail: ayodele.akomolafe@npmcn.edu.ng

This is an open access journal, and articles are distributed under the terms of the Creative Commons Attribution-NonCommercial-ShareAlike 4.0 License, which allows others to remix, tweak, and build upon the work non-commercially, as long as appropriate credit is given and the new creations are licensed under the identical terms.

**For reprints contact:** WKHLRPMedknow\_reprints@wolterskluwer.com

**How to cite this article:** Akomolafe AG, Adejobi AF, Akinniyi TA, Olatunji AS, Adeyemi AC, Egunjobi SM. A giant maxillary odontogenic myxofibroma occurring with pulmonary mycetoma: A rare case report and review of literature. *Niger J Med* 2022;31:347-55.

**Submitted:** 08-Mar-2022

**Revised:** 09-Apr-2022

**Accepted:** 03-May-2022

**Published:** 24-Jun-2022

### Access this article online

Quick Response Code:



**Website:**  
www.njmonline.org

**DOI:**  
10.4103/NJM.NJM\_37\_22

squishy, or gelatinous in texture and range in color from gray-white to tan-yellow.<sup>[6]</sup> Microscopically, the tumor is composed of randomly oriented, morphologically bland stellate-to-spindle shaped cells embedded in a loose myxoid extracellular matrix with cells presenting with thin, long cytoplasmic prolongations giving the tissue characteristics of resemblance of immature mesenchyme.<sup>[7]</sup> The background of MF is hyalinized or collagenous. The presence of islands of odontogenic epithelium varies, but these are regarded to be a remnant rather than an integral part of the disease.<sup>[8]</sup>

Jaw resection, excision, and enucleation combined with curettage are the mainstay treatment to prevent recurrence due to MF propensity to infiltrate surrounding soft tissues.<sup>[2]</sup>

We present a case of oral and maxillofacial (OMF) in a 22-year-old female with a painful, rapidly progressive left maxillary swelling, associated with bleeding. The lesion was clinically diagnosed as maxillary osteosarcoma, but incisional biopsy suggested desmoplastic fibroma. Asymptomatic pulmonary mycetoma was discovered on a chest radiograph incidentally. The dilemma of diagnosis of OMF still exists. We will review the clinical presentation, radiographic examination, histological features, differential diagnoses, and management of this rare neoplasm.

## CASE REPORT

A 22-year-old female presented in the OMF surgery outpatient clinic of our center with six-month history of rapidly progressive painful, left maxillary swelling. She had earlier reported at a private tertiary hospital for treatment five weeks prior to presentation but could not afford the cost of treatment. The patient gave no positive history of cigarette smoking or alcohol consumption, but there was a history of spontaneous bleeding from the swelling. There was no associated history of chronic cough or hemoptysis; however, weight loss was severe. She could only tolerate oral fluid intake due to the huge mass.

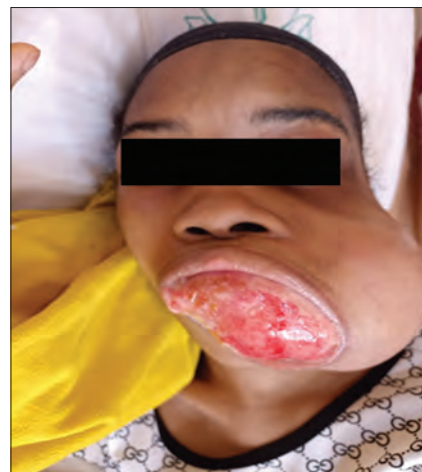Examination revealed an asthenic, chronically ill-looking, pale, and dehydrated but acyanosed patient. There was a left giant maxillary swelling, extending across the midline to the contralateral side and inferior laterally to the mandible on the left side. It measured about 16 cm × 14 cm in its widest diameter. The overlying skin was intact but shiny. It was tender and of mixed consistency on palpation. The ipsilateral submandibular lymph nodes were tender, enlarged, firm, discrete, and freely mobile. Intraoral examination revealed a near-total obliteration of the oral cavity with the lesion projecting through a distended rima oris. There was gross buccopalatal expansion extending from the right first premolar to the contralateral maxillary tuberosity with multiple discharging sinuses [Figure 1]. The left side of the mandibular arch had collapsed lingually due to the pressure effect from the maxillary mass.

Maxillary osteosarcoma was our clinical diagnosis based on age, rapid progression, spontaneous bleeding, and severe weight loss. Craniofacial computed tomography (CT) scan

revealed extensive well-defined isodense lesion predominantly on the left side of the maxilla extending across the midline with complete obliteration of the left maxillary antrum, sparing the orbital floor, cranial base, and infratemporal fossa [Figure 2]. However, preoperative histopathology revealed the diagnosis as desmoplastic fibroma. The duration and nature of the lesion did not support these histopathological findings, leading to a diagnostic dilemma. Immunohistochemistry could not be done due to the unavailability of the markers. A decision was made based on the CT finding and histopathological diagnosis to excise the lesion. Preoperative investigations included full blood count, clotting profile, electrolyte, urea and creatinine, and chest radiograph. Chest roentgenograph revealed thin-walled cavitory lesions with characteristic air-crescent signs. This was an incidental finding. Following patient review by the pulmonologist and cardiothoracic surgeon, a metastasis was ruled out and a diagnosis of a left-sided pulmonary mycetoma was made [Figure 3]. She was commenced on itraconazole 200 mg daily. The hematocrit was 8.3 g/dl. She was optimized before surgery with blood transfusion, nutritional support, and rehydration.

The patient's airway was potentially difficult due to the gigantic tumor size; therefore, elective tracheostomy was done in order to achieve general anesthesia. Access to the lesion was through Dieffenbach's modification of the Weber-Ferguson incision combined with maxillary vestibular incision [Figure 4]. Intraoperatively, the lesion was found to have cleavage, delineating it from the surrounding normal bone. The mass was completely excised along with peripheral osteotomy. Recovery was uneventful. Tracheostomy was discontinued five days following surgery after observing the departmental protocol on decannulation. Figure 5 shows the patient at six-month postoperative

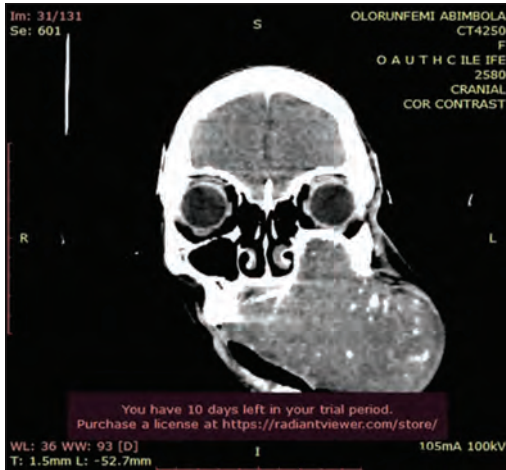The surgical specimen was subjected to histopathology. Macroscopic examination revealed giant, irregularly shaped, grayish brown, and firm tissue mass measuring 15 cm × 13 cm × 7 cm [Figure 6]. Cut surface appears whitish



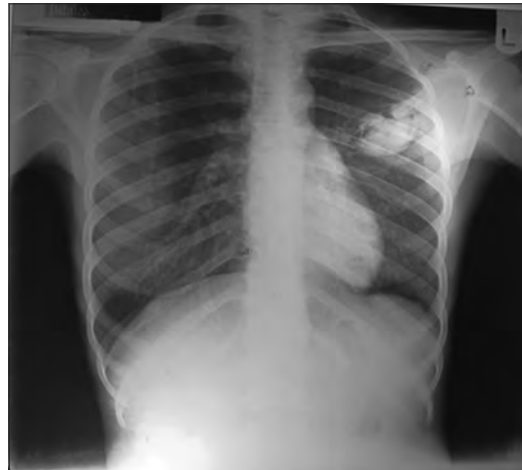**Figure 1:** Preoperative photograph of the patient showing the massive swelling

and slimy, as depicted in [Figure 7]. Microscopy showed predominantly myxoid stroma with spindle-to-stellate-shaped cells interspersed with collagen fibers. The periphery of the

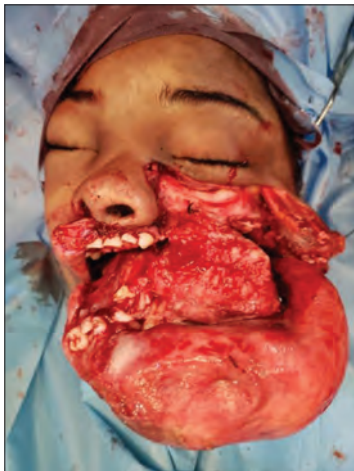lesions displayed predominant fibrous with vascular channels [Figure 8]. Also seen within the lesion are areas of calcific foci resembling cementum [Figure 9 and 10].



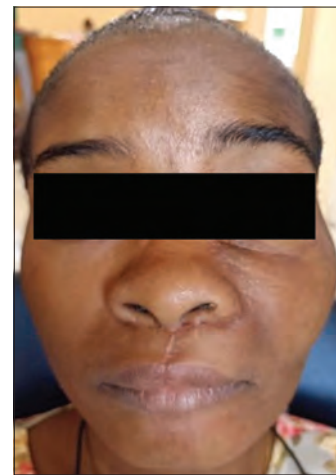**Figure 2:** Computed tomographic scan showing extensive well-defined isodense lesion predominantly on the left side of the maxilla extending across the midline



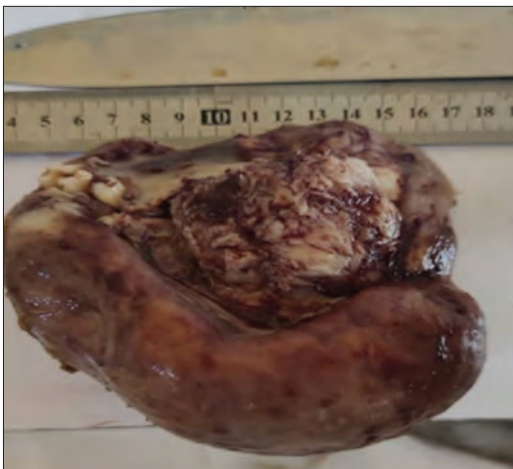
**Figure 3:** Chest X-ray showing a thin-walled cavitary lesion with characteristic air-crescent sign (black arrow)



**Figure 4:** Intraoperative picture with the lesion surgically exposed



**Figure 5:** Six-months postoperative photograph of the patient revealing good healing

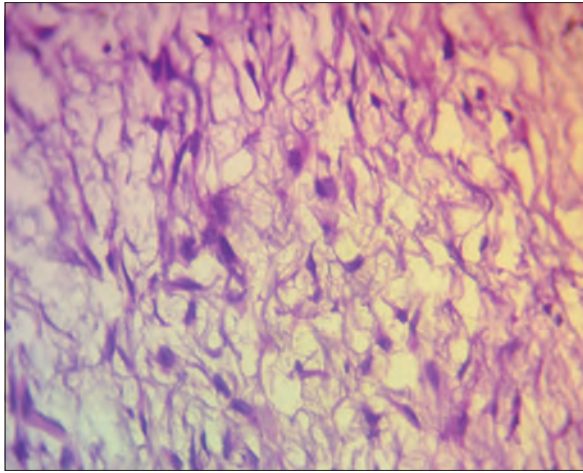


**Figure 6:** Photograph of the resected maxillary jaw tumor fixed in formalin

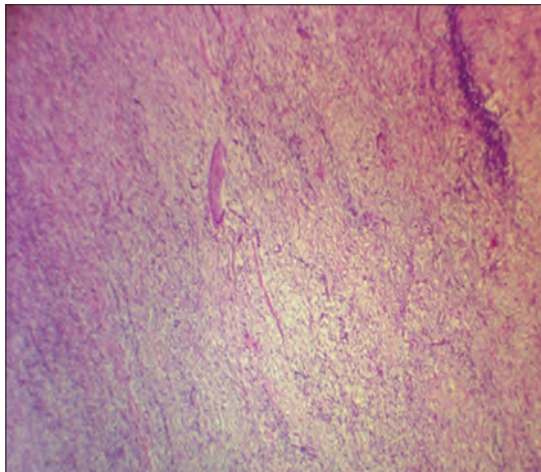


**Figure 7:** Cut surface (white and slimy) of the resected tumor

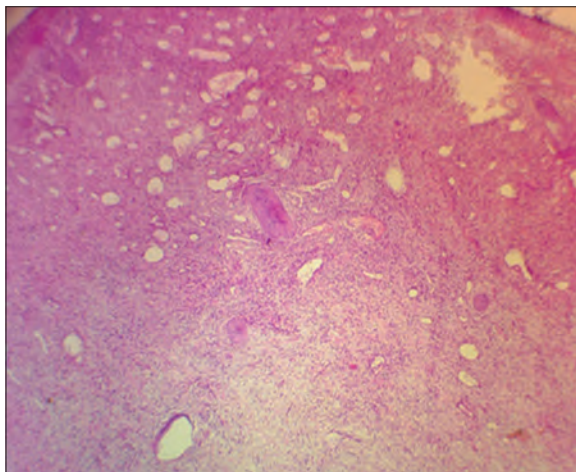




**Figure 8:** Photomicrograph ( $\times 400$ ) showing myxoid stroma with spindle/stellate-shaped fibroblasts



**Figure 9:** Photomicrograph ( $\times 40$ ) of the central area of the lesion showing myxoid and fibrous area with calcified material resembling bone



**Figure 10:** Photomicrograph ( $\times 100$ ) showing periphery of the tumor appearing more fibrous with calcified materials and vascular channels

The patient was discharged two weeks after the surgical procedure with a surgical obturator to facilitate feeding and minimize late wound contracture

## DISCUSSION

MF is widely reported as a benign, painless, slow-growing but locally aggressive tumor that exclusively affects the jaw bones and may arise from the dental follicle, the dental papilla, or the periodontal ligament.<sup>[3,9]</sup> In contrast to the hitherto painless nature of this tumor, the present case presented with a rapidly progressive, massive, painful swelling with associated bleeding mimicking a malignant lesion. This is similar to Meleti *et al.*<sup>[10]</sup> who reported in their systematic review of literature of 15 articles on odontogenic MF that 5 (35.71%) out of the 24 patients had varying degrees of pain. The painful nature of this lesion can be attributed to the large size of the swelling, which could easily be traumatized by projecting associated teeth with resultant injury being infected by oral microbiota. Another reason adduced to the pain is a result of local invasion of surrounding tissues.<sup>[10]</sup> The mandible is found to be more frequently affected than the maxilla, with a predilection for the posterior region in both jaws. In contrast, our patient presented with a massive anterior maxillary swelling. In most cases, MF was discovered during the second and fourth decades of life, with the third decade being the most common.<sup>[4]</sup> Our patient is in the third decade of life, which is in agreement with what has been reported in the literature.<sup>[4]</sup>

A patient's aesthetics is usually compromised due to facial disfigurement. The swelling may also interfere with speech and swallowing and may cause respiratory compromise if the swelling displaces the tongue upward and backward. Our patient cited aesthetic compromise and inability to eat as her chief complaint, as her facial appearance had been severely compromised due to the resultant facial swelling.

Radiographically, myxofibroma presents in several patterns such as unilocular, pericoronal, radiolucent–radiopaque, and more frequently as multilocular radiolucency with well-corticated or diffuse borders.<sup>[10–13]</sup> The size of the lesion on the radiograph depends largely on the age of the lesion. It could be extended to involve the half of the maxilla with involvement of the maxillary tuberosity and the floor of the orbit or the mandible with the ramus and condyle involved.<sup>[14,15]</sup> It occasionally presents with unusual cortical reactions described as radiopaque lines with vertical orientation to the mandibular cortex from the periosteum into the adjacent soft tissue. This gives a resemblance of a sun-burst appearance.<sup>[16]</sup> It could also present as a destructive lesion exhibiting a peripheral sunray appearance. This cortical reaction on the radiograph could be responsible for the occasional misinterpretation of the tumor as a malignant lesion. The radiological features of myxofibroma make it difficult to differentiate it from other odontogenic tumors. In the past, plain radiograph was the sole image requested to investigate odontogenic fibromyxoma. The two-dimensional views of the plain radiographs made it difficult

**Table 1: Review of clinicopathologic variant of myxoma clinicodemographic data**

Article	Age/ gender	Number of cases	Location/duration	Symptoms	Size	Tissue involvement	Diagnosis dilemma
Index case	22/female	1	Maxillar/six months	Swelling/pain/ bleeding/pale/ asthenic	15 cm×13 cm×7 cm	Bone	Yes (odontogenic fibroma)
Okada <i>et al.</i> , 1997 <sup>[23]</sup>	52/male	1	Maxillary/six months	Swelling/no bleeding/pale/ alcoholism	3 cm×2 cm×1 cm	Soft tissue	Yes (epulis)
Mehrotra and kamboj 2008 <sup>[24]</sup>	12/male	1	Mandibular/48 months	Swelling/pain/ paresthesia	14 cm×8 cm×5 cm	Bone	No
Shahoon <i>et al.</i> , 2009 <sup>[11]</sup>	8/male	1	Mandibular/six months	Swelling	3.5 cm×2 cm	Bone	No
Hadidy <i>et al.</i> , 2010 <sup>[25]</sup>	15/male	1	Mandibular/NS	Swelling/ pain splenic angiosarcoma	NS	Bone	Yes (osteomyelitis)
Gupta <i>et al.</i> , 2010 <sup>[26]</sup>	30/female	1	Maxillary/four months	Swelling/pain	2 cm×2 cm	Bone	Radicular cyst
Infant cossio <i>et al.</i> , 2011 <sup>[5]</sup>	32/female	1	Anterior maxillary/ three months	Swelling	2 cm×1 cm	Bone	No
Dietrich <i>et al.</i> , 2011 <sup>[27]</sup>	46/male	1	Post maxillary/eight months	Swelling	Not available	Bone	No
Rokos <i>et al.</i> , 2011 <sup>[28]</sup>	5/female	1	Mandibular/one month	Swelling pain	4 cm×3 cm	Bone	Benign spindle cell lesion
Naresh <i>et al.</i> , 2015 <sup>[29]</sup>	63/female	1	Mandibular/12 months	Swelling	2 cm×2 cm	Soft tissue	No
Chauhan and Guruprasad 2012 <sup>[30]</sup>	32/female	1	Maxillary/six months	Swelling	-	Bone	No
Cankaya <i>et al.</i> , 2017 <sup>[2]</sup>	39/male	1	Post maxillary/NS	Swelling	2 cm×2 cm	Bone	No
Reddy <i>et al.</i> , 2013 <sup>[7]</sup>	12/male	1	Maxillary/six months	Swelling	Not available	Bone	No
Mounesh Kumar <i>et al.</i> , 2012 <sup>[31]</sup>	27/female	1	Maxillary/12 months	Swelling	5 cm×3 cm	Bone	No
Khan <i>et al.</i> , 2015 <sup>[32]</sup>	52/female	1	Maxillary/36 months	Swelling	5 cm×3 cm	Bone	Ossifying fibroma
Zayet and Eiid 2014 <sup>[33]</sup>	13/female	1	Mandibular/maxillary/ NS	Swelling	NS	Bone	No
Deliverska <i>et al.</i> , 2014 <sup>[34]</sup>	60/male	1	Mandibular/20 years with rapid Increase last two years	Swelling	-	Bone	No
Omeje <i>et al.</i> , 2015 <sup>[15]</sup>	8/male	8	Maxillary/24 months	Swelling/pain/ bleeding	12 cm	Bone	NS
	2/female		Mandibular/12 months	Swelling/pale	7 cm	Bone	NS
	7/male		Mandibular/24 months	Swelling/pain	12 cm	Bone	NS
	9/male		Maxillary/15 months	Swelling/pain/ ulceration	9 cm	Bone	NS
	11/female		Mandibular/36 months	Swelling/pale	10 cm	Bone	NS
	13/female		Maxillary/24 months	Swelling	8 cm	Bone	NS
	8/male		Mandibular/36 months	Swelling/pale	15 cm	Bone	NS
	10/female		Mandibular/12 months	Swelling	6 cm	Bone	NS
Verma <i>et al.</i> , 2015 <sup>[35]</sup>	21/male	1	Maxillary/eight months	Swelling	5 cm×4 cm	Bone	Yes? fibrous epulis
Singh <i>et al.</i> , 2016 <sup>[12]</sup>	21/male	1	Mandibular/NS	Swelling pain	5 cm×4 cm	Bone	Yes (epulis/ AM/CGCG/ myxoma)
Bahl <i>et al.</i> , 2016 <sup>[36]</sup>	15/male	1	Mandibular	Swelling pain	6 cm×5 cm	Bone	Unicystic ameloblastoma
Alhousami <i>et al.</i> , 2018 <sup>[6]</sup>	22/female	1	Mandibular/three years	Swelling	4 cm×2.5 cm	Bone	No

Contd...

**Table 1: Contd...**

Article	Age/ gender	Number of cases	Location/duration	Symptoms	Size	Tissue involvement	Diagnosis dilemma
Sato <i>et al.</i> , 2018 <sup>[37]</sup>	22/male	1	Mandibular/NS	Swelling	NS	Bone	No
Trehan <i>et al.</i> , 2020 <sup>[38]</sup>	30/female	1	Maxillary	Swelling 1 episode of bleeding (rapid change)	5 cm×5 cm	Soft tissue	Yes (low-grade spindle cell tumor)

NS: Not specified, AM: Ameloblastoma, CGCG: Central giant cell granuloma

to delineate the extent of the lesion, especially the maxillary lesion, hence the need for a CT scan in investigating this lesion. Gupta *et al.*<sup>[17]</sup> utilized CT scan and orthopantomograph in investigating their patient with right maxillary swelling. This is in tandem with Sharma *et al.*<sup>[18]</sup> that utilized the same imaging technique in addition to Waters' view of the skull and three-dimensional reconstruction of the CT scan in their case. Singh *et al.*<sup>[12]</sup> utilized orthopantomography only in investigating their patient who presented with mandibular lesion. Additional investigative tools that have been found useful in the management of patients with odontogenic fibromyxoma are cone-beam CT, magnetic resonance imaging, and stereolithographic models.<sup>[14,19]</sup>

MF is generally the same as other odontogenic tumors. Descriptive terminologies such as “soap bubbles,” “ground glass,” and “tennis racquet threads” have been used.<sup>[7]</sup> This great variability and the lack of specificity of radiological signs make histopathological examination mandatory. Possible differential diagnosis includes desmoplastic fibroma, primordial odontogenic tumor, and chondromyxoid fibroma.

The histology of MF shows a predominantly myxoid stroma interspersed with collagen fibers seen with the presence of spindle-to-stellate-shaped cells. Seen in areas are foci of calcific materials resembling cementum as shown in [Figures 9 and 10]. Also noted at the periphery of the lesion are much more fibrous stroma with vascular channels. Due to the histologic presentation, a diagnosis of MF was made. The provisional histopathologic diagnosis made prior to surgical resection was desmoplastic fibroma based on the stromal desmoplasia encountered in the lesion. It is interesting to note that because the mass was huge, the lesion has matured over time from being myxoid to becoming fibrotic which manifested massively at the periphery. It was this fibrotic area that was accessible when biopsy was done, creating this confusion. This underscores the importance of core biopsy or fine-needle aspiration cytology when a large mass is needed to be biopsied.

Primordial odontogenic tumor was also considered as a differential due to the presence of stellate-to-spindle-shaped cells, making it look like dental papillae. In our case, though there were stellate cells with myxoid stroma, there was no overlying epithelial component which is seen in primordial odontogenic tumor.

Chondromyxoid fibroma is rare in the oral cavity and typically presents with myxoid stroma in lobules with areas

of calcification resembling bone. This lobular presentation was not present in our case, and the stroma was devoid of chondromyxomatous appearance.

Currently, there is no consensus on the appropriate treatment for myxofibroma because there are varied methods of treatment reported in the literature, which include enucleation alone, enucleation with curettage followed by peripheral ostectomy, surgical excision of the mass, and surgical resection.<sup>[14,15]</sup> Singh *et al.*<sup>[12]</sup> performed enucleation only for their case, this is contrary to Reddy *et al.*<sup>[7]</sup> that added curettage to the enucleation in their case. Sharma *et al.*<sup>[18]</sup> surgically managed their patient by enucleation and curettage followed by peripheral ostectomy. The decision on the choice of treatment depends on, size of lesion at presentation, knowledge on the biological behavior of the lesion, and age of the patients at presentation. However, in our case, the lesion was found to be anatomically distinct from the surrounding normal bone and was surrounded by a thin envelope of slimy, mucoid substance with a cleavage which necessitated a conservative approach of surgical excision with peripheral ostectomy in areas where the remaining bone stump appeared rough. Of particular note in the management of the present case was the accidental finding of thin-walled cavitory lesions with characteristic air-crescent signs which was suggestive of left-sided pulmonary mycetoma. Pulmonary mycetoma, also known as pulmonary aspergilloma, is a saprophytic form of aspergillosis which results from growth of aspergillus in damaged bronchopulmonary tissues.<sup>[20,21]</sup> Various diseases that cause pulmonary scarring or cavities, such as lung cancer, cystic fibrosis, bullous emphysema, tuberculosis, and pulmonary abscesses predispose individuals to pulmonary aspergilloma. There was concern as to whether the patient can undergo surgery with the lung findings, which necessitated review by the pulmonologist and cardiothoracic surgical teams. Upon the review, the teams advised that the surgery be carried out as the patient was asymptomatic but recommended that the patient should be placed on antifungal drug (itraconazole 200 mg 1 2 hourly) which the patient commenced three days preoperatively and continued postoperatively. It has been reported that systemic azoles are effective in the treatment of mycetoma in approximately 50%–80% of patients.<sup>[22]</sup>

The literature review was done using search engine PubMed, Google Scholar, and Scopus with the following keywords: “Odontogenic myxofibroma,” “odontogenic fibromyxoma,” “odontogenic myxoma” “myxofibroma of the maxilla,”



**Table 2: Review of histologic variant of myxoma radiographic, treatment, recurrence and histology**

Article	Radiography	Histopath finding	Treatment	Recurrence	Reconstruction	Diagnosis
Index case	Multilocular radiolucency	↑Myxoid↓Fibrous Strands of odontogenic epithelium	Excision with peripheral ostectomy	Nil/six months	Obturator	Myxofibroma
Okada <i>et al.</i> , 1997 <sup>[23]</sup>	Unilocular radiolucency	↑Myxoid↓Fibrous Strands of odontogenic epithelium	Extirpation/ extraction	Nil/24 months	NS	Myxofibroma
Mehrotra and Kamboj, 2008 <sup>[24]</sup>	Multilocular radiolucency	↑Fibrous↓Myxoid	Mandibulectomy	Nil/36 months	Ilaic crest	Myxofibroma
Shahoon <i>et al.</i> , 2009 <sup>[11]</sup>	Multi/unilocular-radiolucency	Nil	Enuacleation	Nil/36 months	NS	Fibromyxoma
Hadidy <i>et al.</i> , 2010 <sup>[25]</sup>	Abnx bone marrow signal	Not stated	Nil	Death from ass CA	NS	Myxofibroma
Gupta <i>et al.</i> , 2010 <sup>[26]</sup>	Mixed radiolucent-radioopaque	↑Fibrous↓Myxoid	Maxillectomy	NS	NS	Fibromyxoma
Infant Cossio <i>et al.</i> , 2011 <sup>[5]</sup>	Multilocular radiolucency	↑Fibrous↓Myxoid Strands of odontogenic epithelium	Maxillectomy	Nil	Anterior iliac crest graft	Fibromyxoma
Dietrich <i>et al.</i> , 2011 <sup>[27]</sup>	Multilocular radiolucency	↑Myxoid↓Fibrous Strands of odontogenic epithelium	Enucleation + curettage	Nil/24 months	Pedicle buccal fat pad	Fibromyxoma
Rokos <i>et al.</i> , 2011 <sup>[28]</sup>	Multilocular radiolucency	↑Fibrous↓Myxoid	Enucleation	Nil/six months	NS	Myxofibroma
Naresh <i>et al.</i> , 2015 <sup>[29]</sup>	No bony pathology	↑Myxoid↓Fibrous No epithelium rest	Enucleation	Nil	NS	Myxofibroma
Cankaya <i>et al.</i> , 2017 <sup>[2]</sup>	Unilocular-radiolucency	↑Myxoid↓Fibrous Strands of odontogenic epithelium	Enucleation + curretage	Nil/12 months	NS	Myxofibroma
Chauhan and Guruprasad 2012 <sup>[30]</sup>	Unilocular-radiolucency	NS	Enucleation + currettage	Nil/12	NS	Fibromyxoma
Reddy <i>et al.</i> , 2013 <sup>[7]</sup>	Multilocular radiolucency	↑Fibrous↓Myxoid	Enucleation + curretage	Nil/not stated	NS	Fibromyxoma
Mounesh Kumar <i>et al.</i> , 2012 <sup>[31]</sup>	Radioapacity	↑Fibrous↓Myxoid	Maxillectomy	Nil/six months	Obturator	Fibromyxoma
Deliverska <i>et al.</i> , 2014 <sup>[34]</sup>	Multilocular radiolucency	NS	Excision, osteotomy	-	Vestibular flap	Fibromyxoma
Khan <i>et al.</i> , 2015 <sup>[32]</sup>	Multilocular radiolucency	↑Fibrous↓Myxoid	Excision with curretage	Nil/four months	NS	Myxofibroma
Zayet and Eiid 2014 <sup>[33]</sup>	Unilocular radiolucency	↑Fibrous↓Myxoid	Enucleation	NS	NS	Fibromyxoma
Omeje <i>et al.</i> , 2015 <sup>[15]</sup>	Multilocular radiolucency	↑Myxoid↓Fibrous	Excision	Nil/two years	NS	Fibromyxoma
	Multilocular radiolucency	↑Myxoid↓Fibrous	Excision	Nil/two years	NS	Fibromyxoma
	Multilocular radiolucency	↑Myxoid↓Fibrous	Resection	Nil/two years	NS	Fibromyxoma
	Multilocular radiolucency	↑Myxoid↓Fibrous	Excision	Nil/two years	NS	Fibromyxoma
	Multilocular radiolucency	↑Myxoid↓Fibrous	Excision	Nil/two years	NS	Fibromyxoma
	Multilocular radiolucency	↑Myxoid↓Fibrous	Excision	Nil/two years	NS	Fibromyxoma
	Multilocular radiolucency	↑Myxoid↓Fibrous	Excision	Nil/two years	NS	Fibromyxoma
	Multilocular radiolucency	↑Myxoid↓Fibrous	Excision	Nil/two years	NS	Fibromyxoma
	Multilocular radiolucency	↑Myxoid↓Fibrous	Excision	Nil/two years	NS	Fibromyxoma
Verma <i>et al.</i> , 2015 <sup>[35]</sup>	Unilocular radiolucency	↑Fibrous↓Myxoid	Excision	Nil/nine months	NS	Fibromyxoma

*Contd...*

**Table 2: Contd...**

Article	Radiography	Histopath finding	Treatment	Recurrence	Reconstruction	Diagnosis
Singh <i>et al.</i> , 2016 <sup>[12]</sup>	Multilocular radiolucency	↑Fibrous↓Myxoid	Enucleation	Not follow	NS	Fibromyxoma
Bahl <i>et al.</i> , 2016 <sup>[36]</sup>	Unilocular radiolucency	↑Myxoid↓Fibrous	Segmental resection	Nil/12 months	Free fibular flap	Fibromyxoma
Alhousami <i>et al.</i> , 2018 <sup>[6]</sup>	Multilocular radiolucency	↑Fibrous↓Myxoid	Segmental resection	Nil/six months	Reconstruction plate	Fibromyxoma
Sato <i>et al.</i> , 2018 <sup>[37]</sup>	Multilocular radiolucency	NS	Mandibulectomy	Nil/84 months	TMJ prostheses	Myxofibroma
Trehan <i>et al.</i> , 2020 <sup>[38]</sup>	Multilocular radiolucency	↑Fibrous↓Myxoid	Excision/peripheral ostectomy	Followed/not stated	NS	Fibromyxoma

NS: Not specified, TMJ: Temporomandibular joint, CA: Carcinomas

“myxofibroma of the mandible,” “myxofibroma of the jaw,” “fibromyxoma of the jaw” “case report on myxofabroma,” and “case series on myxofibroma.” Articles where amount of fibrous and myxoid tissue were not stated were excluded from the study. Findings from this review are concisely summarized in Tables 1 and 2 with the inclusion of the present case.

In conclusion, MF of the jaws is uncommon. Surgery is the only choice of treatment as MF is not radiosensitive. Consideration for the type of surgery may include the age of the patient, extent of the tumor, and recurrence of the lesion. A surgical excision with peripheral ostectomy in areas where the remaining bone stump appeared rough was our treatment of choice in this patient. The patient has been followed up for a period of six months without any clinical or radiographic evidence of recurrence, this is in agreement with Gupta *et al.*<sup>[17]</sup> followed their patient up for six months with no evidence of recurrence.

### Declaration of patient consent

The authors certify that they have obtained all appropriate patient consent forms. In the form, the patient has given her consent for her images and other clinical information to be reported in the journal. The patient understand that name and initials will not be published and due efforts will be made to conceal identity, but anonymity cannot be guaranteed.

### Financial support and sponsorship

Nil.

### Conflicts of interest

There are no conflicts of interest.

## REFERENCES

- Poudel P, Bajracharya B, Bhattacharya S, Bajracharya D, Singh S, Pokhrel P, *et al.* Odontogenic myxofibroma-Report of a rare entity. *J Pathol Nepal* 2016;6:1043-45.
- Cankaya AB, Erdem MA, Bilgic B, Firat D. Myxofibroma of the maxilla, current concepts, and differential diagnosis. *J Dent Sci* 2017;12:417-20.
- Santarelli A, Mascitti M, Capocasale G, Troiano G, Favia GF, Malorano E, *et al.* Odontogenic myxofibroma in a paediatric patient: Case report and review of the literature. *Glob J Oral Sci* 2015;1:23-8.
- Sweeney J, Laverick S. Odontogenic myxofibroma-A rare case report. *Arc Journal of Dental Sciences* 2020;5:1-3.
- Infante Cossío P, Martínez de Fuentes R, García-Perla García A, Jiménez-Castellanos Ballesteros E, Gómez Izquierdo L. Myxofibroma

of the maxilla. Reconstruction with iliac crest graft and dental implants after tumor resection. *Med Oral Patol Oral Cir Bucal* 2011;16:e532-6.

- Alhousami T, Sabharwal A, Gupta S, Aguirre A, Park E, Kramer JM. Fibromyxoma of the jaw: Case report and review of the literature. *Head Neck Pathol* 2018;12:44-51.
- Reddy GS, Kumar BS, Muppa R, Regonda SK, Tvs HK. Odontogenic fibromyxoma of maxilla: A rare case report. *Case Rep Dent* 2013;2013:345479.
- Brannon RB. Central odontogenic fibroma, myxoma (odontogenic myxoma, fibromyxoma), and central odontogenic granular cell tumor. *Oral Maxillofac Surg Clin North Am* 2004;16:359-74.
- Westwood RM, Alexander RW, Bennett DE. Giant odontogenic myxofibroma. Report of a case with histochemical and ultrastructural studies and a review of the literature. *Oral Surg Oral Med Oral Pathol* 1974;37:83-92.
- Meleti M, Giovannacci I, Corradi D, Manfredi M, Merigo E, Bonanini M, *et al.* Odontogenic myxofibroma: A concise review of the literature with emphasis on the surgical approach. *Med Oral Patol Oral Cir Bucal* 2015;20:e1-6.
- Shahoon H, Esmaeili M, Nikhalat M, Farokhi E. Odontogenic fibromyxoma and odontogenic cyst in an eight year old boy: Three-year follow-up. *J Dent Res Dent Clin Dent Prospects* 2009;3:103-5.
- Singh S, Singh S, Sachdeva A, Gupta K. Odontogenic fibromyxoma: A diagnostic dilemma. *Int J of Oral Health and Med Res* 2016;3:111-5.
- Lawal AO, Adisa AO, Olusanya AA. Odontogenic tumours: A review of 266 cases. *J Clin Exp Dent* 2013;5:e13-7.
- Sato H, Asoda S, Muraoka W, Yoshikawa M, Yasui T, Horie N. Large odontogenic mixofibroma of the mandible excised without visible scar: A case report. *Journal of Oral and Maxillofacial Surgery, Medicine and Pathology* 2018;30:272-7.
- Omeje KU, Amole IO, Osunde OD, Efunkoya AA. Management of odontogenic fibromyxoma in pediatric Nigerian patients: A review of 8 cases. *Ann Med Health Sci Res* 2015;5:461-5.
- White JA, Ramer N, Wentland TR, Cohen M. The rare radiographic sunburst appearance of odontogenic myxomas: A case report and review of the literature. *Head Neck Pathol* 2020;14:1105-10.
- Gupta I, Keluskar V, Shetti AJ. Odontogenic fibromyxoma of left maxilla-A case report. *Journal of International of Oral Health* 2010;2:79-85.
- Sharma R, Esht V, Nagrath S, Thapar DJ. Odontogenic fibromyxoma of maxilla: A rare lesion. *Int J Dent Med Res* 2014;1:42.
- Alansari R, Gohel A, Kashtwari D, Ajos R. Odontogenic fibromyxoma: Case report and a review of the literature. *Oral Med Oral Pathol Radiol* 2021;132:e123-24.
- Singhal S. Pulmonary mycetoma. *Lung India* 2012;29:81-2.
- Lee SH, Lee BJ, Jung DY, Kim JH, Sohn DS, Shin JW, *et al.* Clinical manifestations and treatment outcomes of pulmonary aspergilloma. *Korean J Intern Med* 2004;19:38-42.
- Lang M, Lang AL, Chauhan N, Gill A. Non-surgical treatment options for pulmonary aspergilloma. *Respir Med* 2020;164:105903.
- Okada H, Izumi R, Kaneda T, Yamamoto H. Odontogenic myxofibroma arising from the periodontal ligament in the maxillary molar region.



- J Periodontol 1997;68:479-84.
24. Mehrotra D, Kamboj M. Recurrent odontogenic myxofibroma of the mandible in a 12 year old: An illustrative case report. *J Clin Pediatr Dent* 2008;32:309-12.
  25. Hadidy A, Alsharif A, Sheikh-Ali R, Abukhalaf M, Awidi A, Abukaraki A, *et al.* Odontogenic myxofibroma synchronous with primary angiosarcoma of the spleen. *Br J Radiol* 2010;83:e10-3.
  26. Gupta I, Keluskar V, Shetti A. Odontogenic fibromyxoma of left maxilla-A case report. *J Int Oral Health* 2010;2:79-85.
  27. Dietrich EM, Papaemmanouil S, Koloutsos G, Antoniadis H, Antoniadis K. Odontogenic fibromyxoma of the maxilla: A case report and review of the literature. *Case Rep Med* 2011;2011:238712.
  28. Rokos J, Carlos R, Romañach MJ. Clinical pathologic conference case 6: Infantile myofibroma. *Head Neck Pathol* 2011;5:292-5.
  29. Naresh N, Srinivas V, Malik A, Sahoo NK, Dutta V. Myxofibroma of the soft tissue of face. *Med J Armed Forces India* 2015;71:S282-4.
  30. Chauhan DS, Guruprasad Y. Odontogenic fibromyxoma of the maxilla. *SRM J Res Dent Sci* 2012;3:212.
  31. Mounesh Kumar C, Suresh K, Pramod R, Rajendra Baad AS, Raghavendra M. An unusual case of odontogenic fibromyxoma of anterior maxilla. *Pathology* 2012;3:60-3.
  32. Khan SF, Agrawal P, Sur J. A rare case report of myxoid fibroma of maxilla. *Quant Imaging Med Surg* 2015;5:778-82.
  33. Zayet MK, Eiid SB. Multiple fibromyxomas of the jaws: A case report. *Imaging Sci Dent* 2014;44:237-41.
  34. Deliverska E, Krasteva A, Stefanov L, Michaylova H, Bobeva A. Unsuspected odontogenic fibromyxoma the mandible – A clinical case. *Med Inform* 2014;1:45-51.
  35. Verma P, Surya V, Kadam SG, Umarji H. Radiographic presentation of fibromyxoma: An uncommon entity. *IJSS* 2015;2:13.
  36. Bahl S, Raju GS, Shah G, Chandarana P. Central odontogenic fibromyxoma of mandible: An aggressive odontogenic pathology. *BMJ Case Rep* 2016;2016:bcr2016217303.
  37. Sato H, Asoda S, Muraoka W, Yoshikawa M, Yasui T, Horien N. Large odontogenic mixofibroma of the mandible excised without visible scar: A case report. *J Oral Maxillofac Surg Med Pathol* 2018;30:272-7.
  38. Trehan S, Jaitly S, Lade H, Ponnusamy S, Khandelwal K. Odontogenic fibromyxoma of maxilla: A rare case with intriguing pathology. *Indian J Otolaryngol Head Neck Surg* 2020;1-5. <http://doi/10.1007/s12070-020-02187-z>.