

Crystalline Maculopathy: A Report of Two Patients in Ibadan, Southwestern Nigeria

T. S. Oluleye¹, Y. O. Babalola¹, O. I. Majekodunmi¹, M. A. Ijaduola¹, Olabimpe Ruth Abiola¹

¹Department of Ophthalmology, University College Hospital, Ibadan, Oyo State, Nigeria

Abstract

We present two patients with crystalline maculopathy seen at the Eye Clinic of the University College Hospital, Ibadan, Nigeria. Both patients had diabetes, with the first patient having systemic hypertension controlled on medications. There was no history of kola nut ingestion in the two patients. Medical examination by the internist revealed no other systemic disease. The central vision was good in both patients. Optical coherence tomography localized the crystals to the inner retina, and there was no associated macular edema. Some pathogenetic mechanisms are proffered based on available literature.

Keywords: Crystalline retinopathy, diabetes, maculopathy, West Africa

INTRODUCTION

Crystalline maculopathy has been reported in Nigerians of Igbo tribe living abroad. This was postulated to be due to the kola nuts consumed by this set of Nigerians.^[1] Other reports also found retina crystals in other Nigerian tribes living abroad.^[2] However, there was no available report to the best of the authors' knowledge on the subject in Nigerians living in Nigeria.

Funduscopy in patients with crystalline maculopathy often revealed iridescent spots on the macula with little or no visual affectation. Differentials of crystals on the macula or retina include tamoxifen therapy, Bietti's crystalline retinopathy, canthaxanthine ingestion, exposure to sunlight, and intravenous drug abusers. Other systemic diseases implicated include sickle cell disease, oxalosis, and Sjögren syndrome. Previous reports have been made on retina crystals occurring in hyperornithinemia, cystinosis, and macular hole.^[3,4]

amlodipine). She had no history of kola nut consumption and no history of other systemic disease. Ocular examination showed visual acuity of 6/9 and 6/12 in the right and left eye with a best correction of 6/6 in each eye. Anterior segments were quiet, with cortical lens opacities. Applanation tonometry showed intraocular pressures of 18 mmHg in each eye.

Fundus biomicroscopy with the slit lamp and a +78D lens revealed pink discs with cup-disc ratios of 0.3 in both eyes. Few cotton wool spots were noted on the retina and iridescent spots in both fovea (which were refractile crystals on magnification). Optical coherence tomography (OCT) scan showed no macular edema. The hyperreflective crystals were noted on the fovea depression in inner retina, especially on black and white imaging mode [Figure 1a-c].

Case 2

The second patient, an 82-year-old Nigerian female of Yoruba tribe who has lived in Ibadan, Southwestern Nigeria since birth.

CASE REPORTS

Case 1

A 71-year-old female of Yoruba origin residing in Western Nigeria presented to the eye clinic for routine eye examination. She is a known diabetic and hypertensive being optimally controlled with medications (glibenclamide, metformin, and

Address for correspondence: Dr. O. I. Majekodunmi,
Department of Ophthalmology, University College Hospital, Ibadan,
Oyo State, Nigeria.
E-mail: wolemajek@gmail.com

This is an open access journal, and articles are distributed under the terms of the Creative Commons Attribution-NonCommercial-ShareAlike 4.0 License, which allows others to remix, tweak, and build upon the work non-commercially, as long as appropriate credit is given and the new creations are licensed under the identical terms.

For reprints contact: WKHLRPMedknow_reprints@wolterskluwer.com

How to cite this article: Oluleye TS, Babalola YO, Majekodunmi OI, Ijaduola MA, Abiola OR. Crystalline maculopathy: A report of two patients in Ibadan, Southwestern Nigeria. *Niger J Med* 2021;30:112-5.

Submitted: 19-Nov-2020

Revised: 05-Dec-2020

Accepted: 25-Dec-2020

Published: 15-Feb-2021

Access this article online

Quick Response Code:



Website:
www.njmonline.org

DOI:
10.4103/NJM.NJM_200_20

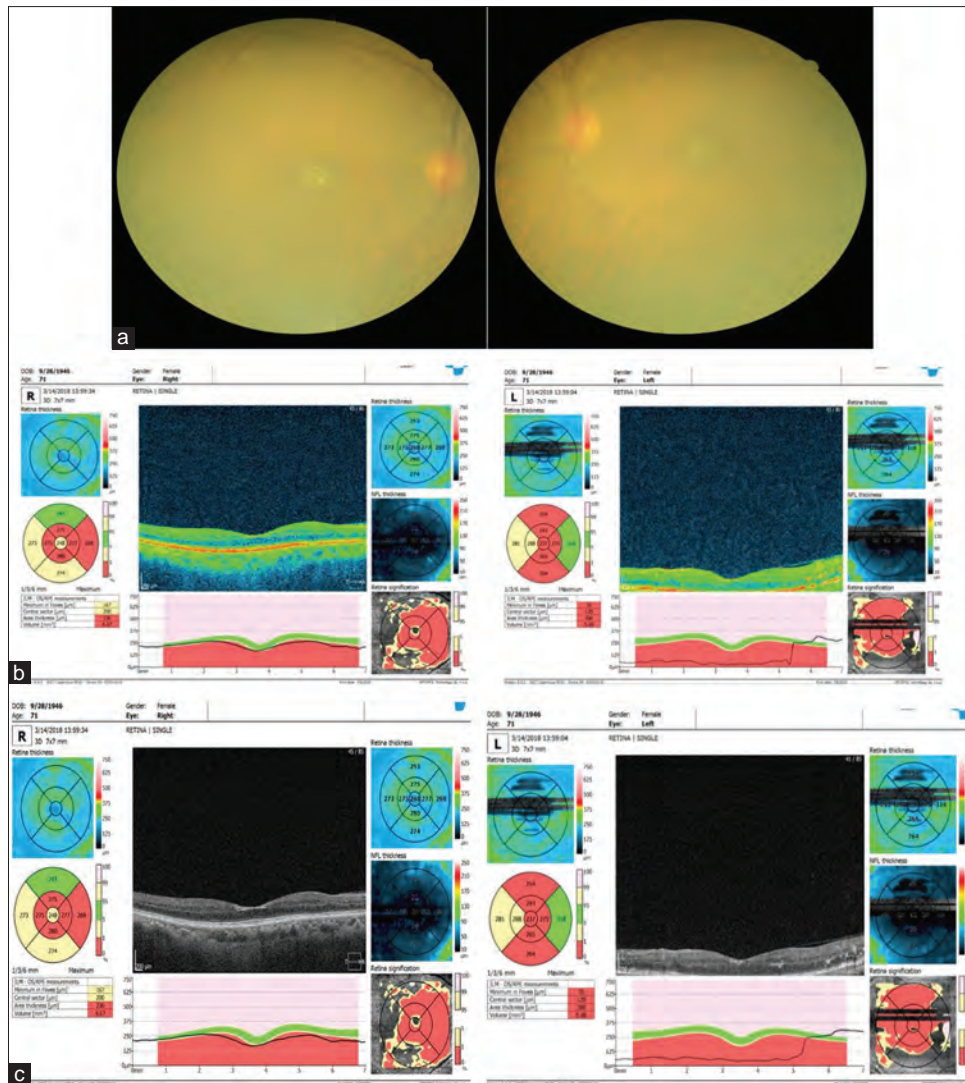


Figure 1: (a) Fundus photo with iridescent crystals on both foveae. (b) Optical coherence tomography scan showing refractile bodies in inner retina at the fovea depression, no macular edema. (c) Black/white mode of optical coherence tomography showing crystals at the fovea depression

She had no history of kola nut ingestion. She is a diabetic of 6-year duration controlled on medication (glibenclamide and metformin). She had no other systemic diseases. She presented for routine retinal examination. Ocular examination showed visual acuity of 6/9 in each eye with quiet anterior segments.

Fundus biomicroscopy with the slit lamp and a +78D lens showed clear media, pink discs, normal retinal vessels, and few hard exudates temporal to the macula. Iridescent refractile crystals were seen on both maculae with no macular edema. A diagnosis of nonproliferative diabetic retinopathy with crystalline maculopathy was made. OCT scan showed right vitreomacular traction, but no edema was seen. Using the black/white mode enhanced the reflectivity of the crystals on the fovea depression [Figure 2a-c].

DISCUSSION

Crystalline maculopathy was reported in Nigerians and other West African patients in the United States and was termed West

African crystalline maculopathy. The Igbo tribe of Nigeria and the intake of kola nut were prominent in the reports.^[1] The two patients in our report belong to the Yoruba tribe of Western Nigeria. However, our patients had no history of kola nut ingestion. Other reports have reported the crystals in the Yoruba and the Benin tribes of Nigeria living abroad.^[2]

Systemic diseases such as chronic renal failure, hyperornithemia, oxalosis, and Sjögren syndrome are associated with crystals on the retina. Drugs such as tamoxifen, tanning agents, and intravenous talc are associated with retina crystals.^[3,4] Chronic retinal detachment and macular hole have also been implicated.^[5] Our patients had no other systemic diseases apart from diabetes and hypertension. Hypertension and diabetes mellitus were well controlled in our patients. They were on oral hypoglycemic drugs only, except the first patient who is also on antihypertensive. The intern did not find any other systemic diseases.

Visual acuity was normal in both patients in support of a previous report.^[6] Dilated funduscopy showed mild retinopathy

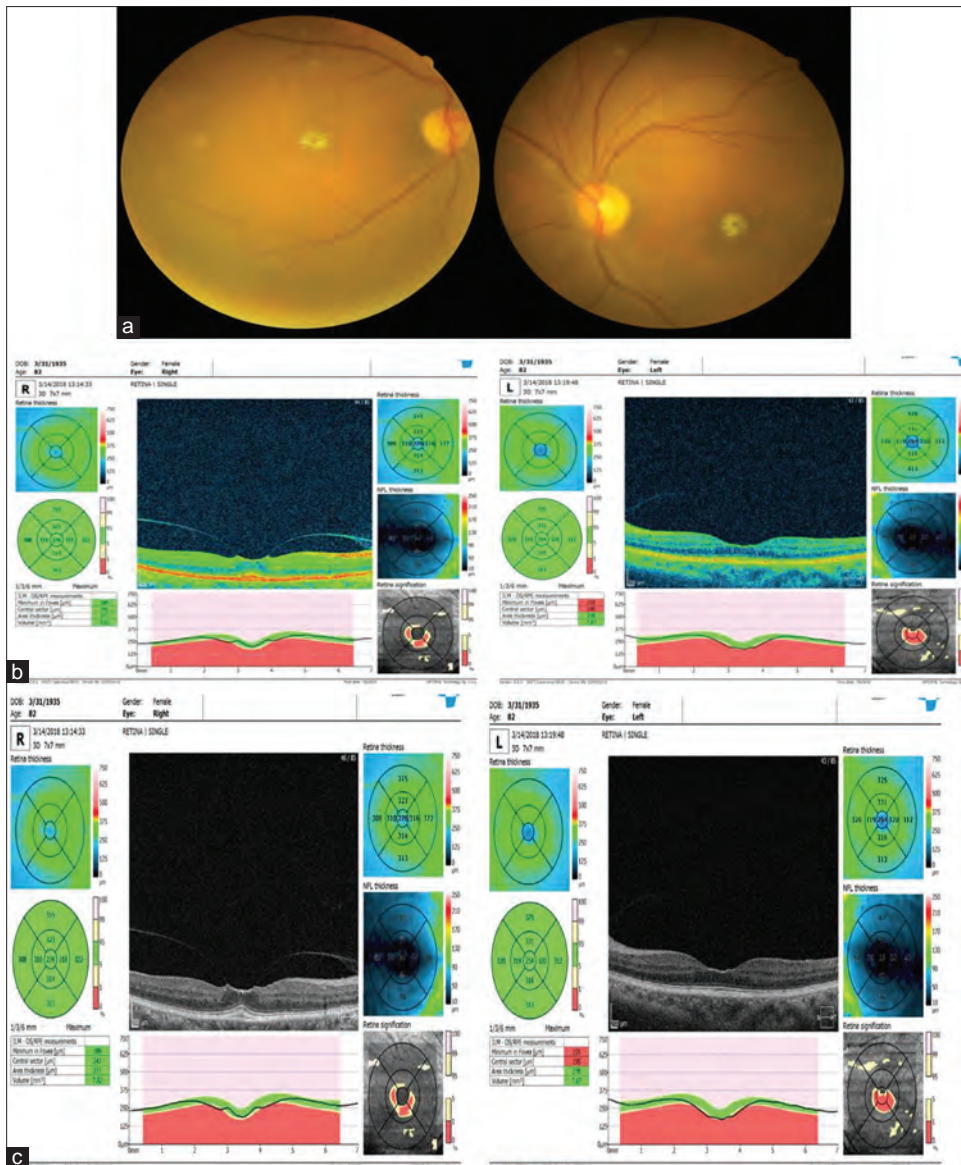


Figure 2: (a) Fundus photos of patient 2 with iridescent crystals on the macula with few hard exudates temporal to the macula. (b) Optical coherence tomography of patient 2 with no macular edema, right vitreomacular traction with refractile bodies in inner retina. (c) Black/white optical coherence tomography imaging mode showing hyperreflectivity of the crystals

with few hard exudates in the second patient. The first patient had no significant retinopathy. OCT showed no macula edema in both patients. Vitreomacular traction was noted in one eye of the second patient; however, no edema was found on OCT. In our patients, the crystals at the fovea were located in the inner retina similar to other reports with black/white imaging mode of the OCT showing enhancement of their reflectivity.^[2,7]

Previous workers attributed the crystals to vascular etiology from diabetes and retinal vascular disease, while some linked crystalline retinopathy to some form of diets in the populace.^[6,7] In western Nigeria, consumption of starchy or carbohydrate-rich foods are common. It may be difficult to narrow it down to a particular food. Postmortem examination of the crystals may give some clues as to their etiology. However,

the only similarities in both patients include tribe, presence of diabetes, and possible similarities in diet.

Differential diagnoses in our patients include; diabetic maculopathy where the crystals may be mistaken for hard exudates on cursory examination. However, magnified view will show refractive crystals and no edema. Visual acuity is usually normal. Other considerations include; cystoid macular edema from diabetes, old vascular occlusion, or inflammatory cystoid macula edema. The crystals look like microcysts, but magnified view will show refractile crystals, no macula edema, and good visual acuity.

Other differential diagnoses include; drug toxicity from anticancer medications such as tamoxifen. Crystals are

deposited in the retina and macula in a more extensive pattern. Our patients had no history of breast cancer or previous cancer therapy.

Crystals may also occur in the retina in Bietti's crystalline retinopathy, oxalosis, and canthaxanthine therapy. However, all these were absent in our patients.

In conclusion, crystalline maculopathy may be more common than reported. The etiology is still an enigma; however, diabetes is a common factor. Postmortem examination and analysis may reveal their true etiology.

Acknowledgment

The authors thank the patients for consenting to have their pictures taken for this manuscript.

Financial support and sponsorship

Nil.

Conflicts of interest

There are no conflicts of interest

REFERENCES

1. Sarraf D, Ceron O, Rasheed K, Drenser KA, Casey R. West African crystalline maculopathy. *Arch Ophthalmol* 2003;121:338-42.
2. Rajak SN, Mohamed MD, Pelosini L. Further insight into West African crystalline maculopathy. *Arch Ophthalmol* 2009;127:863-8.
3. Nadim F, Walid H, Adib J. The differential diagnosis of crystals in the retina. *Int Ophthalmol* 2001;24:113-21.
4. Bloomenstein MR, Pinkert RB. Canthaxanthine retinopathy. *J Am Optom Assoc* 1996;67:690-2.
5. Heatley CJ, Georgalas I, Sullivan P. Crystalline retinopathy associated with chronic macular hole; a report of two cases. *Eye (Lond)* 2007;21:1120-1.
6. Browning DJ. West African crystalline maculopathy. *Ophthalmology* 2004;111:921-5.
7. Kung JS, Leng T. West African crystalline maculopathy in sickle cell retinopathy. *Case Rep Ophthalmol Med* 2015;2015:910713.