

Gastric Duplication Cyst with Multiple Ectopic Pancreatic Tissues: A Case Report and Review of Literature

Victor Ifeanyichukwu Modekwe¹, Somto Celestine Ngonadi², Ezekiel Uchechukwu Nwankwo¹, Chukwuzitelu Oluwajoba Okafor Udah³, Charles Chidiebele Maduba⁴

¹Department of Surgery, Daystar Specialist Hospital Nkwelle-Ezunaka and Nnamdi Azikiwe University Awka, Anambra Nigeria, ²Department of Paediatrics, Nnamdi Azikiwe University Teaching Hospital Nnewi, Anambra Nigeria, ³Department of Surgery, Daystar Specialist Hospital, Nkwelle-Ezunaka, Anambra Nigeria. ⁴Department of Surgery, Alex Ekwueme Federal University Teaching Hospital Abakaliki, Ebonyi Nigeria

Abstract

A gastric duplication cyst (GDC) is a type of enteric duplication cyst. It can co-exist with an ectopic tissue. This was a female toddler with a GDC at the greater curvature. An abdominal ultrasound and a contrast-enhanced computed tomogram suggested the cyst. She had laparotomy, complete cyst and partial gastric excision with the removal of extragastric pancreatic tissue. The histology report came out as a cyst with associated intracystic and an extracystic pancreatic tissue. She made a clinical improvement. GDC can be associated with both intracystic and extracystic ectopic pancreatic tissues. This should be kept in mind when choosing the modality of treatment.

Keywords: Ectopic pancreas, gastric duplication cyst, intra-peritoneal cyst

INTRODUCTION

A gastric duplication cyst (GDC) is a rare type of gastrointestinal duplication cyst.^[1,2] It is an abnormal extra portion of the gastrointestinal tract that shares blood supply with the original tract, which can be asymptomatic or present with life-threatening complications. It accounts for 2%–9% of all gastrointestinal duplication cysts.^[2] It is a congenital anomaly and usually diagnosed at childhood, but can evade diagnosis till adulthood. A GDC has muscular and mucosal layers.^[1] It may or may not communicate with the gastric lumen.^[1] The cyst could be asymptomatic or symptomatic. Its symptoms, when present may include nausea, vomiting, rectal bleeding, abdominal pain, palpable mass, and features of gastric outlet obstruction.^[3–5] It has also mimicked other anomalies such as lymphangioma.^[6] GDC has been associated with ectopic tissues such as gastric, duodenal, and pancreatic tissues.^[1,5,7] An abdominal ultrasound will reveal a cyst in the vicinity of the stomach.^[6] A contrast-enhanced abdominal computed tomogram (CT) will show a cystic lesion attached to the stomach.^[5] Treatment is by open or laparoscopic resection, and a newer trend of endoscopic submucosal resection.^[6,8]

This is a rare case of symptomless extraluminal, noncommunicating, and incomplete GDC associated with double pancreatic ectopic tissues in a child.

CASE REPORT

A 19-month-old female with an incidental observation of a recurrent upper abdominal lump. There was no pain, vomiting, weight loss, hematemesis and hematochezia. An intraperitoneal mass was noted in the epigastric region, very mobile, and nontender. There was no ascites and the hernia orifices were intact. She had stable vital signs; with a weight of 10Kg.

An abdominopelvic ultrasound suggested a mesenteric cyst. A computed tomography abdominal scan with double contrast revealed an 8 cm × 7 cm hypodense cystic

Address for correspondence: Dr. Victor Ifeanyichukwu Modekwe, Daystar Specialist Hospital, Nkwelle-Ezunaka, Anambra State, Nigeria. E-mail: victormodekwe@yahoo.com

This is an open access journal, and articles are distributed under the terms of the Creative Commons Attribution-NonCommercial-ShareAlike 4.0 License, which allows others to remix, tweak, and build upon the work non-commercially, as long as appropriate credit is given and the new creations are licensed under the identical terms.

For reprints contact: WKHLRPMedknow_reprints@wolterskluwer.com

How to cite this article: Modekwe VI, Ngonadi SC, Nwankwo EU, Okafor Udah CO, Maduba CC. Gastric duplication cyst with multiple ectopic pancreatic tissues: A case report and review of literature. Niger J Med 2020;29:734-6.

Submitted: 27-Jun-2020 **Revised:** 30-Jul-2020

Accepted: 25-Aug-2020 **Published:** 24-Dec-2020

Access this article online

Quick Response Code:



Website:
www.njmonline.org

DOI:
10.4103/NJM.NJM_121_20

mass [Figures 1 and 2] arising from the greater curvature of the stomach [Figures 2 and 3]. There was a dilated stomach [Figures 2 and 3]. The hemoglobin was 10 g/dl. The serum electrolytes, blood urea, and creatinine were normal.

She was planned for and had an exploratory laparotomy where a cyst arising from the greater curvature of the stomach [Figure 4], sharing the same wall with the stomach, but no luminal communication was seen. The cyst was closer to the antral region than the fundal region. The cyst has a yellowish cord extending to the vicinity of the splenic hilum [Figure 5]. The pancreas, spleen, and intestines were normal. The stomach was dilated, but no evidence of gastric outlet obstruction from other causes. Cystectomy with partial gastrectomy was done. The yellowish cord was removed en-bloc with the cyst. The stomach was repaired in two layers with a size 2-0 polyglactin suture.

The specimen was sent for histology and came out as an ectopic pancreatic tissue on both the mucosa of the cyst and the adjoining cord. The child had an uneventful recovery. She has been followed up for 3 months.

DISCUSSION

GDC is a congenital anomaly and diagnosis tends to occur at the childhood stage.^[5] Asymptomatic types may be diagnosed later in adulthood, especially when present as a complication of rectal bleeding or peritonitis following rupture.^[1,6,7] The predilection of the cyst for the greater curvature makes it less likely to produce symptoms. The index case was an incidental finding of an upper abdominal mass that is intermittent and has no other symptoms. This will require observant parents or caregivers, who are knowledgeable to insist they saw a mass and to seek expert healthcare. The above may have accounted for this early presentation, as similar lesions usually present in adulthood.^[7] A late presentation usually comes as a complication, especially when an ectopic tissue is involved.^[7] It is impressive to note the early asymptomatic presentation, which is not the norm in the environment.^[8]

An abdominal ultrasonography (USS) may suggest a GDC. However other commoner differential diagnoses make ultrasound not very effective. USS, in this case, showed a

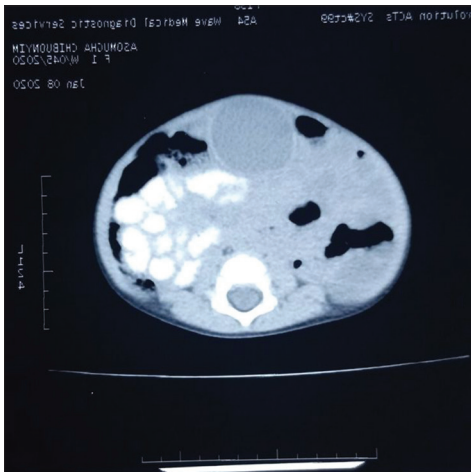


Figure 1: A contrast-enhanced computed tomogram scan showing a hypoechoic mass abutting the anterior abdominal wall

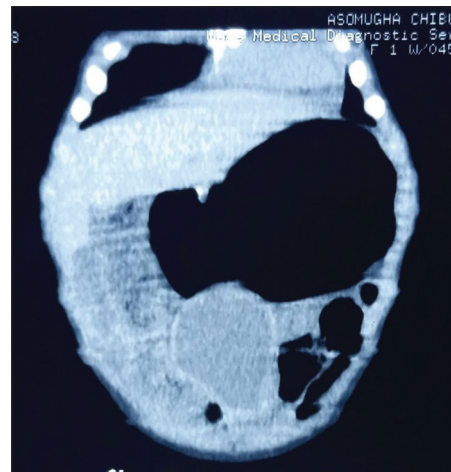


Figure 2: Coronal computed tomogram-scan section: Showing dilated stomach and cyst attached to the greater curvature of the stomach

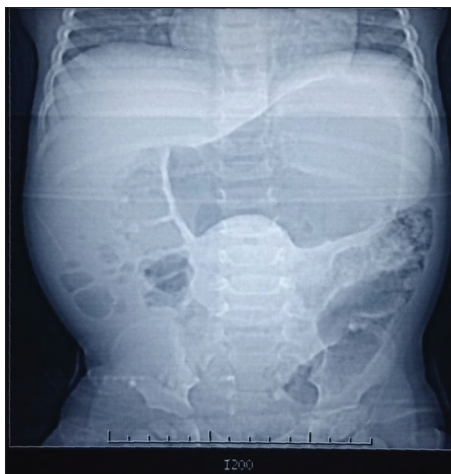


Figure 3: Computed tomogram-scan showing dilated stomach, and a mass indenting and hanging down the greater curvature

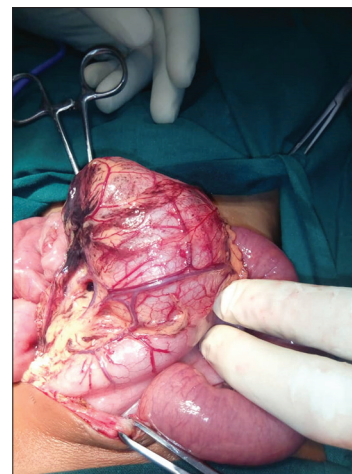


Figure 4: Laparotomy picture showing the gastric duplication cyst (thick arrow) attached to the greater curvature of the stomach (thin arrow)

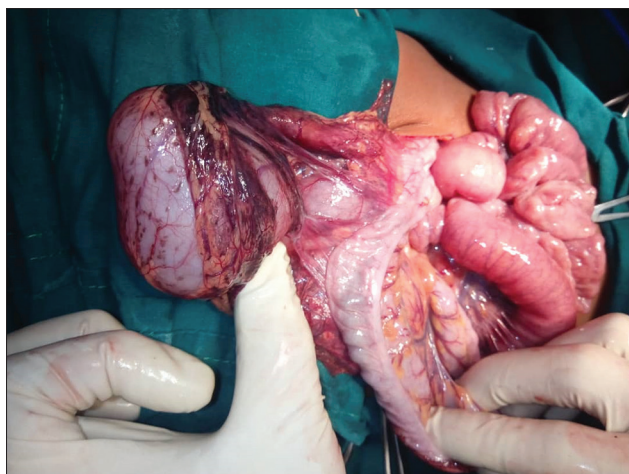


Figure 5: Laparotomy picture showing the cord-like ectopic pancreatic tissue (thick arrow) attached to the gastric duplication cyst (horizontal thin arrow) and extending toward the splenic hilum (vertical thin arrow)

hypoechoic mass below the stomach, suggesting an omental cyst. However, a contrast-enhanced CT will most likely suggest a GDC. It showed, in this case, a hypodense mass with minimal enhancement adherent to the stomach but not communicating with it. The reconstructions of CT scan images made the delineation clearer and more definitive. It was enough to intervene with these results since there were no other symptoms.^[9] However, none of the modalities of USS and CT scan could pick out the extragastric ectopic pancreatic tissue. This was purely an intraoperative finding.

A GDC, like every other enteric duplication cyst, is usually a true cyst. They may also be associated with an ectopic tissue. This index case has the presence of an ectopic pancreatic tissue in its mucosa and an extramural ectopic pancreatic tissue attached to it as a yellowish cord. These are intracystic and extracystic pancreatic ectopic tissue. This is unique from many other reported cases. The embryogenesis of this is not very clear except for the endodermal and foregut origins of both the stomach and the pancreas. Ectopic pancreatic tissue can secrete enzymes that may digest or lead to the erosion of the cyst wall, with resultant bleeding, peritonitis, or pancreatitis.^[1] The cyst was well vascularized, with its supply coming from the stomach. This, with its complete muscle and mucosal layers, met the criteria for GDC.^[6]

This index case had an open surgery. The cyst and the extracystic ectopic pancreatic tissue were excised en bloc with a cuff of the gastric wall. This was enough for the treatment. Laparoscopic excision is an option but was not available. Endoscopic submucosal excision of the index GDC would have led to an inadequate treatment, as it can only remove the cyst, but will not be able to pick out nor remove the extrinsic ectopic pancreatic tissue noted in this case.^[10] This would have been a great omission in the treatment. Enucleation or formation of cystogastrostomy would have been inappropriate in this case.^[1]

The removal of the cyst obviates the likely complications that may arise. A GDC can rupture causing peritonitis, from enzymatic actions of the ectopic tissue. It can also lead

to bleeding into the gastrointestinal tract.^[5] It can erode into the contiguous organs.^[5] Malignant transformation is a possibility in a GDC, when not removed.^[1] Moreover, pressure effects on the stomach and contiguous organ as well as gastric outlet obstruction can occur, leading to vomiting, epigastric pain, weight loss, epigastric fullness, dysphagia, and dyspepsia.^[10] The index case is at risk of pancreatitis from the ectopic pancreatic tissue.^[1] The early removal done in this index case has prevented these possibilities.

CONCLUSION

GDC is rare. It can co-exist with both an intramural and an extramural ectopic tissue such as pancreatic tissue. Moreover none of the current existing preoperative modality can pick out these ectopic tissues. This diagnosis is made intraoperatively and after a histopathology report. An open or laparoscopic surgical intervention is ideal for a complete diagnosis and adequate treatment.

Declaration of patient consent

The authors certify that they have obtained all appropriate patient consent forms. In the form the patient(s) has/have given his/her/their consent for his/her/their images and other clinical information to be reported in the journal. The patients understand that their names and initials will not be published and due efforts will be made to conceal their identity, but anonymity cannot be guaranteed.

Financial support and sponsorship

Nil.

Conflicts of interest

There are no conflicts of interest.

REFERENCES

1. Doepker MP, Ahmad SA. Gastric duplication cyst: A rare entity. *J Surg Case Rep* 2016;2016: rjw073.
2. Scatizzi M, Calistri M, Feroci F, Girardi LR, Moraldi L, Rubio CA, *et al.* Gastric duplication cyst in an adult: Case report. *In vivo* 2005;19:975-8.
3. Perek A, Perek S, Kapan M, Göksoy E. Gastric duplication cyst. *Dig Surg* 2000;17:634-6.
4. Takazawa S, Uchida H, Kawashima H, Tanaka Y, Sato K, Jimbo T, *et al.* Laparoscopic partial gastrectomy of a huge gastric duplication cyst in an infant. *Nagoya J Med Sci* 2015;77:291-6.
5. Surridge CA, Goodier MD. Gastric duplication cyst: A cause of rectal bleeding in a young child. *Afr J Paediatr Surg* 2014;11:267-8.
6. Xv FY, Sun A, Gan Y, Hu HJ. Gastric duplication cyst mimicking large cystic lymphangioma in an adult: A rare case report and review of the literature. *World J Clin Cases* 2019;7:2087-93.
7. Passos ID, Chatzoulis G, Miliadis K, Tzoi E, Christoforakis C, Spyridopoulos P. Gastric duplication cyst (GDC) associated with ectopic pancreas: Case report and review of the literature. *Int J Surg Case Rep* 2017;31:109-13.
8. Adejuyigbe O, Olayinka OS, Sowande OA, Abubakar AM. Gastrointestinal duplications in Ile-Ife, Nigeria. *East Afr Med J* 2002;79:134-6.
9. Taiwo OC, Fatureti OI, Taiwo AO, Adefalajo AP, Ajani MA. Gastric duplication cyst in a Nigerian infant. *J Case Reports* 2018;8:42-5.
10. Fang Y, Gao T, Yang H, Ma S, Li Q, Zhou PH. Removal of an infant's gastric duplication cyst through endoscopic submucosal dissection: A case report. *Medicine (Baltimore)* 2019;98:e14820.