

PROSTATE ADENOCARCINOMA WITH UNILATERAL TESTICULAR METASTASIS: TWO CASES WITH DIFFERENT PRESENTATIONS

Musliu Adetola Tolani¹, Muhammed Ahmed¹, Ahmad Bello¹, Balarabe Kabir², Lovely Fidelis¹, Hussaini Yusuf Maitama¹

¹Division of Urology, Department of Surgery, Ahmadu Bello University / Ahmadu Bello University Teaching Hospital, Shika-Zaria, Kaduna State, Nigeria.

²Department of Pathology, Ahmadu Bello University / Ahmadu Bello University Teaching Hospital, Shika-Zaria, Kaduna State, Nigeria.

ABSTRACT

Background: Most patients with prostate cancer present with advanced disease in sub-Saharan Africa. However, metastasis to the testis is rare.

Findings: This report details the incidental detection of isolated unilateral metastasis to the testis and epididymis from the prostate on histopathologic analysis of the orchidectomy specimen in a 77-year-old man (case 1) and the finding of palpable unilateral testicular secondary from aggressive metastatic prostate cancer in a relatively younger man (47 years old) during clinical evaluation (case 2).

Conclusion: The presentation of testicular metastasis from prostate cancer varies with the patient. A high index of suspicion in the phases of evaluation of these patients is required in order to prevent missed diagnosis.

Keywords: Prostate cancer, testicular metastasis, orchidectomy.

NigerJmed 2020: 175-177
© 2020. Nigerian Journal of Medicine

INTRODUCTION

Prostate cancer is the most common solid tumour in adults. It tends to be relatively more aggressive in black populations. In sub-Saharan Africa, where prostate cancer screening is minimal, most patients still present with advanced stages of the disease. Testicular metastasis from a prostate primary is rare despite their proximity. It was first reported by Semans about 100 years ago. It is reported by some studies to occur in 0.5-4.0% of all prostate cancer cases and is usually incidentally detected following orchidectomy for prostate cancer treatment.

CASE REPORTS

We review the presentation of 2 cases of advanced prostate cancer with unilateral testicular metastasis.

Case Report 1

A 77-year-old man who presented to the urology clinic of our hospital with obstructive and irritative lower urinary tract symptoms, weight loss and hematuria. He had no other symptoms. Digital Rectal Examination revealed an asymmetrically enlarged prostate with multiple hard nodules. Prostate-Specific Antigen (PSA) was 92 ng/ml. Trans-rectal ultrasound scan showed a prostate with

distorted parenchymal echotexture, multiple hypoechoic nodules in the peripheral zone and a breached capsule. A tru-cut biopsy was done, and the histology revealed prostate adenocarcinoma, Gleason score 7 (3+4). The metastatic survey revealed no evidence of distant spread.

A diagnosis of locally advanced prostate cancer with clinical stage of T₄N₀M₀ was made. The patient was counselled for androgen deprivation therapy and opted for orchidectomy. The histological analysis of the testicular tissue, removed at orchidectomy, revealed metastatic adenocarcinoma involving the left testicular tissue and epididymis (Figure 1). Post-hormonal ablation testosterone level was 0.3ng/ml. He is currently 15 months on follow up and has been asymptomatic.

Case Report 2

A 47-year-old man referred from a secondary health care facility with transfusion-dependent anaemia of 4 months duration. He had been transfused with a total of 10 units of blood. He also had a history of significant weight loss, anorexia and generalized body weakness as well as low back pain and lower limb weakness. No lower urinary tract symptoms or haematuria. Examination revealed a cachectic, pale-looking patient with left-sided facial nerve palsy (upper motor neuron type), nodular right testis and an enlarged prostate with a hard, nodular surface on both lobes and obliterated median groove. Retroviral screening and Mantoux test were negative. The metastatic survey showed widespread abdominal masses in the region of the pancreatic body and adrenal gland, multiple osteolytic lesions in the lumbar vertebrae and pelvic bones and right-sided pleural effusion. Serum Prostate Specific Antigen was >100 ng/ml. Prostate biopsy revealed adenocarcinoma, Gleason score 8 (5+3).

Correspondence to:

Dr. Musliu Adetola Tolani,
Division of Urology,
Department of Surgery,
Ahmadu Bello University Teaching Hospital,
P.M.B. 06, Shika-Zaria, Kaduna State, Nigeria.
E-mail: adetolatolani@yahoo.com
+234 8035646382

A diagnosis of metastatic prostate cancer (T₄N₁M_{1c}) was made. Due to his poor performance status, the patient was resuscitated, counselled and placed on androgen deprivation therapy (depot injection of 3.6mg Goserelin) as first-line therapy. He later consented for bilateral orchidectomy where histology of the right testis confirmed metastatic adenocarcinoma (Figure 2).

Prostate-Specific Antigen 6 months after hormonal ablation was still > 100 ng/ml and he is presently on combined androgen blockade in our follow-up clinic.

DISCUSSION

Metastasis of solid tumours to the testis are generally rare; however, the prostate represents its most common primary site. Oranusi et al. noted that two-third of the secondary metastasis to the testis were from the prostate, while Haupt et al. published that it represents 35% of all secondary testicular tumours.

The patients diagnosed with this rare metastasis tend to be older than those with primary testicular tumours. Most of the reports of patients with testicular metastasis of prostate cancer were in their seventh decade of life. Others have reported patients in their eight-decade in line with the age of the patient in case report 1. An old patient with an abnormal testis could suggest metastasis from a primary tumour. However, the occurrence of testicular metastasis in a 47-year-old male in the second case is similar to the observation of Kyei et al. in Accra. This suggests that these secondaries could occur in young men with aggressive prostate cancer.

Prostatic urethral involvement increases the likelihood of testicular metastasis; this might have occurred in the first case who presented with LUTS. This is similar to the report by Zhang et al. in which the patient presented with the same symptom. Spread to the testis could occur by direct invasion, lymphatic spread, retrograde venous involvement and arterial embolism. In addition, the pattern of metastatic infiltration could be intertubular, intratubular with/out vascular and lymphatic invasion. In case report 1, a lesion was found in the epididymis suggesting a probable extension through the vas (endocanalicular route). This is in contrast to the report by Chapagain et al. in which there was no lesion in the epididymis. The widespread metastatic lesion in the second case report could mean that the testicular spread occurred via the haematogenous route.

Risk factors for testicular metastasis include high PSA levels and high Gleason's score. Unlike the first case, the aggressiveness of cancer in the second case is highlighted by its higher primary Gleason's grade and higher Gleason's score. Most of the PSA in previous studies were greater than 100 ng/ml, similar to the finding in the second report. Others have however documented a PSA of less than 100 ng/ml which is similar to the reported PSA found in our first case.

Patients with testicular metastasis from the prostate tend to have widespread metastases at other sites as seen in the second case. Korkeas et al. noted that all their patients had bone and lung metastasis. However, the first case did not have any evidence of distant cancer spread within the limits of the investigations done.

Testicular metastasis from a prostate primary is usually

incidentally detected during autopsies or following bilateral orchidectomy and could present as a synchronous or metachronous lesion. In the first case, the clinically silent unilateral testicular metastasis was incidentally detected at orchidectomy done 3 months after the diagnosis of the primary tumour while the metastasis in the second case presented as a clinically palpable nodule felt on the examination of the testes.

Reported cases of these testicular secondaries are usually unilateral but may be bilateral in a lesser proportion of cases. The metastasis to the testis in both cases reported in this study were unilateral. This is in consonance with the work of Korkeas et al. in which 2 of the 3 patients reported had unilateral metastasis. However, Kim et al. reported bilateral involvement of the testis. Others have also reported testicular metastasis presenting as a painless palpable testicular mass (13-23%) which creates diagnostic difficulty differentiating it from primary testicular cancer. In testicular metastasis from prostate cancer, it is possible that orchidectomy plays a more important role in treatment because Su et al. noted that it provided a means for the extirpation of the prostate cancer cells including isolated ones at this immune-privileged site. However, the persistence of PSA following this treatment in the second case could be related to the poor response of the metastatic tumour cells at the other sites to first-line androgen deprivation therapy. As such, the patient was placed on combined androgen blockade.

The significance of testicular metastasis in the prognosis of prostate carcinoma is uncertain in view of its rarity in advanced disease. Survival after diagnosis is usually less than 1 year. Korkeas et al. reported a post-orchidectomy median survival of 5.3 months. In the first case, the patient has lived 15 months post-orchidectomy without symptoms, while the patient in the second case has lived for 6 months post-orchidectomy.

Other options have also been used in the treatment of metastatic prostate cancer. There is a need to compare oncologic outcomes of orchidectomy with the use of LHRH analogues and systemic chemotherapy in patients having prostate cancer with testicular metastasis.

In conclusion, the presentation of testicular metastasis from prostate cancer varies with the patient. A high index of suspicion in the phases of evaluation of these patients is required in order to prevent missed diagnosis.

FIGURES

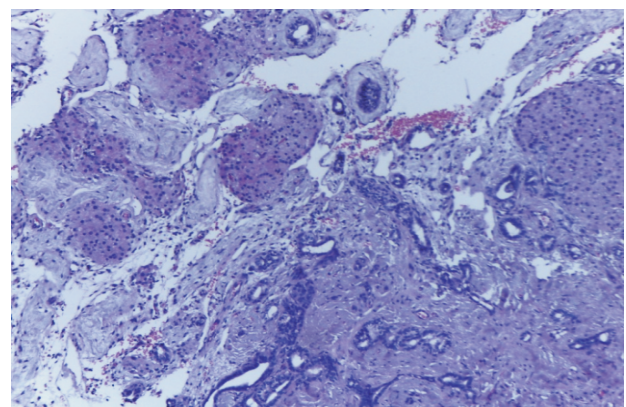


Figure 1: Metastatic adenocarcinoma to the testis and epididymis (HE Stain, X100)

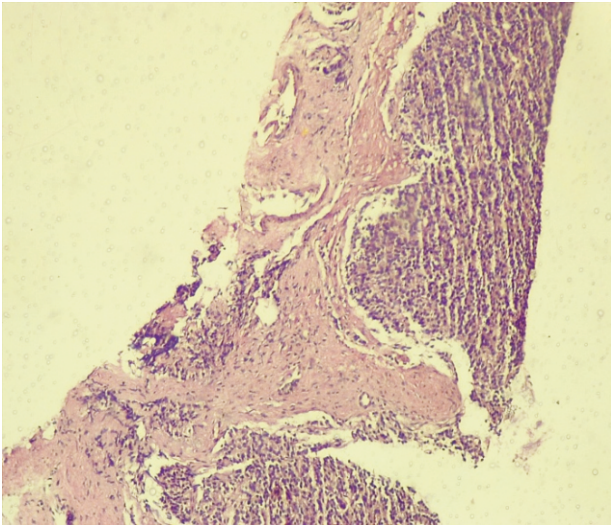


Figure 2: Metastatic adenocarcinoma to the testis (HE Stain, X100)

REFERENCES:

- Berkmen F, Ayyıldız A, Ardicoglu A. Testicular metastasis from adenocarcinoma of the prostate: a review of literature and report of two cases. *Prostate J.* 2000;2:42-4.
- Campara Z, Simic D, Aleksic P, Spasic A, Milicevic S. Metastasis of prostate adenocarcinoma to the Testis. *Case Rep.* 2016;70:318-20.
- Kusaka A, Koie T, Yamamoto H, et al. Testicular metastasis of prostate cancer: a case report. *Case Rep Oncol.* 2014;7:643-7.
- Su J, Aslim EJ, Aydin H, Tan PH, Sun H, Ho HSS. A rare case of isolated castrate-resistant bilateral testicular metastases in advanced prostate cancer. *Asian J Urol.* 2017;1-4.
- Oranusi CK, Onyiaorah I V, Ukah CO. Pattern of testicular biopsies as seen in a tertiary institution in Nnewi, Southeast Nigeria. *Niger J Surg.* 2014;20:55-8.
- Haupt HM, Mann RB, Trump DL, Abeloff MD. Metastatic carcinoma involving the testes: clinical and pathologic distinction from primary testicular neoplasm. *Cancer.* 1984;54:709-14.
- Sampathrajan S, Garg G, Gupta S, Sahay SC, De S. Incidentally detected testicular metastasis in a case of prostatic adenocarcinoma. *J Clin Diagnostic Res.* 2015;9:3-4.
- Chapagain U, Neupane S, Tuladhar S, Pradhananga S, Basnet RB, Regmi S. Prostatic cancer with metastasis to the testis- a case report. *J Pathol Nepal.* 2015;5:784-6.
- Kwon SY, Jung HS, Lee JG, Choi SH, Kwon TG, Kim TH. Solitary testicular metastasis of prostate cancer mimicking primary testicular cancer. *Korean J Urol.* 2011;52:718-20.
- Rahardjo HE, Umbas R, Sutisna H. Testicular metastases from prostate carcinoma. *Asian J Surg.* 2010;33:154-6.
- Kim SO, Choi YD, Jung SI, et al. Prostate cancer with solitary metastases to the bilateral testis. *Yonsei Med J.* 2011;52:362-4.
- Deb P, Chander Y, Rai RS. Testicular metastasis from carcinoma of prostate: report of two cases. *Prostate Cancer Prostatic Dis.* 2007;10:202-4.
- Kyei MY, Vanderpuye V, Edusei L, Mensah JE, Yarney J. Metastatic prostate cancer to the testis as an initial presentation: management, review and outcome. *Int J Case Reports Images.* 2016;7:449-53.
- Zhang J, Dong M, Hu X, et al. Prostatic adenocarcinoma presenting with metastases to the testis and epididymis: a case report. *Oncol Lett.* 2016;11:792-4.
- Korkes F, Gasperini R, Korkes KL, Neto DCVS, Castro MG. Testicular metastases: a poor prognostic factor in patients with advanced prostate cancer. *World J Urol.* 2009;27:113-5.
- Baykal K, Yildirim S, Inal H, et al. Metastasis of prostate adenocarcinoma to testis. *Int J Urol.* 1997;4:104-5.
- Kirkali Z, Reid R, Deane RF, Kyle KF. Silent Testicular Metastasis from Carcinoma of the Prostate. *Br J Urol.* 1990;66:205-7.