

## OROFACIAL MELANOMAS; A REPORT OF THREE CASES

<sup>1</sup>Chidozie Onwuka, <sup>1</sup>Chibuzor Uguru, <sup>2</sup>Mark Nwaoga, <sup>1</sup>Uche Mgbeokwere,  
<sup>1</sup>Uche Okechi, <sup>2</sup>Chukwubuzor Okwuosa, <sup>1</sup>Obiora Umeanuka, <sup>3</sup>Chidinma Onwuka

<sup>1</sup>Department of Oral and Maxillofacial Surgery, University of Nigeria Teaching Hospital, Enugu

<sup>2</sup>Department of Oral and Maxillofacial Pathology, University of Nigeria Teaching Hospital, Enugu

<sup>3</sup>Department of Obstetrics and Gynaecology, University of Nigeria Teaching Hospital, Enugu

### ABSTRACT

**BACKGROUND:** Oro-facial melanomas are rare malignancies of the maxillofacial region accounting for 0.5% of malignancies seen in oral mucosa. This is a case series of three case reports of orofacial melanomas highlighting their management and outcome in our centre.

**FINDINGS:** The cases reported are of three oro-facial melanomas occurring in two females and a male. The age range of the patients was 40-68 years. There were two cases of melanoma of the palate and gingivae and a single case of melanoma of the parotid gland. All the patients presented with stage IV tumours. Of the three cases one died within few weeks of presentation while the remaining two are alive and under review.

**CONCLUSION:** Orofacial melanomas are rare painless lesions which are wrongly considered non-harmful in our environment thus leading to late presentation and poor prognosis.

NigerJmed2019: 88 - 92  
© 2019. Nigerian Journal of Medicine

## INTRODUCTION

Melanomas are melanocyte containing malignant tumours arising from cells of neural crest origin which constitute the melanin pigment in the basal and suprabasal layers of the epithelium.<sup>1</sup> It is more of a cutaneous tumour however, extracutaneous tumour are rare and aggressive.<sup>2</sup> Oro-facial melanomas are rare malignancies of the maxillofacial region accounting for 0.5% of malignancies seen in oral mucosa.<sup>3</sup> In Nigeria oral melanomas accounts for 0.9% of all the melanomas.<sup>4</sup> Malignant melanomas could be amelanotic and this accounts for less than 10% of oral melanomas.<sup>5</sup>

The most frequent site of occurrence of melanomas in the oral cavity are the hard palate and the maxillary gingiva<sup>6</sup> but a secondary satellite from a cutaneous lesion may be located in the tongue, parotid and tonsils.<sup>3</sup> Oral malignant

melanomas may occur with or without radial growth<sup>7</sup>. In some cases, melanosis (radial growth) may occur before the vertical growth<sup>6,8</sup>. Oral malignant melanomas may be grouped into 5 types<sup>9</sup> which include, pigmented nodular, non-pigmented nodular, pigmented macular, pigmented mixed and non pigmented mixed. The lesions are active biologically and are silent clinically presenting as hyper pigmentation of the areas involved in their early stages.<sup>1</sup>

Their colours may range from black, red, purple or gray<sup>10</sup>. In contrast to cutaneous melanomas, primary extracutaneous malignant melanoma are of unknown etiological and intraoral risk factors<sup>10</sup> Treatment modalities for orofacial malignant melanomas include surgery with 5mm-20mm margin<sup>11</sup>, chemotherapy or immunotherapy and radiotherapy.<sup>2</sup>

Chemotherapy and radiotherapy are controversial as treatment modalities<sup>11,12</sup>; however, adjuvant radiotherapy has been reported to be beneficial in patients with aggressive melanomas.<sup>13,14</sup>

**Corresponding author:** Dr. Onwuka Chidozie,  
Department of Oral and Maxillofacial Surgery,  
University of Nigeria Teaching Hospital, Enugu  
**Email:** chidozie.onwuka@unn.edu.ng

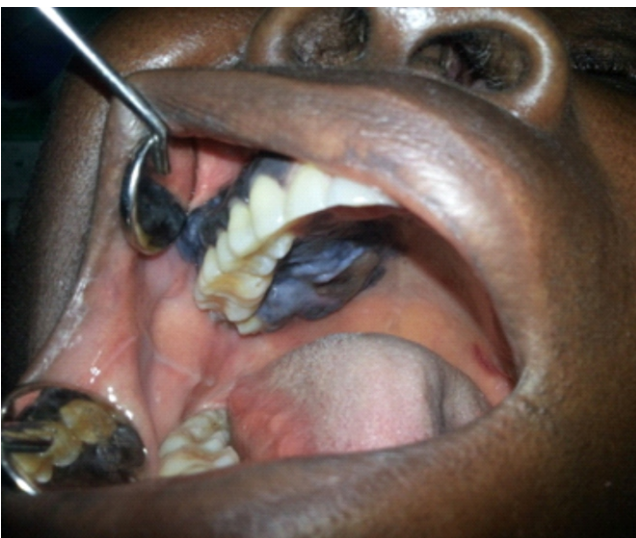## CASEREPORT 1

A 64-year-old female, a retired school teacher presented with a year history of a dark painless ulcerated mass on the palate. Patient claimed to have noticed the lesion more than a decade before presentation. She claimed to have visited many doctors who always reassured her until recently. A biopsy was done on a dark hyperpigmented palatal patch one year prior to presentation with diagnosis as pigmented epitheloid melanocytoma. There were no associated medical conditions, no history of tobacco or alcohol use. On clinical examination we found an ulcerated, nodular mass on the right side of the hard palate with irregular margins.

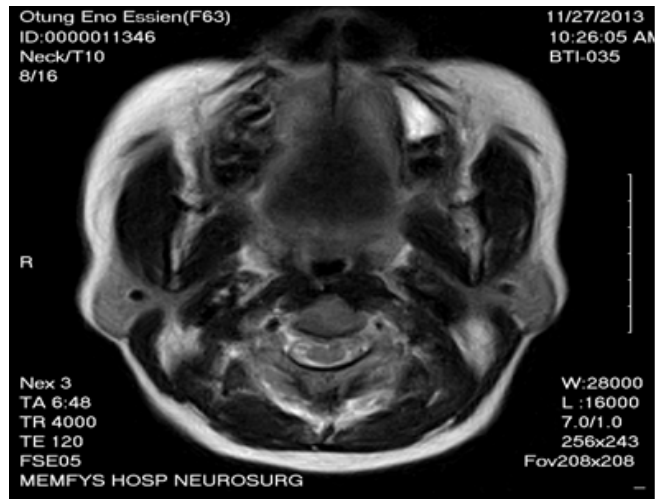
The swelling extended from the upper right lateral incisor to upper last molar (buccally) and from the gingival margin of upper right lateral incisor to the soft palate (palatally) and measured about 5cm by 3cm, and was firm in consistency. Sentinel node biopsy was done which came out negative. Computerized Tomography (CT) scan showed localized lesion in the right palate with features suggestive of malignant melanoma.

A diagnosis of stage IV oral mucosa malignant melanoma was made. She had subtotal maxillectomy with post surgery histology reaffirming the malignant melanoma diagnosis. She was then referred to radiotherapy unit six weeks later where she had chemo-radiotherapy. Four years after surgery patient is still clinically free from the tumor and was fully rehabilitated with an obturator.

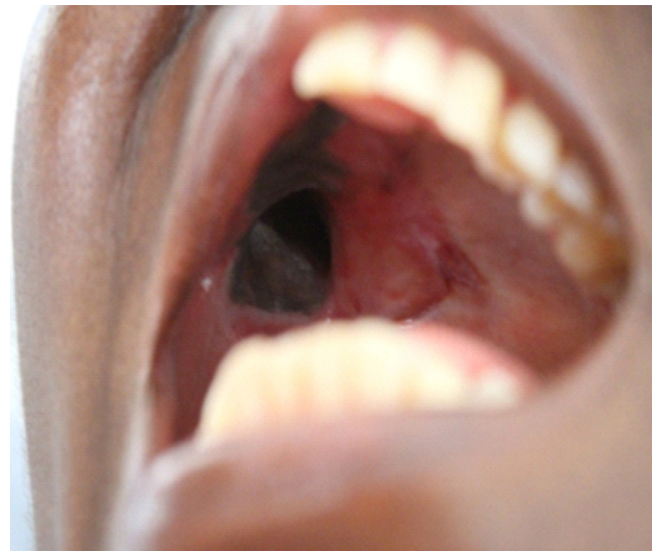**Figure 1: Patient with the tumour pre-surgery**



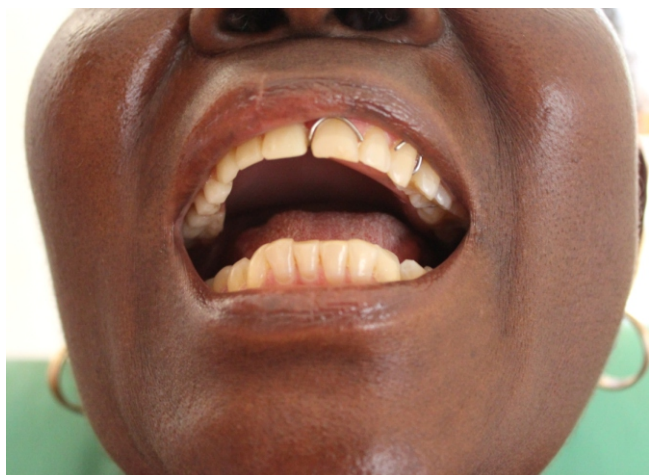**Figure 2: CT-Scan of patient 1**



**Figure 3: Patient 1 post surgery. Dark area inside is the skin graft laid after maxillectomy**



**Figure 4: Post surgical obturator rehabilitation of patient 1**





## CASE REPORT TWO

A 68year old female who presented to the casualty with left sided facial pain x 5/7 and left facial swelling of a year duration. The swelling was initially painless but became painful with increasing size. Pain radiates to the ipsilateral ear, cervical and clavicular area.

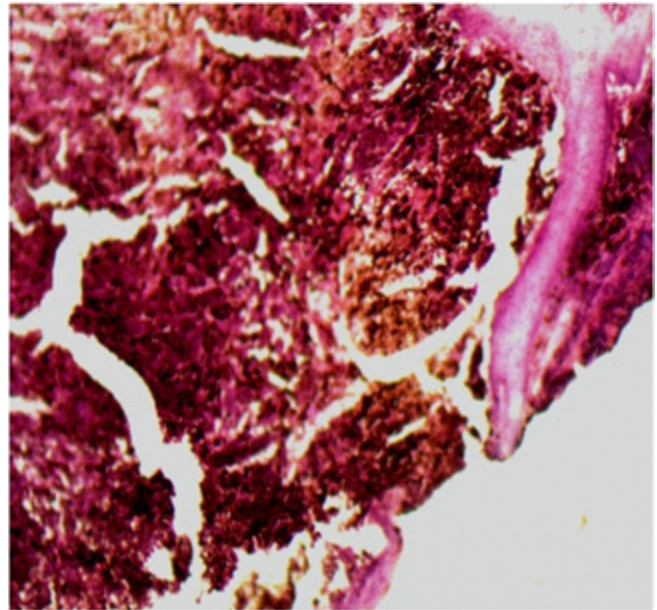
There was history of repeated surgical excision of a nodular scalp lesion long before the appearance of the facial swelling. There was no history of alcohol or tobacco use. On examination, the elderly woman in obvious painful distress with a parotid swelling measuring 8cm x 6cm in diameter. There were multiple firm nodular masses measuring about 2cm x 1.5cm each on left side of the scalp with a single nodular mass on the right side of the scalp.

There was slight ipsilateral tenderness over the stenoideomastoid muscles and mid clavicular area with enlarged cervical lymph nodes which were matted together. The patient's blood pressure was 170/90mmHg with a pulse rate of 86b/min. An impression of left sided facial pain?Nerve compression by mitotic lesion was made. Pain was controlled using strong analgesics and blood pressure was brought under control by the medical team.

Computer tomography (CT) scan showed a parotid mass with an impression suggestive of pleomorphic adenoma. Chest x-ray showed a clinically clear chest with no mitotic lesion. Incisional biopsy of the lesion and cervical node was done and diagnosis of malignant melanoma with positive nodes was made. Left partiectomy without preservation of facial nerve with neck dissection was done after obtaining informed consent.

Scalp lesion was also excised. Patient was discharged few days later and was referred for chemo-radiotherapy after 6 weeks. However, patient is still awaiting radiotherapy. Six months after surgery, no obvious sign of reoccurrence has been noted.

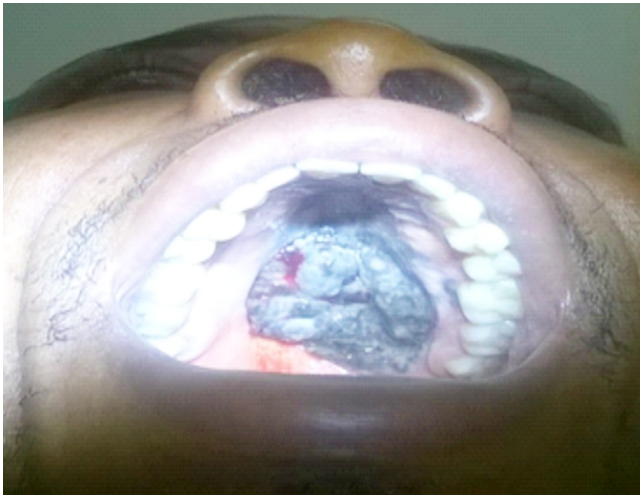**Figure 5: Photomicrograph of Oral melanoma showing mucosal epithelium (periphery), junctional activity and deposits of brownish dark pigments (Hematoxylin-Eosin, magnification x4) of Patient 2**



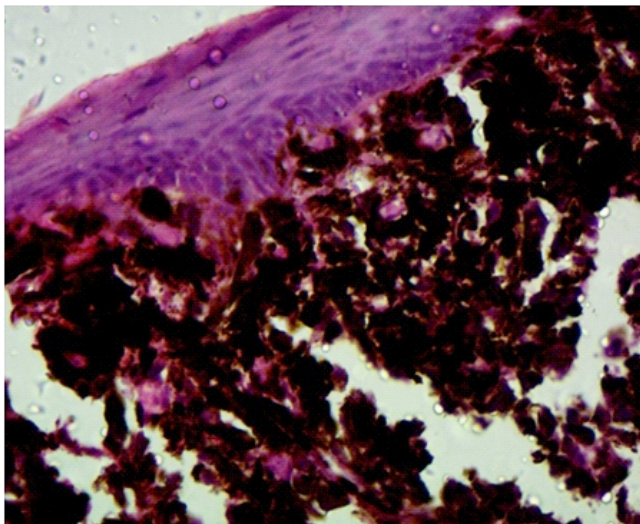
## CASE REPORT 3

A 40year man who presented to the clinic with 7months history of palatal swelling that bled spontaneously and had been increasing in size. On examination, we noted a black midline nodular mass from the posterior margin of the hard palate measuring about and 7cm x 4cm in diameter and extending anteriorly to the upper incisors. The mass was painless, ulcerated and bled on touch. There were multiple bilateral nodular lesions in the neck suggestive of metastatic lymph nodes. The cervical lymph nodes were enlarged, fixed and matted together. Patient appeared weak and was admitted for resuscitation and further treatment. There were positive mitotic lesions noted on the chest x-ray. Biopsy of the lesion revealed a malignant melanoma. Patient was referred to the palliative care unit for further management. Unfortunately, patient died few weeks after presentation.

**Figure 6: Patient 3 with palatal malignant melanoma**



**Figure 7: Photomicrograph of Oral melanoma showing mucosal epithelium (upper periphery), large malignant melanocytes in junctional activity and deposits of brownish dark pigments in subepithelial stroma (Hematoxylin-Eosin, magnification x40)**



## DISCUSSION

Melanomas are rare lesions that are biologically aggressive, often undetected and asymptomatic in early stages and are usually presenting as hyperpigmented patches<sup>1</sup>. Because of this clinical silence, patients usually present late as seen in the cases in our study. Literature noted higher incidence of oral melanomas in males than females<sup>1,15</sup> but in this study 2 out of the 3 cases we reported were females which was in agreement with Koomen et al<sup>16</sup> who reported female preponderance. Our patients were within the age range reported in literature<sup>17</sup> which was 40-70 years. Bishop et al<sup>18</sup> noted high incidence in

older patients as compared to patients under 60 years though, one patient in our report was 40 years old. The parotid melanoma was a secondary lesion from the scalp melanoma and this was in agreement with Gao et al<sup>19</sup> report that noted parotid gland melanomas to be mainly metastatic, usually originating from primaries in the skin of the head and neck.

Two patients underwent surgery with neck dissection in one patient as a result of positive neck nodes. Elective neck dissection has been advocated in management of oro-facial melanomas<sup>20</sup>, however, there are controversies in management of clinically negative neck nodes.<sup>21,22</sup> One patient had post-operative radiotherapy which appears to be very useful as there are no signs of recurrence more than four years post-operatively, this agrees with findings of Teman et al<sup>13</sup> and Ballo et al<sup>14</sup> which suggested that adjuvant radiotherapy may be useful in the management of malignant melanoma. Orofacial malignant melanoma's overall survival rate is poor.<sup>22,23</sup>

Trapp et al<sup>24</sup> noted that poor prognosis is associated with late diagnosis. Patients usually present with advanced stage of the lesion and sometimes with metastases as seen in our cases with one patient dying within weeks of presentation as a result of late diagnosis.

In conclusion, Orofacial melanomas are rare in our environment and are often considered as non-harmful lesions leading to late presentation with increased chances of mortality. Adjuvant radiotherapy appears to be useful in reducing the chances of recurrence as was seen in one of our cases.

## REFERENCES

1. Kumar A, Bindal R, Shetty DC, Singh HP: Principle oral malignant melanoma, clinics patho series of four cases. *Dent Res J* 2012; 9(3): 33-44.
2. Warszawik-Hendzel O, Słowińska M, Olszewska M, Rudnicka L. Melanoma of the oral cavity: pathogenesis, dermoscopy, clinical features, staging and management. *J Dermatol Case Rep*. 2014 Sep 30; 8(3): 60-66.
3. Padhye A and D'Souza J. Oral malignant melanoma: A silent killer, *J Indian Soc periodontal*: 2011; 15(4): 425-428.
4. Goubran CIF, Adekeye E O, Edwards M B, melanoma of the face and mouth in Nigeria. A review and comment on 3 cases. *Int J Oral Surg* 1978; 7: 453-462.



5. Hicks MJ, Flaitz CM: Epidemiology and pathology of oral melanoma. *Oncol* 2000; 36: 152-169.
6. Tanaka N, Mimura M, Ogi K, Amagasa T. Primary malignant melanoma of the oral cavity: assessment of outcome from the clinical records of 35 patients. *Int J Oral Maxillofac Surg.* 2004; 33:761-765.
7. Manolidis S, Donald PJ. Malignant mucosal melanoma of the head and neck: review of the literature and report of 14 patients. *Cancer.* 1997; 80:1373-1386.
8. Hsieh R, Nico MM, Coutinho-Camillo CM, Buim ME, Sanguenza M, Lourenço SV. The CDKN2A and MAP kinase pathways: molecular roads to primary oral mucosal melanoma. *Am J Dermatopathol.* 2013;35:167-175.
9. Nandapalan V, Roland NJ, Helliwell T R, Williams D M, Hamilton J W, Jones A S; Mucosal melanoma of the Head and Neck. *Clin Otolaryngol Allied Sci* 1998; 23: 107-116
10. Penel N, Mallet Y, Mirabel X, Van JT, Lefebvre JL. Primary mucosal melanoma of head and neck: prognostic value of clear margins. *Laryngoscope.* 2006;116:993-995
11. Kienstra MA, Padhya TA. Head and neck melanoma. *Cancer Control.* 2005 Oct;12(4):242-247
12. Kingdom TT, Kaplan MJ. Mucosal melanoma of the nasal cavity and paranasal sinuses. *Head Neck.* 1995;17:184-189
13. Ballo MT, Bonnen MD, Garden AS. Adjuvant irradiation for cervical lymph node metastases from smelanoma. *Cancer.* 2003;97(7):1789-96
14. Temam S, Mamelle G, Marandas P, et al. Postoperative radiotherapy for primary mucosal melanoma of the head and neck. *Cancer.* 2005;103(2):313-19
15. Haiducu ML, Hinek A, Astanehe A, Lee TK, Kalia S. Extracutaneous melanoma epidemiology in British Columbia. *Melanoma Res.* 2014;24:377-80
16. Koomen ER, de Vries E, van Kempen LC, van Akkooi AC, Guchelaar HJ, Louwman MW, Nijsten T, Coebergh JW. Epidemiology of extracutaneous melanoma in the Netherlands. *Cancer Epidemiol Biomarkers Prev.* 2010; 19:1453-1459.
17. Smyth AG, Ward-Booth RP, Avery BS. Malignant melanoma of the oral cavity: An increasing clinical diagnosis. *Br J Oral Maxillofac Surg.* 1993;31:230-235
18. Bishop KD, Olszewski AJ. Epidemiology and survival outcomes of ocular and mucosal melanomas: A population-based analysis. *Int J Cancer.* 2014;134:2961-2971.
19. Gao N., Li L.-J, Li Y, Wang L. Primary amelanotic malignant melanoma of the parotid gland: a case report. *Journal of International Medical Research.* 2008; 36(6): 1435-1439. doi: 10.1177/147323000803600633
20. Mendenhall WM, Amdur RJ, Hinerman RW, Werning JW, Villaret DB, Mendenhall NP. Head and neck mucosal melanoma. *Am J Clin Oncol.* 2005;28:626-630
21. Rapidis AD, Apostolidis C, Vilos G, Valsamis S. Primary malignant melanoma of the oral mucosa. *J Oral Maxillofac Surg.* 2003; 61:1132-1139.
22. Patel SG, Prasad ML, Escrig M, et al. Primary mucosal malignant melanoma of the head and neck. *Head Neck.* 2002; 24: 247-257.
23. Yii NW, Eisen T, Nicolson M, et al. Mucosal malignant melanoma of the head and neck: the Marsden experience over half a century. *Clin Oncol (R Coll Radiol).* 2003; 15: 199-204.
24. Trapp TK, Fu YS, Calcaterra TC. Melanoma of the nasal and paranasal sinus mucosa. *Arch Otolaryngol Head Neck Surg.* 1987;113:1086-1089