

Retinoblastoma in Calabar Nigeria: An 18-Month Retrospective Review of Clinical Presentation at a Tertiary Eye Center

Elizabeth Dennis Nkanga¹, Iwassam Elemi Agbor², Sunday Nnamdi Okonkwo³, Ido Didi Fabian⁴, Ekperonne Babatunde Esu⁵, Dennis George Nkanga⁶, Friday Akwagiobe Odey⁷, Jacintha Banku Okoi-Obuli⁷

¹Department of Ophthalmology, Paediatric Ophthalmology and Strabismus Unit, University of Calabar, ²Department of Community Medicine, University of Calabar, ³Department of Ophthalmology, Oculoplastic Unit, University of Calabar, ⁴International Centre for Eye Health, London School of Hygiene and Tropical Medicine, London UK, ⁵Department of Public Health, Epidemiology Unit, University of Calabar, ⁶Department of Ophthalmology, Medical Retina Unit, University of Calabar, ⁷Department of Paediatrics, Oncology Unit, University of Calabar, Calabar, Cross River State, Nigeria

Abstract

Background: Retinoblastoma, although rare, is the most frequently occurring primary intraocular tumor of childhood. While a cure is often achieved where appropriate treatment is instituted early in the disease, late presentation often leads to unsuccessful treatment interventions. **Aim:** The aim of this study is to provide baseline information on the clinical presentation of retinoblastoma as seen in a tertiary pediatric eye care facility in Calabar, Nigeria. **Materials and Methods:** A retrospective review of case files of children presenting to the Calabar Children's Eye Center (CCEC) with retinoblastoma over 18 months from January 1, 2018 to June 30, 2019 was done. **Results:** Data were collected from 39 children with retinoblastoma who met the inclusion criteria. There were 22 (56.4%) males and 17 (43.6%) females, and the age range was 7–41 months, with a mean age of 25.6 (± 9.0) months. Unilateral disease was seen in 27 (69.2%) participants, whereas 12 (30.8%) had bilateral disease. Although multiple symptoms were seen in many participants protrusion of eye was the most frequently occurring first symptom, (17, 44.0%) followed by red eye (13, 33.0%), whiteman in eye (5, 13.0%), and abnormal alignment (4, 10.0%) among study participants. The lag time from recognition of symptoms to initial consultation ranged from 1 to 25 months, with a mean lag time of 9.13 ± 5.68 months. The ICRB classification system was most frequently used, 27 (69.2%), followed by cTNMH 11 (28.2%), and International Intraocular Retinoblastoma Classification 1 (2.6%). The International Retinoblastoma Staging System was representative. Of the 78 eyes studied, (51, 65.3%) had different stages of retinoblastoma with the majority presenting as advanced retinoblastoma (46, 90.2%). **Conclusions:** Retinoblastoma is seen at the CCEC. Although the most frequent symptom was protrusion of eye, the lag time was often several months long. Most patients presented late with advanced ocular retinoblastoma and or extraocular disease.

Keywords: Calabar, Nigeria, presentation, retinoblastoma

INTRODUCTION

Retinoblastoma is a malignant tumor that originates in the retina of young children. The vast majority of cases present before the age of five years.^[1] Although a rare clinical entity; however, retinoblastoma is the most common ocular malignancy of childhood.^[2] In some developing countries in Africa, it is one of the most frequently presenting solid tumors seen in childhood.^[3-5] In Nigeria, it is the second most common childhood tumor,^[3,4,6] and the most commonly occurring ocular tumor.^[7-9] Its incidence has been estimated to be 1:15,000–1:18,000 live births,^[2] and it does not have any gender, racial, or seasonal predilections.^[2,10-12] About a third of all tumors are said to have been genetically determined (i.e.,

germ line retinoblastoma)^[2,10,11] and less than 10%, have a positive family history.^[1]

More than 50 years after the first cases of retinoblastoma were reported in Nigeria,^[13] there is a persistent and urgent need to improve early detection rates and access to

Address for correspondence: Dr. Elizabeth Dennis Nkanga, Department of Ophthalmology, Paediatric Ophthalmology and Strabismus Unit, University of Calabar, Calabar, Cross River State, Nigeria. E-mail: bettienkanga@gmail.com

This is an open access journal, and articles are distributed under the terms of the Creative Commons Attribution-NonCommercial-ShareAlike 4.0 License, which allows others to remix, tweak, and build upon the work non-commercially, as long as appropriate credit is given and the new creations are licensed under the identical terms.

For reprints contact: WKHLRPMedknow_reprints@wolterskluwer.com

How to cite this article: Nkanga ED, Agbor IE, Okonkwo SN, Fabian ID, Esu EB, Nkanga DG, *et al.* Retinoblastoma in Calabar Nigeria: An 18-month retrospective review of clinical presentation at a tertiary eye center. Niger J Med 2022;31:149-55.

Submitted: 31-Oct-2021

Revised: 12-Jan-2022

Accepted: 18-Jan-2022

Published: 29-Apr-2022

Access this article online

Quick Response Code:



Website:
www.njmonline.org

DOI:
10.4103/NJM.NJM_184_21

effective treatment strategies in the care of children with retinoblastoma in our region. Where children present late, treatment is very often mutilating and unsuccessful.^[14] Without treatment, retinoblastoma usually leads to death.^[11,13-16] Aggressive multimodal therapy and a follow-up period that is individualized, thorough, and unrelenting^[5,8,14,17-20] is key in the treatment protocol to save life, the eye, with useful vision where possible. Where the disease is advanced, the use of systemically administered chemotherapy given cyclically with appropriate individualized adjuncts has demonstrated success in terms of survival and quality of life after the commencement of treatment.^[8,14,18] A multidisciplinary team approach remains the standard of care for all children with retinoblastoma.^[1,14]

At present, there appears to be a dearth in the availability of data on the current state with respect to the clinical findings of retinoblastoma in Calabar, Cross River State (CRS), Nigeria. Treatment outcomes have been said to be more successful where there is applied knowledge on the prevailing pattern of presentation as this can lead to more effective interventions at primary, secondary, and tertiary levels of health care.^[1,8,12,14,17] This research aims to present clinical findings at disease presentation and staging of retinoblastoma at diagnosis, as seen in a tertiary, referral, pediatric eye care facility in Calabar, Nigeria.

MATERIALS AND METHODS

This was a retrospective consecutive case series. All patients recruited into this study were reviewed and managed by a multidisciplinary team that included a pediatric oncologist and hematologist, ophthalmologist, medical social worker, radiologist, and pharmacist. The case notes of all children with retinoblastoma seen in the Calabar Children's Eye Center (CCEC) over an 18-month period beginning January 01, 2018–June 30, 2019 were reviewed and a predesigned data collection form was completed. Information retrieved included gender, family history of retinoblastoma, age at time of diagnosis, duration of symptoms, laterality, symptoms and signs at presentation, lag period from initiation of symptoms to presentation at our center, clinical features, and initial interventions received.

All patients in this study had the diagnosis of retinoblastoma first made clinically by an ophthalmologist supported by ocular, orbital and brain imaging, including ocular A, and B ultrasound scan using a 10 MHz ophthalmic probe, brain computed tomographic scan or magnetic resonance imaging to exclude extension into the orbit or the central nervous system. Relevant data on the criteria for high-risk retinoblastoma, including histopathological features, were collected. Each retinoblastoma case was classified using one of three classification systems, namely the International Classification for Intraocular Retinoblastoma (ICRB), the International Intraocular Retinoblastoma Classification (IIRC) system and the cTNMH classification.^[21] However, for the purpose of uniformity of classification, each case was reclassified using the International Retinoblastoma Staging System (IRSS).^[21] A

histopathological diagnosis was given to support the clinical diagnosis where an enucleation was performed. In these cases, in addition, the pathologist was asked to indicate whether high-risk histopathology features existed,^[22,23] in which case adjuvant systemic chemotherapy was delivered.

Patients who received primary treatment elsewhere were excluded from the analysis, as well as patients for whom key data features were missing.

The lag time, which includes delay from the parents and delay from professionals, was defined as the time between the onset of the symptoms of retinoblastoma and retinoblastoma diagnosis.^[24] For this study, lag time relates to the delay in diagnosis.

Statistics/data management

Data analysis was done using the Statistical Package for the Social Sciences Windows version 20.0 (IBM-SPSS, Chicago, IL, USA). Pearson Chi-squared tests or Fischer's exact tests were used for the categorical data. We expressed numerical data as mean and standard deviation (SD). We expressed the categorical data as percentages. Where the $P < 0.05$, this was considered as statistically significant.

Ethical consideration

Ethical approval to conduct the study was obtained from the Health Research and Ethics Committee of the UCTH Calabar, CRS. Ethical approval number UCTH/HREC/33/689. This is in keeping with the tenets of the Helsinki Declaration.

RESULTS

A total of 46 children with retinoblastoma, presented to our treatment center during the study period. However, data from the case files of (39, 84.7%) children were used for this study while 7 children with retinoblastoma were excluded from the study because of missing data (relevant for the study). Of the 39 children that formed the study population, the age range was seven months to 41 months. The mean age was 25.6 months \pm SD 9.0, with a total of (24, 61.5%) of study participants older than 25 months (two years one month) of age and the remainder (15, 38.5%) being <25 months of age.

The highest frequency of respondents was in the 25 months to 36 months age group (20, 51.3%). This is presented in Table 1. There is a slight male preponderance in our study, as 22 (56.4%) were males, whereas 17 (43.6%) were females. The male-to-female ratio was 1.3–1.0. Regarding the lag time description of the study population, the mean symptom duration was 9.13 \pm 5.68, with the shortest lag time being one month and the longest being an alarming 25 months. A total of eight patients who had the longest lag times (>12 months) had protruding eyes at presentation; evidence of orbital disease. There were no study participants with a positive family history of retinoblastoma.

Furthermore, in Table 1, the relationship between retinoblastoma laterality, age and sex at presentation, was explored. More younger children presented with unilateral retinoblastoma than older children (73.3% vs. 66.7%); however, the difference

Table 1: Relationship between laterality of retinoblastoma and age as well as sex of children under study

	Retinoblastoma			Chi square test	P
	Unilateral (27; 69.2%), n (%)	Bilateral (12; 30.8%), n (%)	Total (39; 100.0%), n (%)		
Age group/months					
0-12	4 (100.0)	0	4 (100.0)	2.703	0.440
13-24	8 (72.7)	3 (27.3)	11 (100.0)		
25-36	12 (60.0)	8 (40.0)	20 (100.0)		
37-48	3 (75.0)	1 (25.0)	4 (100.0)		
<25	11 (73.3)	4 (26.7)	15 (100.0)	9.193	0.661
≥25	16 (66.7)	8 (33.3)	24 (100.0)		
Sex					
Male	14 (66.7)	7 (33.3)	21 (100.0)	0.140	0.708
Female	13 (72.2)	5 (27.8)	18 (100.0)		

was not statistically significant ($P = 0.661$). Similarly, those in extremes of age were more likely to have unilateral retinoblastoma disease, although the difference was not statistically significant ($P = 0.440$). In addition, females were more likely to be brought to our treatment center with unilateral retinoblastoma as compared with males (72.2% vs. 66.7%), but the difference was not statistically significant ($P = 0.708$).

The distribution of first symptoms of eye disease among study participants is shown in Figure 1. The most frequently reported advanced eye symptom leading to referral reported by parents was protruding eye seen in (17, 44.0%) study participants while the least commonly reported first symptom was squint which was noticed in (4, 10.0%) of study participants. White spot in the eye and squint were seen in (5, 13.0%) and (4, 10.0%), respectively.

Table 2 depicts the most advanced clinical signs at diagnosis. With respect to visual acuity (VA) per eye ($n = 78$), 18 right eyes (18, 46.2%) presented with no perception of light (NPL) and were irreversibly blind as a consequence of advanced retinoblastoma, while a smaller proportion of right eyes (14, 36%) presented with VA of 6/12 or better. A larger proportion of left eyes (29, 74.4%) presented with VA of NPL and fewer left eyes (5, 12.8%) presented with VA of 6/12 or better. As regard, best-corrected visual acuity (BCVA) of study participants at presentation (VA of child; $n = 39$),^[25] nearly half of the study participants (19, 48.7%) did not have visual impairment and their BCVA-in the better eye, was better than or equal to 6/12. However, 20 (51.3%) of the study participants had either mild, moderate, or severe visual impairment with BCVA worse than 6/12–6/120 (3/60). Nearly a fifth 8 (20.5%) of the study population had irreversible visual loss and BCVA of worse than 6/120 (3/60) to NPL.

Proptosis was the most advanced eye sign at diagnosis seen in (18, 46.2%), while leukocoria was the most advanced eye sign seen in a few study participants (2, 5.1%). Most patients presented with signs of overt advanced retinoblastoma, including red eye, proptosis, and buphthalmos (28, 71.8%).

While the clinical stage of retinoblastoma was evaluated per eye, the total number of eyes being 78, there was no tumor found in (18, 46.2%) of right eyes and (8, 20.5%) of left eyes and one left eye presented with phthisis bulbi on account of

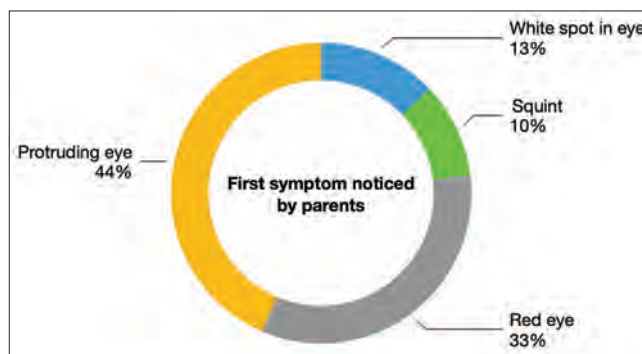


Figure 1: First eye symptom noticed by parents of study participants, $n = 39$

regressed retinoblastoma. Out of the 78 eyes in the index study, (51, 65.3%) had different stages of retinoblastoma. Of the 51 eyes with retinoblastoma, (46, 90.2%) presented with orbital (extraocular) or metastatic retinoblastoma and (5, 9.8%) of the 51, presented with intraocular disease. The classification systems used in the management of study participants is shown in Table 3. The ICRB classification system was most commonly used (27, 69.2%) and the IIRC classification system was used once (1, 2.6%). In addition, Table 4 shows the IRSS classification of eyes studied. A total of (46, 90.2%) eyes presented at IRSS stages II to IV with more than 50% of the 51 eyes with retinoblastoma at IRSS stage II. Nearly one fifth of eyes (10, 19.6%) presented with regional extension of retinoblastoma at IRSS Stage III and (8, 15.6%) eyes had overt orbital disease with evidence of metastatic retinoblastoma (IRSS stage IV) at first presentation.

Figure 2 shows the distribution of the duration of symptoms among study participants. Most patients were brought when symptoms of the disease had been present for 12 months or less (31, 79.5%).

DISCUSSION

Demographic information

While the expected number of retinoblastoma cases in our region is essentially unknown, the picture of this cancer in Nigeria

Table 2: Most advanced clinical signs at diagnosis

Sign	Frequency (n=39; 100.0%), n (%)
VA right eye	
≥6/12	14 (36)
<6/12-6/60	6 (15.3)
<6/60≤LP	1 (2.5)
NLP	18 (46.2)
Total	39 (100.0)
VA left eye	
≥6/12	5 (12.8)
<6/12-6/60	4 (10.3)
<6/60≤LP	1 (2.5)
NLP	29 (74.4)
Total	39 (100.0)
BCVA per participant	
≥6/12	19 (48.7)
<6/12-6/60	10 (25.6)
<6/60≤LP	2 (5.1)
NLP	8 (20.5)
Total	39 (100.0)
Advanced eye sign at diagnosis	
Leukocoria	2 (5.1)
Squint	9 (23.1)
Red eye	5 (12.8)
Proptosis	18 (46.2)
Buphthalmos	5 (12.8)
Total	39 (100.0)

BCVA is by patient, n=39. VA: Visual acuity, NLP: No light perception, LP: Light perception, BCVA: Best corrected visual acuity

Table 3: Classification system used in the diagnosis of retinoblastoma

Retinoblastoma classification used	Frequency (n=39; 100.0), n (%)
ICRB	27 (69.2)
IIRC	1 (2.6)
cTNMH	11 (28.2)
Total	39 (100.0)

ICRB: Intraocular retinoblastoma, IIRC: International intraocular retinoblastoma, cTNMH: American Joint Committee on Cancer classification, according to tumour (T) site, lymph nodes (N), presence of systemic metastasis (M), and hereditary (H) component, c for clinical

Table 4: International retinoblastoma staging system among study participants, (n=51) eyes

Staging at diagnosis	Number (n=51; 100.0%), n (%)
Stage 0	1 (2.0)
Stage I	4 (7.8)
Stage II	28 (55.0)
Stage III	10 (19.6)
Stage IV	8 (15.6)
Total	51 (100.0)

and sub-Saharan Africa largely remains a bleak one with late presentation appearing to be what the clinician sees in hospital

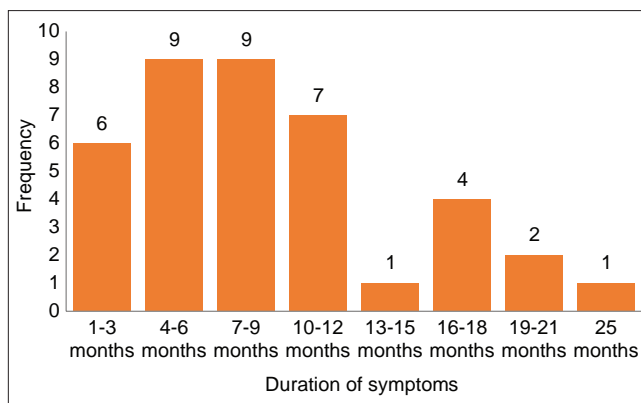


Figure 2: Bar chart of the duration of symptoms

settings.^[5,8,9,14,23] The mean ages in a number of studies in the region have been comparable. In the index study, it is slightly lower than reports from Onitsha, South-Eastern Nigeria,^[9] where an age range of five months to six years was seen with a median age of 2.4 years (28 months) and slightly higher than 24.4 ± 11.4 months from the Lagos^[8] study. In an earlier study in Calabar,^[23] a mean age of 33.68 ± 12.27 months (range 6–55 months) was given. On the other hand, the mean age in a multi-center sub-Saharan Africa study in the Republic of Côte d’Ivoire and the Democratic Republic of the Congo^[5] was higher at three years, while the median age of a study in Egypt^[25] was 24 months (age range two months to 49 months). Mean age reflects age at presentation and patients in the USA present earlier with a mean age of 18 months in unilateral disease.^[14,21]

The slight male preponderance and male to female ratio of 1.3-1.0 is somewhat comparable to what was reported earlier in Calabar,^[23] where there were 15 males and 13 females. This trend is slightly reversed in the study from Onitsha,^[9] with (45.2%) males and (58.8%) females, and Lagos^[8] with 18 males and 23 females and a male to female ratio of 1:1.3. The Republic of Côte d’Ivoire and the Democratic Republic of the Congo^[5] study reported a male: female ratio of 1.07:1.0 (60 males and 56 females). Although, reasons for these differences are not clear, cultural issues along with other demographic factors may contribute to health-seeking behavior patterns, with respect to gender preponderance. Evidence suggests that females are not equitably covered and may be less frequently taken to treatment centers (including retinoblastoma treatment centers) in Nigeria.^[26]

Clinical features

Laterality

The index study reports that most participants had unilateral disease (27, 69.2%) while (12, 30.8%) presented with bilateral disease [Table 1 and Photograph 1]. In comparison, a Lagos study^[8] and an Onitsha^[9] study had a picture similar to the index study with (28, 68.3%) with unilateral, (13, 31.7%) bilateral and (24, 77.4%) unilateral, (7, 22.6%) bilateral retinoblastoma respectively. Globally, unilateral retinoblastoma is nearly twice as common as bilateral disease.^[1,2,11] However, the Alexandria study^[25] reports a marginal difference in laterality

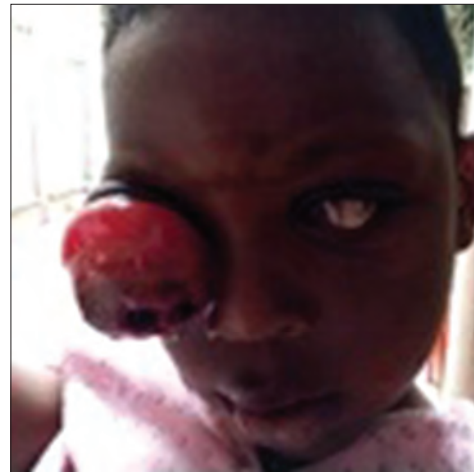as 54% participants presented with bilateral retinoblastoma and an earlier Calabar^[23] study reported (25, 89.3%) unilateral cases and (3, 10.7%) bilateral cases over a six-year period. The earlier Calabar study is at variance with what was encountered in the index study. The reason for this contrast is unclear and population-based studies may unmask the true presentation as regards laterality of retinoblastoma in our region. It is noteworthy that in the index study, the relationship between laterality and age at presentation did not reflect the usual pattern where bilateral retinoblastoma presents earlier in younger children.^[2,11] Younger children and those in the upper extreme of age range encountered were more likely to be brought with unilateral retinoblastoma in our treatment center. However, the difference was statistically insignificant [Table 1]. A similar picture was seen with respect to laterality and sex, where females were more likely to present with unilateral retinoblastoma but this difference was again not statistically significant ($P = 0.708$). It should be noted that time of presentation to treatment center does not always equate duration of symptoms. Research into factors that cause a delay in diagnosis in our region will throw more light in this regard.

Leukocoria

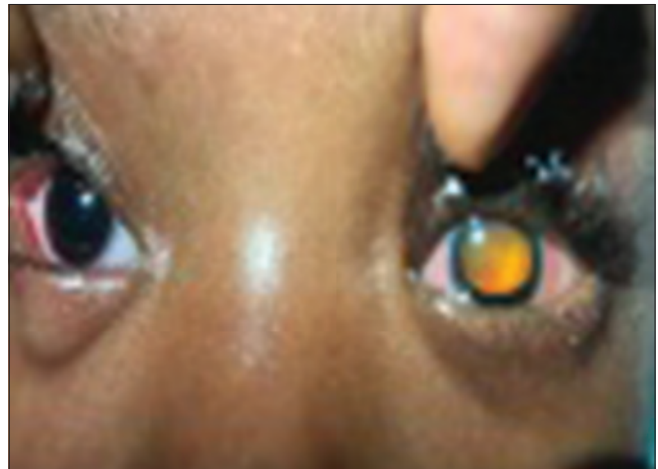While retinoblastoma symptoms may not exist in isolation of each other, a small number of parents of study participants (5, 13.0%) mentioned leukocoria as a first symptom necessitating a referral [Figure 1]. Leukocoria is probably the most common symptom of early retinoblastoma [Photograph 2].^[27] It was the most common first symptom reported in some studies in this region. In Onitsha,^[9] it was encountered in (23, 60.5%) participants, Lagos^[8] reports (32, 59.2%) and the Republic of Côte d'Ivoire and the Democratic Republic of the Congo,^[5] (82, 72%). Leukocoria is an obvious symptom; therefore, the fiat for advocacy for early case finding of retinoblastoma at the level of primary health care is well placed. However, in the index study, it infrequently was the reason parents thought something was wrong with their child's eye. Again, leukocoria was the least frequent advanced eye sign of retinoblastoma at diagnosis in the index study (2, 5.1%), implying that patients more frequently presented with advanced retinoblastoma [Table 2].

Proptosis

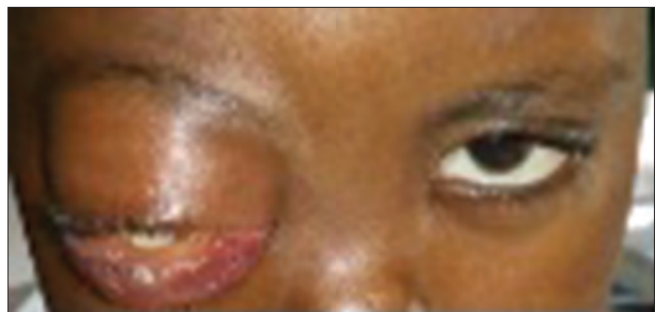Protrusion of the eye ball was encountered as a symptom in a disturbing proportion of patients presenting for the first time in the index study [Photograph 3]. A large proportion of study participants (17, 44.0%) identified protrusion of the eye as the first symptom necessitating referral to hospital [Figure 1]. Proptosis was the most advanced eye sign of retinoblastoma at diagnosis in (18, 46.2%) patients recruited for the index study [Table 2]. As a result of late presentation, extraocular extension of retinoblastoma and proptosis has been the dominant mode of presentation to retinoblastoma centres in Nigeria.^[8,9,13,14] It can be said that a persisting lack of awareness of eye disease in childhood and retinoblastoma^[14] particularly, may contribute to this occurrence. In the index study, about two third (28, 71.8%) of the participants had orbital (extraocular) or metastatic retinoblastoma. Retinoblastoma therefore may



Photograph 1: Bilateral retinoblastoma (neglected disease with right fungating mass)



Photograph 2: Left leukocoria and red eye in advanced unilateral retinoblastoma



Photograph 3: Right proptosis (orbital metastasis) in neglected unilateral retinoblastoma

benefit from targeted public health interventions in this region. Proptosis is a rare finding in patients with retinoblastoma in the developed world.^[10,24]

Red eye

This has been described as an infrequent symptom of retinoblastoma in resource limited settings.^[27,28] A red eye was the

first eye symptom necessitating referral in some participants (13, 33.0%) and the most advanced eye sign in (5, 12.8%) of patients reviewed for the index study [Figure 1 and Table 2, respectively]. This symptom was seen in (3, 5.6%) of the Lagos^[8] study population, and (3, 7.9%) of the Onitsha^[9] study with no mention of a red eye in some published work.^[5,25] Similarly, a squint was reported as a symptom in (21, 53.8%) of the index study population. This symptom though reported, appears less frequently in this region.^[5,8,23]

Presenting visual acuity

A total of (14, 35.9%) right eyes and (5, 12.8%) left eyes had VA of 6/12 or better. Twenty-five, (64%) right eyes had VA of $\leq 6/12$, (19, 76.0%) of which had no potential for vision and of the (34, 87.0%) left eyes that presented with VA of $\leq 6/12$, (29, 85.0%) had NLP at presentation and no visual potential. The frequency of patients with BCVA of 6/12 or better in our study [Table 3] was (19, 48.7%). More than half of the index study participants had visual impairment with BCVA of 6/18 or worse and 8 (20.5%) of study participants presenting with BCVA of $< 6/120$ (3/60) to NLP.

Age-appropriate vision screening in young children is a useful tool for vision-threatening pediatric disorders including retinoblastoma.^[29] However, this requires specialist training which is not readily available in resource-limited settings. This notwithstanding, the eye screening capability of existing primary health-care workers can be expanded to include screening for retinoblastoma by a cost effective and easy to use method employing the use of the Arlight^R Ophthalmoscope device. Primary health workers can be easily trained to use this device in a reliable manner to perform the red reflex test. An unusual red reflex or the presence of strabismus in very young children are clinical features of vision threatening pediatric eye disease including cataract and retinoblastoma that can be detected by primary health care workers including community health workers, early in the course of the disease.^[30] Early detection through targeted screening will facilitate early treatment interventions and improve survival of children with retinoblastoma.

Clinical staging of retinoblastoma

In our study, of the 78 eyes studied, 51 had retinoblastoma at presentation. A total of 5 eyes had early onset retinoblastoma (evidenced by small solitary intraretinal tumor < 5 mm in diameter), 3 of which were incidental findings in participants with bilateral retinoblastoma. A patient with bilateral retinoblastoma at presentation also had left phthisis bulbi consequent to regressed retinoblastoma. IRSS stages II to IV were encountered in a large number of the 51 eyes with retinoblastoma (46, 90.2%), while an unsettling proportion of eyes with advanced retinoblastoma (8, 15.6%) also had associated metastatic disease at first presentation. This is presented in Table 4.

While there appears to be some controversy on the classification system for the most advanced presentation of retinoblastoma,^[19] in the index study, patients' hospital records did not have

uniform staging. Although retinoblastoma staging was not highlighted in other work,^[8,9] in the earlier Calabar^[23] study, all patients seen were classified using the ICRB classification system and of the 28 children with retinoblastoma in that study, (22, 78.6%) had retrolaminar invasion and by extension, extraocular retinoblastoma.

Lag time

This has been defined under three categories:^[24,28]

Lag 1: The time from the recognition of symptoms to the initial consultation with a physician (delay in the initial visit).

Lag 2: The time from the initial consultation to the diagnosis of retinoblastoma (delay in diagnosis).

Lag 3: The time from diagnosis to primary treatment (delay in treatment). For the purpose of the index study, lag time is defined as the interval from the date of the initial notice of reported symptoms of retinoblastoma and the date of retinoblastoma diagnosis. The mean lag time in the index study was 9.13 ± 5.68 , the median being 8 months. This is longer what was reported earlier in Calabar,^[23] where the mean duration of symptoms at presentation was 7.07 ± 4.29 months. Nearly two thirds of participants (25, 64.1%) presented with a duration of symptoms of four months to 12 months, while more than half of the study participants (24, 61.5%) presented with a symptom duration of \geq seven months [Figure 2]. High risk features were seen in 23 of those with lag time \geq seven months. In comparison, a Chinese study^[28] observed 8 of the 138 children included in their single centre study had an overall lag time (including delay to treatment) of more than a year with only 4 children having HHRF. In Argentina,^[18] 75 of their 95 patients had a lag time of < 24 weeks (six months). In comparison, in our study, a smaller proportion of patients (15, 38.5%) had a symptom history of six months or less and (6, 15.4%) were diagnosed with a symptom duration of three months or less [Figure 2]. Research into the factors that are responsible for increased lag time in our setting may give reasons for these findings.

Limitations

The limitations of the study include its retrospective nature and the relatively small study population. In addition to these is the lack of detailed documentation of high-risk histopathological features. A larger, prospective, multicenter prospective study may answer these questions. In spite of these limitations, the index study highlights that, late presentation is still the bane of our health services. Clinical outcome can be improved if this trend is reversed.

Recommendations

We recommend the urgent introduction of retinoblastoma screening into the existing routine well baby and child assessment service at the primary health care level. Aggressive primary eye care information and health education about child eye health and the early detection of retinoblastoma, in particular, should be continuously disseminated to all stakeholders in eye care and child health services through the

media in a sustainable manner. These can be done at state and national levels in Nigeria.

CONCLUSIONS

Retinoblastoma is seen at the CCEC. Although the most frequent first symptom reportedly noticed by parents necessitating referral was protruding eye, the lag time was often several months long and there was an unacceptably high frequency of late presentation with advanced ocular retinoblastoma and or extraocular retinoblastoma disease presenting to our tertiary eye center in Nigeria.

Financial support and sponsorship

Nil.

Conflicts of interest

There are no conflicts of interest.

REFERENCES

- Global Retinoblastoma Study Group; Fabian ID, Abdallah E, Abdullahi SU, Abdulqader RA, Adamou Boubacar S, *et al.* Global retinoblastoma presentation and analysis by national income level. *JAMA Oncol* 2020;6:685-95.
- Kivelä T. The epidemiological challenge of the most frequent eye cancer: Retinoblastoma, an issue of birth and death. *Br J Ophthalmol* 2009;93:1129-31.
- Tijani SO, Elesha SO, Banjo AA. Morphological patterns of paediatric solid cancer in Lagos, Nigeria. *West Afr J Med* 1995;14:174-80.
- Akang EE. Tumors of childhood in Ibadan, Nigeria (1973-1990). *Pediatr Pathol Lab Med* 1996;16:791-800.
- Lukamba RM, Yao JA, Kabesha TA, Budiongo AN, Monga BB, Mwembo AT, *et al.* Retinoblastoma in Sub-Saharan Africa: Case studies of the republic of côte d'ivoire and the democratic republic of the Congo. *J Glob Oncol* 2018;4:1-8.
- Agboola AO, Adekanmbi FA, Musa AA, Sotimehin AS, Deji-Agboola AM, Shonubi AM, *et al.* Pattern of childhood malignant tumours in a teaching hospital in South-Western Nigeria. *Med J Aust* 2009;190:12-4.
- Chuka-Okosa CM, Uche NJ, Kizor-Akaraiwe NN. Orbito-ocular neoplasms in Enugu, South-Eastern, Nigeria. *West Afr J Med* 2008;27:144-7.
- Musa KO, Aribaba OT, Oluleye TS, Olowoyeye AO, Akinsete AM. Challenges of retinoblastoma management in a Nigerian tertiary eye care facility. *J Clin Sci* 2017;14:182-7.
- Nwosu SN, Okpala NE, Nnubia CA, Akudinobi CU. Retinoblastoma in Onitsha, Nigeria. *Niger J Ophthalmol* 2019;27:8-11.
- Dimaras H, Kimani K, Dimba EA, Gronsdahl P, White A, Chan HS, *et al.* Retinoblastoma. *Lancet* 2012;379:1436-46.
- Fabian ID, Sagoo MS. Understanding retinoblastoma: Epidemiology and genetics. *Community Eye Health* 2018;31:7.
- Miranda GA, Simanjuntak GW. Clinical findings and demography of retinoblastoma in a tertiary hospital in a remote area in a developing country. *Asian Pac J Cancer Care* 2018;3:37-41.
- Kodilinye HC. Retinoblastoma in Nigeria: Problems of treatment. *Am J Ophthalmol* 1967;63:469-81.
- Ademola-Popoola DS, Opocher E, Reddy MA. Contemporary management of retinoblastoma in the context of a low-resource country. *Niger Postgrad Med J* 2019;26:69-79.
- Melamud A, Palekar R, Singh A. Retinoblastoma. *Am Fam Physician* 2006;73:1039-44.
- Knudson AG Jr. Mutation and cancer: Statistical study of retinoblastoma. *Proc Natl Acad Sci U S A* 1971;68:820-3.
- Grossniklaus HE. Retinoblastoma. Fifty years of progress. The LXXI Edward Jackson Memorial Lecture. *Am J Ophthalmol* 2014;158:875-91.
- Chantada G, Fandiño A, Manzitti J, Urrutia L, Schwartzman E. Late diagnosis of retinoblastoma in a developing country. *Arch Dis Child* 1999;80:171-4.
- Ali AA, Elsheikh SM, Elhaj A, Osman N, Abuidris D, Eltayeb EA, *et al.* Clinical presentation and outcome of retinoblastoma among children treated at the National Cancer Institute (NCI) in Gezira, Sudan: A single Institution experience. *Ophthalmic Genet* 2011;32:122-5.
- Gupta AK, Meena JP. A narrative review of retinoblastoma and recent advances in its management. *Pediatr Med* 2020;3:20.
- Fabian ID, Reddy A, Sagoo MS. Classification and staging of retinoblastoma. *Community Eye Health* 2018;31:11-3.
- Gupta R, Vemuganti GK, Reddy VA, Honavar SG. Histopathologic risk factors in retinoblastoma in India. *Arch Pathol Lab Med* 2009;133:1210-4.
- Duke RE, Mudhar H, Okokon E. Histopathologic risk factors for metastasis in retinoblastoma seen in a tertiary eye centre in south, south Nigeria. *Arch Clin Exp Surg* 2015;4:83-8.
- Posner M, Jaulim A, Vasalaki M, Rantell K, Sagoo MS, Reddy MA. Lag time for retinoblastoma in the UK revisited: A retrospective analysis. *BMJ Open* 2017;7:e015625.
- Soliman SE, Eldomiaty W, Goweida MB, Dowidar A. Clinical presentation of retinoblastoma in Alexandria: A step toward earlier diagnosis. *Saudi J Ophthalmol* 2017;31:80-5.
- Mganga H, Lewallen S, Courtright P. Overcoming gender inequity in prevention of blindness and visual impairment in Africa. *Middle East Afr J Ophthalmol* 2011;18:98-101.
- Parulekar MV. Detecting retinoblastoma. *Community Eye Health* 2018;31:10.
- Xiao W, Ye H, Zeng H, Tang L, Chen R, Gao Y, *et al.* Associations among socioeconomic factors, lag time, and high-risk histopathologic features in eyes primarily enucleated for retinoblastoma. *Curr Eye Res* 2019;44:1144-9.
- Levenson JH, Kozarsky A. Visual acuity. In: Walker HK, Hall WD, Hurst JW, editors. *Clinical Methods: The History, Physical, and Laboratory Examinations*. 3rd ed., Ch. 115. Boston: Butterworths; 1990. Available from: <https://www.ncbi.nlm.nih.gov/books/NBK219/>. [Last accessed on 2021 Oct 22].
- Bowman R, Foster A. Testing the red reflex. *Community Eye Health* 2018;31:23.