

## PAEDIATRIC NASAL FOREIGN BODY IN CALABAR: A REVIEW OF 5-YEARS EXPERIENCE.

<sup>1</sup>Francis P.M, <sup>1</sup>Adekanye A.G, <sup>1</sup>Mgbe R.B, <sup>1</sup>Offiong M.E, <sup>2</sup>Enyuma C.O.A,

<sup>1</sup>Department of Otorhinolaryngology, University of Calabar Teaching Hospital, Calabar

<sup>2</sup>Department of Paediatrics, University of Calabar Teaching Hospital, Calabar.

### ABSTRACT

**BACKGROUND:** Nasal foreign bodies are common domestic accidents in children. They can constitute a great challenge and management may require great skill. However, seldom does the Otolaryngologist keep track of the number and kinds of the foreign bodies he encounters.

**OBJECTIVE:** To evaluate cases of nasal foreign bodies among children managed in Otorhinolaryngology Department of the University of Calabar Teaching Hospital, Nigeria.

**MATERIALS AND METHODS:** A retrospective study of 215 Cases of paediatric nasal foreign bodies seen and managed in the Otorhinolaryngology Department of the University of Calabar Teaching Hospital from January 2015 to December 2018. Maximum age was 14years. The case notes of all children diagnosed with nasal foreign bodies within the period under review, from ENT Clinic, Ward and Children emergency Room were reviewed as related to age, gender, and type of foreign bodies, category of doctors, methods of removal and complications. Data were analysed and presented in descriptive, tabular and chart forms.

**RESULTS:** Of the 215 children, **43.7%** were males and **56.3%** females. The age range was **0 – 14** years, with a male: female ratio of **1:1.35**. The peak age range at which nasal foreign bodies were found was **0–4** years (87%) and the least frequent age bracket was **10–14** years (1.4%). Most of the children were asymptomatic (60%), and others had unilateral foul-smelling nasal discharge (40%). The most common foreign body were **beads** (34.9%), followed by seeds (23.2%). Most presentations were within one day (90%), followed by one week (7%). Most foreign bodies (59.5%) were inserted into the right nostril, and 40.5% into the left. No bilateral insertion was observed. Most of the foreign bodies (80%) were mechanically extracted with Jobson–Horne's probes without general anaesthesia. Mainly Registrars did most removals 65% while 25% were by Senior Registrars. Mild epistaxis was a complication in 5% of cases.

**CONCLUSION:** Nasal foreign bodies are common in Calabar. The most frequently observed foreign bodies were beads and seeds. Therefore, public health education is needed for parents and caregivers.

**KEYWORDS:** Paediatrics, Nose, foreign bodies.

NigerJmed 2020: 20-23  
© 2020. Nigerian Journal of Medicine

### INTRODUCTION

Nasal foreign bodies are common accidents in children<sup>1,2</sup>. The first year of a child's life represents a phase of exploration and interaction with the environment. This process leads to the placement of objects in orifices<sup>3</sup>. Children often play with objects like toys, hair accessories, household materials or other things in their environments. The parental attitudes, lack of attention, and allowing small objects at the disposal of young children contribute to high incidence of nasal foreign bodies. Nasal foreign bodies may be organic or inorganic<sup>4</sup>. The inorganic is usually inert and asymptomatic while the organic elicits inflammatory reactions from the nasal mucosa leading to nasal discharge<sup>4,5</sup>.

Most nasal foreign bodies are found in the anterior portion of the nasal cavities between the inferior turbinate and septum or near the floor of the nasal fossa. Nasal foreign

bodies may enter the nose through the anterior nares, or posterior choanae during forceful vomiting or eating and coughing at the same time, also during regurgitation of food from the oropharynx and digital manoeuvres for foreign body removal from the oropharynx.<sup>6</sup> Similarly, penetrating injury can be a contributing factor<sup>7</sup>.

Nasal foreign bodies are characterized by early onset of nasal discharge, which becomes purulent and offensive after a few days<sup>1,2</sup>. Also, nasal obstruction and epistaxis may occur. It is a classical axiom that unilateral foul-smelling nasal discharge in children is highly suggestive of nasal foreign bodies<sup>8,9</sup>. The treatment is the removal of the foreign body without trauma to the nose.

The method of removal depends on the type, size, shape and the position of foreign body and cooperation of the patient<sup>10</sup>. In experienced hands, the ideal position for foreign body removal is to have the patient sit on the mother's lap, who will hold the child's arm and legs, while an assistant holds the head, which should be mildly extended (about 30°) position. Overtime, various methods of foreign body removal deployed by Otolaryngologist and non-Otolaryngologist have been reported<sup>7</sup>. These include positive pressure methods, parents kiss, Ambu bag, irrigation method<sup>8, 11-13</sup>. Other documented methods include the use of surgical forceps<sup>13</sup> for objects like papers, foams, plastics, pebbles, stones, erasers and disc batteries. etc.

#### Correspondence to:

Dr Adekanye Abiola Grace  
Department of Otorhinolaryngology,  
University of Calabar Teaching Hospital, Calabar.  
Email:abiolaadekanye@yahoo.com  
Phone:+2348050543605

Button battery foreign bodies in the nose are typically associated with early complications and must be treated as emergency<sup>15-16</sup>. This is because they may result in nasal septal perforations, synechiae and stenosis of the nasal cavity<sup>17</sup>. The currents they generated predispose to tissue injury following leakage.

**AIM:** To determine the types of nasal foreign bodies among children in Calabar.

**OBJECTIVES:**

To assess types of nasal foreign bodies among children managed at Otorhinolaryngology Department of University of Calabar Teaching Hospital, Calabar.

To assess techniques of nasal foreign bodies removal.

**MATERIALS AND METHODS:** This was a retrospective

study of 215 paediatric patients with nasal foreign bodies seen and treated in the Otorhinolaryngology Department (ORL) of the University of Calabar Teaching Hospital between January 2015 and December 2018. Case notes of these patients were retrieved and reviewed for demographic data, clinical diagnosis, site of foreign body, type of foreign body, category of attending doctors, the mode of treatment and complications were recorded for all the patients. The data were analysed with descriptive statistics and presented in descriptive, tabular and chart forms.

**RESULTS:** A total of 215 children seen and treated for nasal foreign bodies, 94 (43.7%) were males, and 121 (56.3%) were females. Male/female ratio was 1: 1.4. The majority of children, 87%, were under 5 years of age. In 59.5% of the cases the foreign body was in the right nasal cavity; 40.5% in the left nasal cavity and none in both cavities. (Table1).

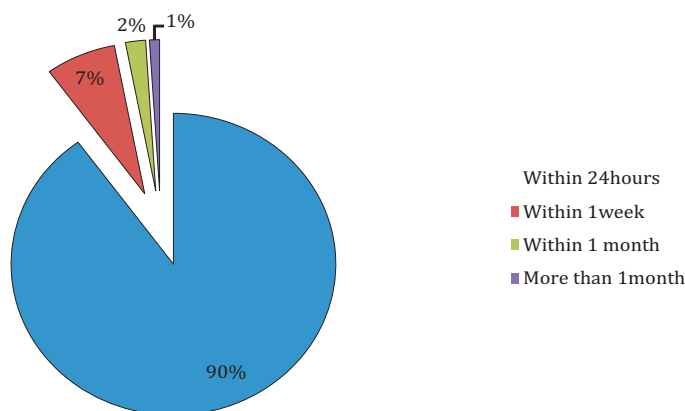
**Table1. Age and Sex of children with locations of nasal foreign bodies**

AGE	NO.	MALE	FEMALE	Rt nasal cavity	Lt nasal cavity
. . .	187	80	107	105	82
5 – 9	25	11	14	21	4
10 – 14	3	3	-	2	1
<b>TOTAL</b>	<b>215</b>	<b>94</b>	<b>121</b>	<b>128</b>	<b>87</b>

**Table2. Types of Foreign Body Recovered**

Material	Number	Percentage
1.Bead	75	34.9%
2.seed	50	23.2%
3.Stone	21	9.8%
4.Eraser	20	9.3%
5.Paper	15	6.9%
6.Plastics & Foam	14	6.5%
7.Chalk	10	4.7%
8.Disc battery	5	2.3%
9.Pebble	4	1.9%
10.Screw nail	1	0.5%
<b>TOTAL</b>	<b>215</b>	<b>100%</b>

The most common foreign bodies were beads of different colours and sizes (34.9%). Thereafter, seeds 23.2%, stones 9.8% and erasers 9.3% formed the bulk of the foreign bodies. Others were papers 6.9%, plastics and foam 6.5% etc.



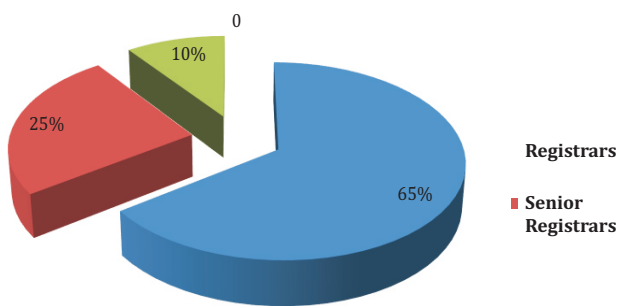
**Fig1. Duration before presentation**

Of the patients, 90% were seen within 24hours of the incidence and 7% within one week. Yet others waited for up to one month (2%) and more (1%). (Fig1).

**Table 3. Techniques of Foreign Body Removal**

Types of Techniques		No.	%
Direct instrumentation	Extraction		
	Jobson - Horne's Probes	172	80
	Nasal Forceps	39	18
	Suction	4	2
Others	Posterior Displacement		Not required
	Ambu bag		Not required
	Parental Kissing etc.		Not required

The majority of the nasal foreign bodies were removed using Jobson - Horne's probes (80%). This was followed by the use of nasal forceps (18%), as shown in Table 3. No general anaesthesia used. No deaths or prolonged morbidity seen.



**Fig2. Category of attending Doctors who removed nasal foreign bodies**  
The removal of the foreign bodies was by Registrars in ORL 65%, Senior Registrars 25% and consultant Otorhinolaryngologists 10%. Fig2.

**DISCUSSION:** Nasal foreign bodies are common domestic accidents in children in Calabar. This is similar to report in literatures<sup>1-2</sup>. In our series, most of our patients were in the age bracket 0 - 4 years (87%), as observed in other studies<sup>4,5,18</sup>.

In our series, female preponderance was observed as reported in many other studies<sup>4,5,7,19</sup>. This is in contrast to studies done by Ngo et al<sup>20</sup>, and Tong et al<sup>21</sup> where males predominated. Beads were the most common foreign bodies seen in our study. This is similar to other findings<sup>6,20</sup>. Beads are common in our environment. They are used to decorate hairs of female children in different styles and colours alongside rubber bands of different colours. In addition, they are used as religious (catholic rosaries) and cultural symbols. Ogunleye et al<sup>18</sup>, in their study, found seeds 34 (32.1%) to be the commonest foreign body. We observed seeds in 50 (32.2%) cases second to beads. In the Mangussi-Gomes et al<sup>22</sup> studies, beans were ranked highest among all the foreign body types in the nasal cavity. In addition, others have reported papers, safety pins, chalks<sup>23</sup> etc.

Button batteries were a common nasal foreign bodies accounting for 5 (2.3%) in our study. When it occurs, they are dangerous because of their ability to cause liquefaction necrosis on contact with moist tissue. Therefore, prompt identification and removal is recommended<sup>24</sup>.

Nasal foreign body in our study were all unilateral, right more than left. No foreign body was reported bilaterally. The right to left ratio of 1.47:1 is similar to R: L 1.46:1 by Ogunleye et al<sup>18</sup>. This could be explained by the predominance of Right handedness in our society. Furthermore, asymptomatic presentation and unilateral foul-smelling rhinorrhoea were the leading symptoms in our study. This is similar to the study of Tiago et al<sup>25</sup> and Srinivas et al<sup>26</sup> but in contrast to other reports in literature<sup>7,20</sup>.

No available complication of button battery documented for the 2.3% cases observed in our series. However, button batteries are emergencies, because of the low- voltage electrical currents, electrolysis-induced release of sodium hydroxide and chlorine gas. If their alkaline contents leak they could also induce liquefactive tissue necrosis, hence the need for prompt removal<sup>14,15,23</sup>.

In this study, most (90%) of the patients presented within 24-hours and had their foreign bodies removed. Similarly, this was reported by Okoye et al<sup>27</sup>, where 119 (88.81%) out of 134 patients presented within the first day with only 15 (11.19%) presenting late.

All the foreign bodies in our series were removed by direct instrumentation, with Jobson-Horne's probe used in 80% of cases, Tilley's nasal forceps in 18% and suction in 2%. This is because the type, nature, shape and accessibility of the foreign body, among others were duly considered before the choice of instruments as similarly used<sup>20</sup>. Other techniques such as posterior displacement, Ambu bag, parental kissing or irrigation were not required. Also, general anaesthesia was not used to facilitate removal. This is similarly reported in other study<sup>7</sup>. However, in the same geopolitical zone, Okoye et al<sup>27</sup> reported that 6 (4.48%) cases out of 134 required general anaesthesia. Mostly junior and senior residents removed most of the nasal foreign bodies in Calabar. This is in contrast to the study of Afolabi et al<sup>28</sup> where senior Registrars and Consultants removed most of the foreign bodies. The complications that may occur following insertion of foreign body in the nose are related to the time elapsed before removal, unskilled attempted removal as well as the size and shape of the foreign body<sup>9,14</sup>. However, unsuccessful attempts at removal may cause bleeding, pain or local injury, hindering further attempts<sup>8</sup> and dislodgement into the larynx or lower airway or oesophagus. In our study, mild epistaxis as a complication was seen in 5% of cases following removal of 215 nasal

foreign bodies. This is in contrast to the study of Nwosu et al<sup>7</sup> where no complications were recorded in a total of 27 cases.

A number of factors have been associated with the success of foreign body removal. These are the duration of foreign body residence, its characteristics (shape, size and texture), patient co-operation, trauma to the nasal cavity, ability to visualize it and surrounding structures, available equipment and the skill of the attending physician<sup>1</sup>. Therefore, with proper training, instrumentation and adoption of published guidelines<sup>4,8</sup> on nasal foreign body removal, most nasal foreign bodies can be removed with ease.

#### CONCLUSION:

Nasal foreign bodies are common emergencies in paediatrics Otorhinolaryngology. Beads are the commonest nasal foreign body and presentation is mostly asymptomatic. The peak age of presentation (0-4 years) cannot properly express themselves, and the object may pass unnoticed hence diagnosis and removal delayed. Management is easy and uneventful in early presentation and when the removal has not been attempted before the presentation.

#### RECOMMENDATION:

Objects small enough that can enter the nose of children should be kept out of their reach in the homes, schools and play arenas. We advocate the use of beads in hairdressing should be avoided in children under five years of age. The classical axiom that a unilateral foul-smelling nasal discharge in a child is pathognomonic of the nasal foreign body until proven otherwise must be kept in mind by parents, caregivers and health professional. Unskilled persons should avoid attempted removal.

**Financial support and sponsorship:** Nil.

**Conflicts of interest:** There are no conflicts of interest.

**Acknowledgement:** We appreciate all nurses and medical record officers.

#### REFERENCES:

1. Botma M, Bader R, Kubba H. 'A parent's kiss': evaluating an unusual method for removing nasal foreign body in children. *J Laryngol Otol* 2000; 114:598 - 600.
2. Kadish HA, Corneli HM. Removal of nasal foreign bodies in the paediatric population. *Am J Emerg Med* 1997; 15: 54-6.
3. Rodriguez H, Passali GC, Gregori D, Chinski A, Tiscomia C, Botto H, Nieto M, Zanetta A, Passali D, Cuestas G. *Int J pediatr Otorhinolaryngol*. 14 (76 Suppl. 1) (2012) 84-91.
4. Roland NJ, McRae RDR, McCombe AW. *Key Topics in Otolaryngology and Head and Neck Surgery*. 3<sup>rd</sup> ed. Oxford: BIOS Scientific Publishers, 2005: 104.
5. Cohen HA, Goldberg E, Horev Z. Removal of nasal foreign bodies in children. *Clin Pediatr (Phila)* 1993; 32:192.
6. Enyuma COA, Offiong M, Adekanye A, Akpan U, Ezeanyagu N, Uffiah O. Foreign body in the nasopharynx: Masquerading as pharyngotonsillitis. *Niger J Med* 2015: 380 - 383.
7. Nwosu JN. Nasal injuries: The place of foreign bodies. *J Health Res Rev* 2016; 3: 107-10.
8. Kiger JR, Brenkert TE, Losek JD. Nasal foreign body removal in children. *Pediatr Emerg Care* 2008; 24 (11): 785-92.
9. Kalan A, Tariq M. Foreign bodies in the nasal cavities: a comprehensive review of the aetiology, diagnostic pointers, and therapeutic measures. *Postgrad Med J* 76: 484-87
10. Baluyot ST. Foreign bodies in the nasal cavity, in Paparella M.M. Shumrick D.A. (Eds.) 2<sup>nd</sup> ed. *Otolaryngology*, vol. 3, WB Saunders WB, Philadelphia, PA, 1980, PP. 2009-2016.
11. Purohit N, Ray S, Wilson T, Chawla OP. The 'parent's kiss': an effective way to remove paediatric nasal foreign bodies. *Ann R Coll Surg Engl* 2008; 90(5)420-22.
12. Finkelstein JA. Oral Ambu-bag insufflations to remove unilateral nasal foreign bodies. *Am J Emerg Med* 1996; 14(1):57-8.
13. Lichenstein R, Giudice EL. Nasal wash technique for nasal body removal. *Pediatr Emerg Care* 2000; 16(1): 59-60.
14. Francois M, Hamrioui R, Narcy P. Nasal foreign bodies in children. *Eur Arch Otorhinolaryngol* 1998; 255(3): 132-4.
15. Hong D, Chu YF, Tong KM, Hsiao CJ. Button batteries as foreign bodies in the nasal cavities. *Int J Pediatr Otorhinolaryngol*. 1987; 14: 15-9.
16. Gomes CC, Sakano E, Lucchezi MC, Porto PR. Button battery as a foreign in the nasal cavities. *Special aspect. Rhinology* 1994; 32: 98-100.
17. McRae D, Premachandra DJ, Gatland DJ. Button batteries in the ear, nose and cervical oesophagus, a destructive foreign body. *J Otolaryngol* 1989; 18: 317-9.
18. Ogunleye AO, Sogebi OA. Nasal foreign bodies in African children. *Afr J Med Sci*. 2004; 33; 225-8.
19. Gregori D, Salemi L, Scarinzi C et al. Foreign bodies in the nose causing complications and requiring hospitalization in children 0 - 4 age: Results from the European survey of foreign bodies' injuries study. *Rhinology* 2008; 46:28-33.
20. Ngo A, Ngo KC, Sim TP. Otorhinolaryngeal foreign bodies in children presenting to the emergency department. *Singapore Med J* 2005; 46(4): 172-8.
21. Tong MC, Ying SY, Van Hasselt CA. Nasal foreign bodies in children. *Int J Pediatr Otorhinolaryngol* 1996; 35: 207-11.
22. Mangussi-Gomes J, Andrade JS, Matos RC, Kosugi EM, Penido Nde O. ENT foreign bodies. Profile of the cases seen in a tertiary hospital emergency care unit. *Braz J Otorhinolaryngol* 2013; 79: 699-703.
23. Guthrie D. Foreign bodies in the nose. *J Laryngol Otol* 1956; 41: 454-7.
24. Capo JM, Lucente FE. Alkaline battery foreign bodies of the ear and nose. *Arch Otolaryngol Head Neck Surg* 1986; 112: 562-3.
25. Tiago RS, Salgado DC, Correa JP, Pio MR, Lambert EE. Foreign body in ear, nose and oropharynx: Experience from a tertiary hospital. *Braz J Otorhinolaryngol* 2006; 72: 177-81.
26. Srinivas Moorthy PN, Srivalli M, Rau GV, Prasanth C. Study on the clinical presentation of ear and nose foreign bodies. *Indian J Otolaryngol Head Neck Surg* 2012; 64: 31-5.
27. Okoye BC, Onotai LO. Foreign bodies in the nose. *Nigerian Journal of Medicine: Journal of the National Association of the Resident Doctors of Nigeria*. 2006; 15(3):301-4.
28. Afolabi OA, Suleiman AO, Aremu SK, Alabi BS, Segun-Busari S, Dunmade AD, Ologe FE. An audit of paediatric nasal foreign bodies in Ilorin, Nigeria. *South African Journal of Child Health* 2009; 3(2): 64.