

Permanent tracheostomy: Its social impacts and their management in Ondo State, Southwest, Nigeria

MI Akenroye, AT Osukoya

Departments of Ear, Nose and Throat-Head and Neck Surgery, State Specialist Hospital, Akure, Ondo State, Nigeria

Abstract

Background: Upper respiratory tract obstruction resulting from bilateral recurrent laryngeal nerve damage is commonly managed with permanent tracheostomy in our environment.

Objective: To evaluate the social impacts of permanent tracheostomy and its management in Ondo State, Southwest Nigeria.

Materials and Methods: Four patients were managed with permanent tracheostomy due to bilateral laryngeal nerve paralysis following thyroidectomy. The observed complications are grouped as surgical/medical and social complications.

Results: Surgical/medical complications include excessive mucus production, 29 (43.2%), stoma infection 18 (26.8%), stoma polyp and soft tissue blockage of tube fenestrations were 10 (15%) each. The observed impacts on patients' social life include: Negative attitude of family members, difficulty with professional use of voice, problems of social integration and scarcity of tracheostomy tube with speaking valves.

Conclusion: Management of social impacts of permanent tracheostomy is more difficult than other complications and family members must be involved in it.

Key words: Negative impact on social life, permanent tracheostomy, surgical complications

Date of Acceptance: 21-May-2012

Introduction

Tracheostomy was introduced into medicine as a means of relieving upper respiratory tract obstruction as early as the second century AD by Galen.^[1] Since then it has been successfully employed not only to relieve upper respiratory tract obstruction but also in many clinical conditions including protection of lower respiratory tract, tracheobronchial toileting and assistance of ventilation especially in prolonged unconsciousness. It is sometimes a much needed pre-operative procedure in major surgeries involving head and neck region where respiration could be compromised.

Tracheostomy could be for a short term, known as temporary tracheostomy, or a life-long measure, known as permanent tracheostomy. In temporary tracheostomy the tube only stays in place from a few days to a few weeks. It ultimately gets removed at the resolution of primary disease or when

the respiratory obstruction resulting from such condition is over. When the tracheostomy tube is removed, closure of the stoma can be spontaneous with the use of air tight dressing or a surgical closure may be employed.

A permanent tracheostomy however remains on the patient for as long as he lives. This is often due to conditions associated with irreversible damage to the laryngeal architecture or injury to both recurrent laryngeal nerves, making the larynx inadequate in its respiratory function. Indications for a permanent tracheostomy include laryngeal paralysis or collapse, radiation therapy of the upper airways or oropharynx, laryngotracheal resections, staged laryngeal reconstruction, nasal neoplasia, or severe secretory respiratory disease.^[2,] Permanent tracheostomy is also

Address for correspondence:

Dr. M. I. Akenroye,
P.O. Box 3861, Akure, Ondo State, Nigeria.
E-mail: manuwaakenroye@yahoo.com

Access this article online

Quick Response Code:



Website: www.njcponline.com

DOI: 10.4103/1119-3077.106751

PMID: *****

commonly performed in a patient with severe obstructive sleep apnea syndrome who cannot tolerate nasal continuous positive airway pressure and has failed other surgical procedures.^[3]

The continued presence of the tracheostomy tube *in situ* constitutes undesirable artificial device both to the cervical tissue and to the patients who wear them.

Both permanent and temporary tracheostomies are associated with many complications,^[4] which include:

- Tube blockage
- Excessive mucus production
- Stoma infection
- Polyp formation around stoma
- Hemorrhage
- Laryngeal stenosis, ugly neck scar etc.

Patients with permanent tracheostomy in our environment (i.e. Southwest Nigeria) face many other social setbacks. These include:

- Family reluctance to accept them e.g. spouses/relatives/siblings
- Problems of adjusting to social environment
- Interference with professional use of voice
- Scarcity of materials for maintenance of tubes
- Our experiences in managing some of these social setbacks are illustrated in the study.

Materials and Methods

There were four patients in this study with ages 65, 50, 43 and 40 years with mean age of 49.5 years. These ages relate to point of entry into the study. These patients were seen over 11 years. All patients were females. Their primary diseases were non-toxic goiter with duration of goiter ranging from 3 to 5 years. Three of the patients had subtotal thyroidectomy and one had total thyroidectomy. None of the patients had the thyroidectomy done in our hospital. They all got into our services by referral from nearby tertiary health institutions where there were no otolaryngologists.

Two of the patients presented at our hospital with stridor and severe upper respiratory obstruction and were treated with tracheostomy. One had tracheostomy done the second day after thyroidectomy due to severe respiratory obstruction. The fourth patient had been living with heavy snoring and moderate respiratory obstruction until she developed upper respiratory tract infection which tilted her over to complete obstruction. Her tracheostomy was done at the point of entry into emergency room because she was cyanosed and virtually unconscious.

Considering the relatively uncommon incidence of bilateral recurrent laryngeal nerve paralysis following thyroidectomy,

we consider four patients being managed by a secondary health care facility such as ours as a significant number. At the time of writing this paper, the patients have worn their tracheostomy tubes for 11 years, 10 years, 7 years and 3 months, respectively. All patients had direct laryngoscopy after tracheostomy to confirm the paralysis of both vocal cords. The time interval between the thyroidectomy and tracheostomy varied from two days post-operation to 2 years post-operation.

Results

The commonest complication was excessive mucus production, 29 (43.2%) [Table 1].

Each surgical complication was promptly treated as it arose. Excessive mucus production usually responded to antihistamines and corticosteroids, stoma infections were treated with antibiotics according to culture and sensitivity results and in virtually all cases, *Staphylococcus aureus* was isolated. Polyps around the stoma as shown in Figure 1 were curetted from time to time and sometimes by application of silver nitrate sticks, soft tissue obstruction of tube fenestration required excision under local anesthesia and regular tube changing.

None of our patients had any episode of bleeding from the stoma except during excision of polyp or soft tissues and this never constituted any problem.

At the time of this report, the first three of our patients have mastered most of the techniques involved in tube changing that they only present to the clinics when there is soft tissue obstruction of tube fenestration as shown in figure 2 or when their tube is so corroded that a change is highly necessary. The fourth is in early stages of polyp formation around the tracheostoma and excessive mucus production necessitating treatment still remain her prevailing problems. In spite of these, she is one of those who have successfully returned to their teaching profession using tracheostomy

Table1: Surgical/medical complications and frequency of occurrence

Complications	Frequencies of occurrence in each case				
	Case 1	Case 2	Case 3	Case 4	Total (%)
Stoma infection	7	5	5	1	18 (26.8)
Polyp around stoma	5	2	2	1	10 (15)
Tube fenestration blockage	2	3	5	Nil	10 (15)
Hemorrhage	Nil	Nil	Nil	Nil	0 (0)
Excessive mucus production	15	6	7	1	29 (43.2)
					69 (100)

with speaking valves.

Apart from the surgical complications arising from tracheostomy, we identified many setbacks affecting all the patients. These setbacks and our management are described below:

1. Family reluctance to accept patients – 75% (3);
2. Problems of social integration – 100% (4)
3. Rehabilitation to professional use of voice – 50% (2)
4. Scarcity of tracheostomy tube with speaking valves

Family acceptance measures

Informing patient of a permanent tracheostomy always poses a rude shock to them and their relations especially spouses. The euphoria of the relief from goiter quickly disappears and is replaced by misery and despair. Spouses and other relations get terrified and their number of visits continues to decline. The constantly asked question is “when will the tube be removed?” And this exposes their reluctance to take their wives home with the tube.

We overcame the problem of rejection by having many rounds of doctor/family conferences. All concerned were educated in these conferences focusing on the benefits, the complications, the reasons why the tube may not be fully removed and how best to look after the tube. This was done about once a week postoperatively and repeated just before discharge. The oldest patient in this study (a teacher) was always invited to share experience and to encourage the patients, which she gladly did and we take pains to answer all questions about fears around the tube. Teaching patients/siblings on changing tracheostomy tube becomes easier after such conferences. The patient is supervised to master inner tube changing first before whole tube changing.

The patient and at least one relation are encouraged to learn the techniques of tube changing to build up confidence. The problem of rejection or family fears was finally controlled by these interactions.

Problems of social integration

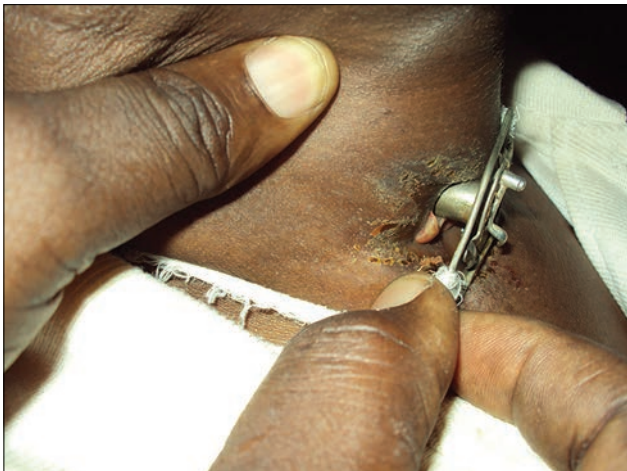

Figure 1: Polyp formation around stoma

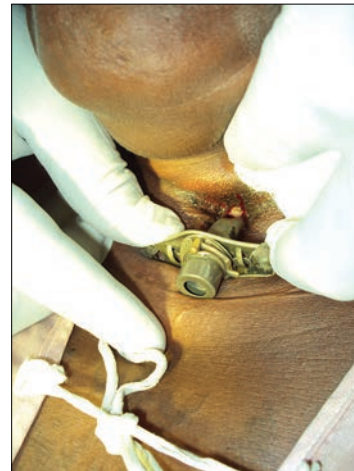

Figure 2: Soft tissue blockage of tube fenestration

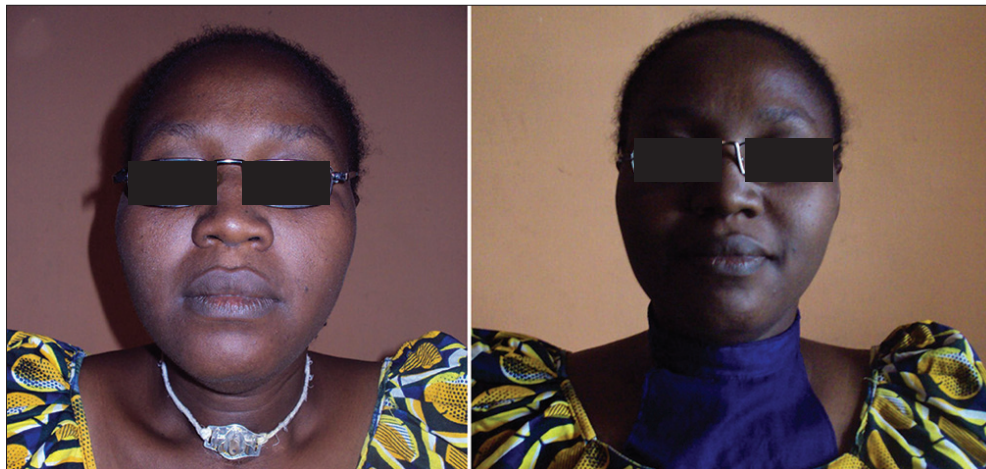

Figure 3: High neck collar bib designed to conceal both the tube and the tape

Tracheostomy is not one of the common artificial devices the public is used to. The presence of a tracheostomy tube on the neck of patient constitutes a social stigma and inhibition to social interaction. It is not only unattractive but in some communities, it is scaring. To prevent this social embarrassment we devised a number of costumes to conceal the tube. Some in form of high neck collar bib designed to conceal both the tube and the tape as shown in Figure 3.

These are made of different colors to match any particular cloth worn by the patient. The tubes are also concealed with different fashionable mufflers around the neck using very light non-airtight materials. Gold necklaces were also designed like jewelries to replace the conventional tape of the tracheostomy tube as shown in Figure 4.

Rehabilitation to professional use of voice

Patients with bilateral vocal cords paralysis have close to normal voice. This is because the cords assume a paramedian position. In some however, the pitch of their voice may drop. All our patients had close to normal voices before tracheostomy was instituted, except the fourth patient who presented in a semi-comatose state and the voice quality could not be assessed before surgery. This made adjustment to tracheostomy with speaking valve very easy and beneficial. With the modalities of concealing the tube and beautification with gold necklace, two of our patients who are primary school teachers were successfully rehabilitated back to their jobs and were able to cope satisfactorily. The other two got adjusted very comfortably and they can easily pass by without tracheostomy being noticed.

Scarcity of tracheostomy with speaking valves for maintenance

This has constituted one very difficult problem. Tubes of this type are very scarce in the Nigerian Medical equipment markets. Many equipment sellers have never heard or seen

one. Sometimes, we are compelled to use any available fenestrated tracheostomy tubes when the right-size tube was not available.

Occasionally, we had to employ local technology to drill fenestration to provide the needed space for air and speech production on any available standard metal tubes when we are short of tubes with speaking valves, and rounded wooden or plastic materials were fashioned to block the external tracheostomy tube hole during the day and removed at night to allow for adequate breathing as shown in Figure 5. At the time of this report, the first three of our patients have mastered all techniques of tracheostomy tube changing. They only came to clinic when new tubes are required or when they have other medical problems. They strictly maintain their clinic appointments.

Discussion

Tracheostomy is a common surgical procedure employed in the relief of upper respiratory obstruction.^[1] However, in the surgical management of goiter, tracheostomy may be employed at different stages. The need to employ tracheostomy in surgical management of goiter may be apparent preoperatively. A.A. Abdel *et al.* identified some risk factors that may be a pointer for use of tracheostomy in thyroidectomy. These include a large goiter of over 5 years, preoperative recurrent laryngeal nerve palsy, thyroid cancer, marked tracheal deviation, retrosternal goiter and difficult intubation.^[5] Post-thyroidectomy respiratory obstruction and stridor could be a pointer to bilateral recurrent laryngeal nerve paralysis. Other causes of upper airway obstructions after thyroidectomy include laryngeal edema, tracheomalacia or tracheal collapse from long-standing compression of trachea by a large goiter.^[6] Other indications for a permanent tracheostomy include laryngeal paralysis or collapse, radiation therapy of the upper airways or oropharynx, laryngotracheal resections, staged laryngeal reconstruction, nasal neoplasia or severe secretory respiratory disease.^[2]



Figure 4: Gold necklace designed like jewelry to replace the conventional tape of the tracheostomy tube

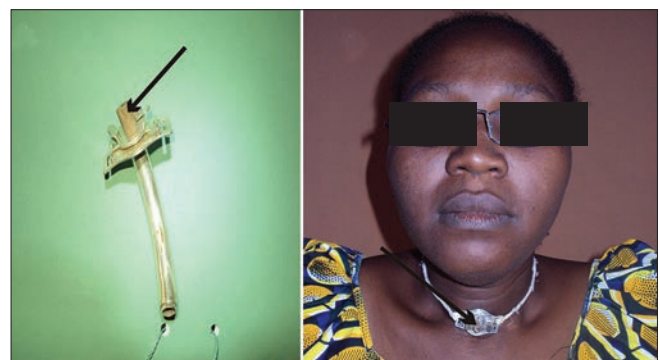


Figure 5: Rounded wooden material fashioned to block the external tracheostomy tube hole

While tracheostomy is considered a relatively safe procedure, it is not without its own share of both minor and major complications. Over the years, tracheostomy has been performed by all categories of surgeons. The patient with permanent tracheostomy lives virtually all his life with a tube in the neck. Their attention is constantly drawn to the tube and the euphoria attached to the relief from the primary goiter is quickly lost.

In the unfortunate event of a patient sustaining bilateral laryngeal nerve damage during thyroidectomy, a permanent tracheostomy is inevitable in our environment. This is because other modalities of restoration of laryngeal function e.g. nerve grafting is a lot more technically difficult and the result is not immediate. Paralysis of both recurrent laryngeal nerves poses one of the most difficult complications of thyroidectomy.

The need for post-operative tracheostomy in bilateral recurrent laryngeal nerve paralysis has nothing to do with dust-laden environment as argued by Gyoh and Emery.^[7] It is often mandatory as their survival usually depended on it. When the predictive risk factors are high preoperatively, the patients and close relations e.g., spouses or at least one sibling need thorough enlightenment about the possibility of tracheostomy that may be permanent. This will facilitate easy acceptability by all concerned. In case of a difficult thyroidectomy or when risk factors are many, a direct laryngoscopy preoperatively and tracheostomy intraoperatively may be safe and prevent an unplanned emergency tracheostomy.^[5] (This was the case in two of our patients.)

The practice of carrying out direct laryngoscopy immediately postoperatively provide the necessary information about the

status of the vocal cords and integrity of the laryngeal nerves to differentiate it from laryngeal edema or laryngomalacia or other causes of respiratory obstruction in the immediate post-thyroidectomy period.

Conclusion

The problem of looking after a permanent tracheostomy is much higher than that of surgical complications, and material for voice maintenance and rehabilitation is particularly scarce in our environment. As such, all effort must be made to prevent bilateral recurrent laryngeal nerve paralysis during thyroidectomy in our environment.

References

1. Amusa YB, Akinpelu VO, Fadiora SO, Agbakwuru EA. Tracheostomy in surgical practice- experience in a Nigerian tertiary hospital. *West Afr J Med* 2004;23:32-4.
2. Hedlund CS. Surgery of the upper respiratory system. In: Fossum TW, editor. *Small Animal Surgery*. St. Louis: the CV Mosby Co; 1997. p. 609-47.
3. Eisele DW, Smith RV. Complications in Head and Neck Surgery. 2nd ed. Philadelphia: Mosby Elsevier; 2009; 409-16
4. Bailey BJ, Johnson JT. *Head and Neck Surgery-Otolaryngology*. 4th ed. Philadelphia: Lippincott Williams and Wilkins; 2006;663.
5. Abdel Rabim AA, Ahmed ME, Hassan MA. Respiratory complications after thyroidectomy and the need for tracheostomy in patient with a large goiter. *Br J Surg* 1999;86:88-90.
6. Mchenry CR, Pihorski JJ. Thyroidectomy in patients with marked thyroid enlargement, airway management, morbidity and outcome. *Am Surg* 1994;60:586-9.
7. Gyoh SK, Emery JG. Coping with respiratory obstruction after thyroidectomy for giant goiters in Northern Nigeria. *Ann R Coll Surg Engl* 1988;70:99-104.

How to cite this article: Akenroye MI, Osukoya AT. Permanent tracheostomy: Its social impacts and their management in Ondo State, Southwest, Nigeria. *Niger J Clin Pract* 2013;16:54-8.

Source of Support: Nil, **Conflict of Interest:** None declared.