

# Bladder stones in catheterized spinal cord-injured patients in Nigeria

Kawu AA, Olawepo A<sup>1</sup>, Salami OOA<sup>2</sup>, Kuranga SA<sup>3</sup>, Shamsi H<sup>4</sup>, Jeje EA<sup>5</sup>

Department of Orthopaedics, University of Abuja Teaching Hospital Gwagwalada, Abuja FCT, <sup>1</sup>Department of Anatomy, University of Ilorin, Ilorin, <sup>2</sup>Department of Surgery, National Orthopaedic Hospital, Yaba, Lagos, <sup>3</sup>Department of Surgery, University of Ilorin Teaching Hospital, <sup>4</sup>Department of Orthopaedics, KMC Manipal, Mangalore, <sup>5</sup>Department of Surgery, Lagos University Teaching Hospital, Lagos Nigeria

## Abstract

**Objective:** The objective was to determine the incidence of bladder stones in patients with spinal cord injury (SCI) and to assess if catheter encrustation or positive urinary culture of *Proteus mirabilis* is predictive of bladder stones. Background: Bladder stones are common urological complication in those with SCI managed with indwelling urinary catheter. Detection and removal of bladder stones are important to prevent possible further complications.

**Design:** This was a prospective cohort study.

**Materials and Methods:** Ultrasound scan was performed in persons with SCI seen from 1st January to 31st December 2009 who had indwelling urethral catheter for at least 3-month post-injury. Indwelling urethral catheters were examined for encrustation at the time of removal, urine culture taken specifically for *P. mirabilis* and ultrasound scan done to detect bladder stones.

**Results:** There were 89 patients with spinal cord injury and 68 (76.4%) patients were evaluated during the review period. Twenty-nine (42.6%) patients had bladder stones and 22 (32.3%) patients had catheter encrustation. Of the 22 patients with catheter encrustation, 19 (86.3%) also had bladder stones. Forty-six (67.6%) patients had no catheter encrustation. Of these, 7 (14.7%) were found to have bladder stones. Thirty-seven (38.2%) urine cultures were positive for *P. mirabilis*. Of these 37 (54.4%) patients, 27 also had bladder stones. Catheter encrustation ( $P = 0.004$ ) and a positive urine culture of *P. mirabilis* ( $P = 0.007$ ) in patients with indwelling urinary catheter is highly predictive of the presence of bladder stone.

**Conclusions:** This study shows that a large number of SCI patients have an indwelling urethral catheter and suggests that ultrasound scan for the presence of stone should be schedule in a catheterized SCI patient if catheter encrustation or a positive urine culture of *P. mirabilis* is noted.

**Key words:** Bladder stones, spinal cord injuries, ultrasound scan, urethral catheter

**Date of Acceptance:** 26-April-2011

## Introduction

Spinal cord injury (SCI) in Nigeria is an age old problem.<sup>[1-5]</sup> There is an increase use of the indwelling urinary catheter in SCI patients because of the increase number of patients with cervical injury, also in women with a high-level injury with adductor spasticity and in order to shorten hospital stay patients are discharged early to rehabilitation with

indwelling urinary catheter.<sup>[6,7]</sup> With this increase in indwelling catheter use, there is an attendant increase in complications resulting from its use.

Linsensmeyer *et al*,<sup>[6]</sup> noted the important role of indwelling catheters at increasing the risk of bladder stones in spinal

### Address for correspondence:

Dr Kawu A Ahidjo,  
Spine Unit, Department of Orthopaedics, University of Abuja  
Teaching Hospital, Gwagwalada, PMB 228, Abuja FCT, Nigeria.  
E-mail: ahidjokawu@yahoo.com

### Access this article online

#### Quick Response Code:



**Website:** www.njcponline.com

**DOI:** \*\*\*

**PMID:**

cord-injured patients. The indwelling catheter has been implicated in bladder stones formation that are a common urological complication in SCI.<sup>[8-10]</sup> In tandem with the indwelling catheter, *Proteus mirabilis* a urease-producing bacterium, alkalinizes urine promoting crystallization of struvite and calcium phosphate leading to stone formation.<sup>[11]</sup> Bladder stones can cause blockage of the catheter leading to bladder distension and consequent autonomic dysreflexia in those with thoracic injuries at T6 level.<sup>[6,8]</sup>

The objective of this study is to determine the incidence of bladder stone in patients with SCI with an indwelling urethral catheter and to assess if catheter encrustation or a positive urinary culture of *P. mirabilis* is predictive of bladder stone in Nigerian subjects.

### Materials and Methods

The records of patients admitted at the University of Abuja Teaching Hospital, Gwagwalada from 1st January 2009 to 31st December 2009 were prospectively reviewed. All patients with a SCI who were admitted in our institution had an indwelling urethra catheter for at a least duration of 3 months since the injury and gave an informed consent were included in this study. Ethical approval was obtained before the commencement of this study.

All patients in this study had their catheters personally change by the first author. Catheters were examined for crust and catheter tips sent for microscopy, culture, and sensitivity. Data extracted include catheter tip culture for *P. mirabilis*, presence or absence of stone crust on the catheter and presence or absence of bladder stone on ultrasound scan.

Bladder stone recorded following a least duration of 3 months of the indwelling urethral catheter were designated as dependent variables to identify potential risk associations. Data were analyzed using the chi-square analysis or Fisher’s exact test. The predictive measures were determined by crude odds ratios (ORs) and adjusted odds ratios (adjusted ORs). The ORs were adjusted using multivariate logistic regression; 95% confidence intervals (CI) were used and P-value of <0.05 was significant. Statistical Package for Social Sciences (SPSS) 17.0 was employed for this analysis.

### Results

Sixty-eight SCI patients with indwelling urethral catheter were enrolled and evaluated in this study after 3 months of catheter use. There are 29 (42.6%) patients with bladder stones. Catheter encrustation was noted in 22 (32.4%) patients. Of these 22 patients, 19 (86.3%) also had bladder stones. In other words, a positive result for catheter encrustation had a positive result for bladder stones 86.3% of the time. Thirty-six individuals had no catheter encrustation; 3 (8.3%) of these patients were found to have bladder stones. This is depicted in Figure 1.

Figure 2 shows the relationship between positive culture of *P. mirabilis* and the presence of bladder stone. *Proteus mirabilis* was cultured in 37 (22.1%) patients. Of these 37 patients, 27 (73.0%) also had bladder stones. A positive result (73.0%) for culture of *P. mirabilis* had a positive result for bladder stones. Thirty-one individuals had no positive culture for *P. mirabilis*, 2 (5.9%) of these patients were found to have bladder stones. Table 1 shows the statistical analysis of the positive predictive value of catheter encrustation and a positive culture of *P. mirabilis*. The association between bladder stone, catheter encrustation, and positive culture of *P. mirabilis* is shown in Table 2.

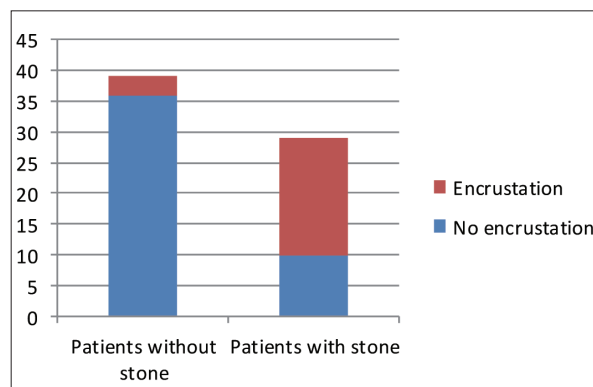


Figure 1: Catheter encrustation and the presence of bladder stone (the figure on the y-axis is the actual number of patients)

Table 1: Predictive value of catheter encrustation and a positive culture of *Proteus mirabilis*

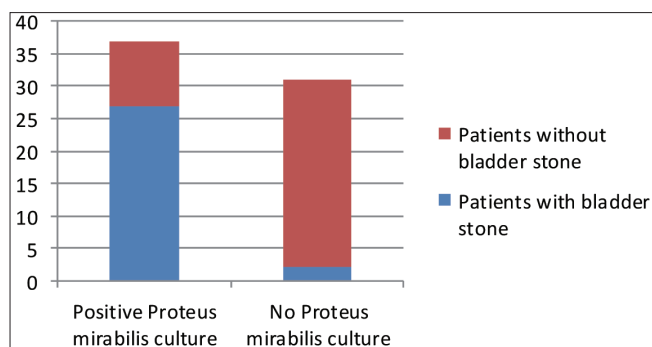
Parameter	Presence of bladder stone (%)	Absence of bladder stone (%)	P-value
Catheter encrustation	19/22 (86.3%)	3/22 (13.7%)	0.004*
Positive <i>Proteus mirabilis</i> culture	27/37 (73.0%)	10/37 (27.0%)	0.007*

\*Chi-square test

Table 2: Predictors of bladder stone

Parameter	Present (%)	Absent (%)	OR	Adjusted OR	P-value
Catheter encrustation	18/22 (81.8)	7/46 (15.2)	2.5	2.1 (1.4-3.3)	0.001§
Positive culture for <i>P.mirabilis</i>	27/37 (72.9)	2/31 (6.5)	3.3	2.4 (1.7-6.3)	0.001§

§Mann-Whitney U test. *P. mirabilis* - *Proteus mirabilis*



**Figure 2:** Proteus mirabilis culture and the presence of bladder stone (the figure on the y-axis is the actual number of patients)

## Discussion

Indwelling catheter is an adjunct in the management of SCI in Nigeria.<sup>[1-5]</sup> This study showed that majority of the SCI patients in our study have an indwelling urethral catheter. This agree with findings by other workers<sup>[6,10-13]</sup> who noted a higher use of indwelling urethral catheter in SCI. The catheter stones result from synergism of bacteria such as *P. mirabilis* that alkalinizes the urine and promotes crystallization of struvite and calcium phosphate facilitated by foreign body like the catheter leading to catheter encrustation.<sup>[6,9,12-16]</sup> Formation of this small stones set up a cascade leading to more stone formation despite a change in catheter. This stone may block the catheter lumen obstructing urinary flow causing bladder distension.<sup>[15,16]</sup>

The “gold standard” to detect bladder stones is through the use of cystoscopy.<sup>[8]</sup> Ultrasound scanning was however used in this study to detect bladder stone because it is noninvasive, easily available, reproducible, and cheap. This is considering that majority of our patients live on less than a dollar a day in Nigeria.<sup>[17]</sup> Complications<sup>[18]</sup> like were not recorded in this study.

This study shows a strong correlation between bladder stone, positive culture for *P. mirabilis*, and catheter encrustation. In the study by Linsenmeyer *et al.*,<sup>[6]</sup> they noted an 85% chance that bladder stones are present if there is catheter encrustation. In our study we also noted 86.3% chance despite different modality used to detect the stone. Also a positive culture for *P. mirabilis* provides an excellent correlation with the presence of bladder stones. In this study, if there is a positive culture for *P. mirabilis*, there is a 73.0% chance that bladder stones are also present. Therefore, if at any time a catheter is noted to be encrusted or there is a positive culture for *P. mirabilis*, a patient should be scheduled for ultrasonography to detect stone.

A small number of patients who had bladder stone had neither positive culture for *P. mirabilis* nor catheter encrustation; therefore to avoid missing bladder stones in

such patients, ultrasonogram should be scheduled yearly for all patients to detect bladder stone.

## Conclusion

This study shows that a large number of SCI patients have an indwelling urethral catheter. There is also a high association between bladder stones and the presence of catheter encrustation or positive culture of *P. mirabilis*. It therefore suggests that ultrasound scan for the presence of stone should be schedule in a catheterized SCI patient if catheter encrustation or a positive urine culture of *P. mirabilis* is noted.

## References

- Solagberu BA. Spinal cord injuries in Ilorin, Nigeria. *West Afr J Med* 2002;21:230-2.
- Obalum DC, Giwa SO, Adekoya-Cole TO, Enweluzo GO. Profile of spinal injuries in Lagos, Nigeria. *Spinal Cord* 2009;47:134-7.
- Olasode BJ, Komolafe IE, Komolafe M, Olasode OA. Traumatic spinal cord injuries in Ile-Ife, Nigeria, and its environs. *Trop Doct* 2006;36:181-2.
- Umaru H, Ahidjo A. Pattern of spinal cord injury in Maiduguri, North Eastern Nigeria. *Niger J Med* 2005;14:276-8.
- Nwadinigwe CU, Iloabuchi TC, Nwabude IA. Traumatic spinal cord injuries (SCI): a study of 104 cases. *Niger J Med* 2004;13:161-5.
- Linsenmeyer MA, Linsenmeyer TA. Accuracy of predicting bladder stones based on catheter encrustation in individuals with spinal cord injury. *J Spinal Cord Med* 2006;24:402-5.
- Nobunga AI, Go BK, Karunas RB. Recent demographic and injury trends in people served by Model Spinal Cord Injury Care Systems. *Arch Phys Med Rehabil* 1999;80:1372-82.
- Linsenmeyer TA, Stone JM, Stein S. Neurogenic bladder and bowel dysfunction. In: DeLisa JA, editor. *Rehabilitation Medicine Principles and Practice*. 4th ed. Philadelphia, PA: Lippincott-Raven; 2004. p. 1619-53.
- Cardenas D, Farrell-Roberts L, Sipski M, Rubner D. Management of gastrointestinal, genitourinary and sexual function. In: Stower SL, DeLisa JA, editors. *Spinal Cord Injury- Clinical Outcomes from the Model System*. Gaithersburg, MD: Aspen Publication; 1995. p. 120-45.
- DeVivo MJ, Fine PR, Cutter GR, Maetz HM. The risk of bladder calculi in patients with spinal cord injuries. *Arch Intern Med* 1985;145:428-30.
- Mobley HL, Warren JW. Urease-positive bacteriuria and obstruction of long-term urinary catheters. *J Clin Microbiol* 1987;25:2216-7.
- Favazza T, Midha M, Martin J, Grob BM. Factors influencing bladder stone formation in patients with spinal cord injury. *J Spinal Cord Med* 2004;27:252-4.
- Linsenmeyer TA, Ottenweller J. Bladder stones following SCI in the Sprague-Dawley rat. *J Spinal Cord Med* 2003;26:65-8.
- Ord J, Lunn D, Reynard J. Bladder management and risk of bladder stone formation in spinal cord injured patients. *J Urol* 2003;170:1734-7.
- Hedelin H, Eddeland A, Larsson L, Pettersson S, Ohman S. The composition of catheter encrustations, including the effects of allopurinol treatment. *Br J Urol* 1984;56:250-4.
- Stamm WE. Catheter-associated urinary tract infections: epidemiology, pathogenesis, and prevention. *Am J Med* 1991;91:655-715.
- UNDP. Press release. Nigeria's President Obasanjo applauds UN strategy to end world poverty at Millennium project. Available from: <http://undp.org/dpa/pressrelease/2005/march/htm>. [Last cited on 2010 Jan 19].
- Binard JE, Persky L, Lockhart JL, Kelley B. Intermittent catheterization the right way! (Volume vs. time-directed). *J Spinal Cord Med* 1996;19:194-6.

**How to cite this article:** ???

**Source of Support:** Nil, **Conflict of Interest:** None declared.