

Bilateral post-traumatic acute extradural hematomas: A report of four cases and review of literature

DO Udoh

Department of Surgery, University of Benin Teaching Hospital, P.M.B., Benin City, Edo State, Nigeria

Abstract

Bilateral extradural hematomas are rare and follow significant trauma. The mortality is higher than with unilateral single extradural hematomas and postoperative outcome depends on preoperative neurological status.

Key words: Bilateral, extradural, hematoma, outcome, trauma

Date of Acceptance: 14-Jul-2011

Introduction

Extradural hematoma (EDH), seen in 1–2% of head injury cases, is a major source of preventable mortality.^[1] Acute bilateral EDH is rare.^[2-8] Described before the era of computerized tomography (CT), it was associated with poor results, with mortality ranging between 15 and 100% in reported cases.^[4-8] CT has made diagnosis easier and improved prognosis.^[5]

We present four illustrative cases, out of 37, of surgically-managed EDH seen on our service in three years.

Case Reports

Case 1

A 64-year-old carpenter was admitted 24 h following a motor vehicle accident. He was referred with progressive neurological deterioration after adequate resuscitation. He had premorbid systemic high blood pressure. His Glasgow coma score (GCS) was 11. His pupils were 4 mm in diameter bilaterally. Cranial CT scan showed (i) multiple biparietotemporal linear skull fractures (ii) biparietal EDH, three times larger on the left, and (iii) effacement of the lateral ventricles and sulci [Figures 1 and 2].

Due to his age and uncontrolled premorbid hypertension,

the decision was made for precipitate evacuation of the larger left parietal EDH reducing anesthetic and operative times and reducing the possibility of intraoperative hypertensive complications. He had emergency left frontoparietal craniotomy with evacuation of 200 ml of clot. Postoperatively, GCS improved to 15 within 12 h. Repeat CT scan showed spontaneous resolution of the nonoperated right EDH. He was discharged on the 10th postoperative day.

Case 2

A 20-year-old farmer was admitted 6 h after a branch of a tree struck him on the head during tree-felling. He lost consciousness immediately. His Glasgow coma score was 8 with 6 mm diameter sluggishly-reacting pupils bilaterally. He had features of imminent tentorial herniation. CT brain showed (i) multiple linear bifrontotemporal skull fractures, (ii) bifrontal EDH across the midline, and (iii) effacement of the ventricles, basal cisterns, and sulci [Figures 3 and 4].

He underwent emergency bifrontal craniotomy with evacuation of clot. Intraoperative findings included bleeding from the diploic veins and a torn frontal part of the superior sagittal sinus. Both were controlled. He improved to a GCS of 15 and was discharged after 2 weeks.

Address for correspondence:

Dr. David Okon Udoh,
University of Benin Teaching Hospital, P.M.B. 1111, Benin City,
Edo State, Nigeria.
E-mail: daveudoh@yahoo.com

Access this article online

Quick Response Code:



Website: www.njcponline.com

DOI: 10.4103/1119-3077.94111

PMID: 22437103

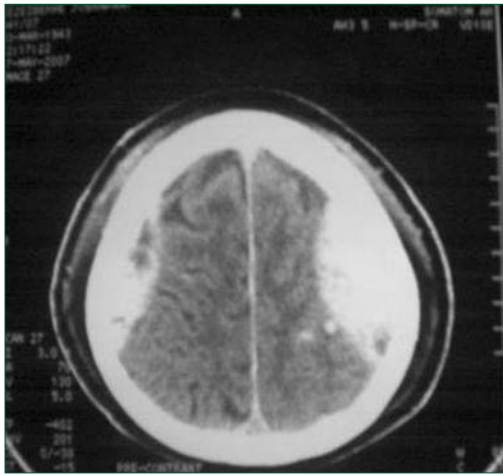


Figure 1: Biparietal EDH in a 64-year-old man showing a much larger left parietal clot which was evacuated initial gait disturbance

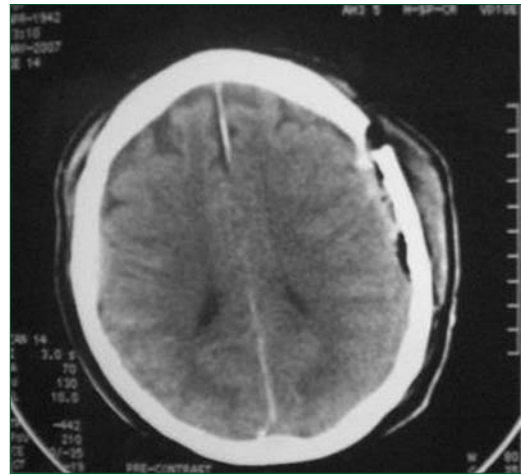


Figure 2: Postoperative CT showing spontaneous resolution of the nonoperated right parietal clot. Note the craniotomy flap on the left side

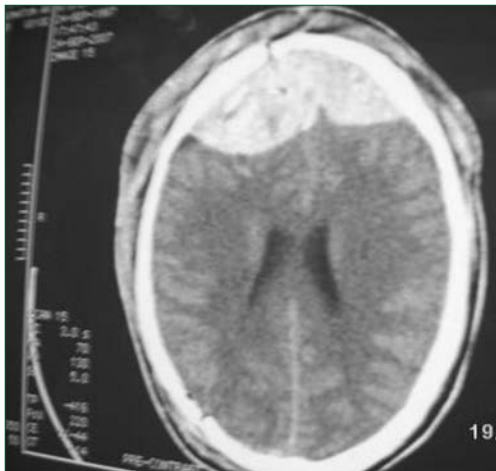


Figure 3: Bifrontal EDH in a 20-year-old male. Note the frontal skull fracture

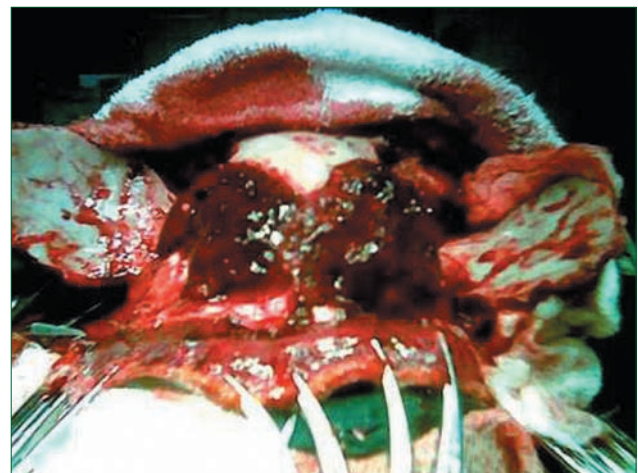

Figure 4: Separate bilateral frontal craniotomies. Note the clot across the midline and the damaged superior sagittal sinus which was the source of the hematomas

Case 3

A 23-year-old right-handed male student presented 30 min following a gunshot injury to the back of the head. He was shot at the back of the head with a low velocity hand gun while lying face down at a distance of 1 m from the occiput. There was no history of loss of consciousness, but he bled profusely from the injury.

Physical examination showed a young man with Glasgow coma score of 15. Mental status and cranial nerves were intact and he had generalized hyperreflexia; power was grade 5 in all muscle groups. His pupils were 3.5 mm in diameter bilaterally and they reacted briskly to light. The vital signs were normal.

CT scan of the brain showed (i) a linear right occipital fracture, (ii) multiple intra- and extracranial pellets, (iii) a right occipital hyperdense lenticular occipital collection, and (iv) mild effacement of the fourth ventricle and dilatation of the temporal horn of the right lateral ventricle.

The hematoma measured <1 cm. A decision was taken to manage nonoperatively.

He developed progressively worsening occipital headaches radiating to the back of the neck and drowsiness on the 5th day. Bilateral pupillary diameter increased to 4 mm and both reacted sluggishly to light. A decision was then taken to carry out an operative decompression and he underwent an emergency suboccipital craniectomy and evacuation of clot.

The operative finding was 50 ml of extradural clot which was now bilateral with oozing from the torcula herophili (confluens sinuum). Clot was evacuated and the bleeding from the torcula herophili was controlled with pressure packing using oxidized cellulose.

He improved neurologically and was discharged without headaches on the 8th postoperative day.

Case 4

A 60-year-old male was referred to us from a general hospital. He was a victim of a motor vehicle crash six days before the referral and had remained unconscious since the incident.

Physical examination showed an elderly man with Glasgow coma score of 7 and his pupils were 6 mm in diameter bilaterally with no reaction to light. His blood pressure was 170/90 mmHg and he had an average volume, regular pulse of 58 beats per minute. His respiration was irregular with a rate of 36 cycles per minute.

CT scan showed (i) biparietal hyperdense lenticular lesions, (ii) overlying depressed skull fractures, (iii) effacement of the sulci, both lateral ventricles, third ventricle, Sylvian fissures, and the periquadrigenal cistern.

The diagnosis was biparietal EDH with imminent tentorial herniation.

He had emergency biparietal elevation of depressed skull fracture with evacuation of 300 ml of EDH from both sides.

He continued to deteriorate and died on the 2nd postoperative day.

Discussion

Bilateral extradural hematomas are rare findings associated with significant mortality in the pre-CT era.^[4] Usually, the patients are young adults, and it is rarer in children. The incidence has been reported to range between 2 and 10%.^[6,7] Male to female ratio is 5:1; it is found across the midline in 50–69% of cases and in different locations in the rest.^[6,8] There is associated skull fracture, most often linear, in 95–100% of patients.^[3,6,7,9] In fractures across the midline, bleeding may result from the superior sagittal sinus.^[5]

EDHs are contact injuries resulting from blunt trauma to the skull; it was thought that the initial impact with cranial fracture detaches the dura and injures blood vessels – once bleeding begins, the extradural space fills with blood.^[9,10] Arterial bleeding produces hydrostatic water pressure effects progressively stripping away the dura from the skull and widening the perimeter of the hematoma.^[10] Venous bleeding is slower, so tends to be smaller in size and less severe due to the ease of spontaneous arrest.

Bilateral EDH usually follows significant head trauma resulting in rapid, sometimes late, deterioration in sensorium, even in patients who initially had no neurological deficits; this indicates rapid expansion with imminent tentorial herniation.^[3] Thus, there is need for serial CT evaluation when minimal bilateral EDH shows on initial scans.^[3]

Rarely, acute bilateral EDH may occur sequentially rather than simultaneously and may escape detection by initial CT. Thus, serial CT scanning is also necessary for diagnosis when a patient deteriorates after removal of the unilateral collection.^[2,5]

Over 95% of cases require evacuation, sometimes bilateral simultaneous craniotomies by two neurosurgeons.^[3,8] However, there is a tendency toward less and less surgical intervention in EDH if avoidable; EDHs have been known to resolve spontaneously within 6 h, presenting the possibility for conservative management.^[8,11-13] Thus, there is a strong case for leaving EDH less than 1 cm diameter if the patient might deteriorate from the procedure.^[11] Serial CT is essential in conservatively managed EDH and these include nonsurgical cases who have grave prognosis.^[1,3,12,14]

Conclusion

Bilateral post-traumatic acute extradural hematomas no longer carry the high mortality of the pre-CT era due to improved radiological diagnosis and monitoring combined with expeditious operative decompression

Acknowledgment

I acknowledge the immense and tireless assistance of Josephine Egbewuare, the Secretarial Assistant of our Neurological Surgery Unit for all the hours she spent putting this publication together.

References

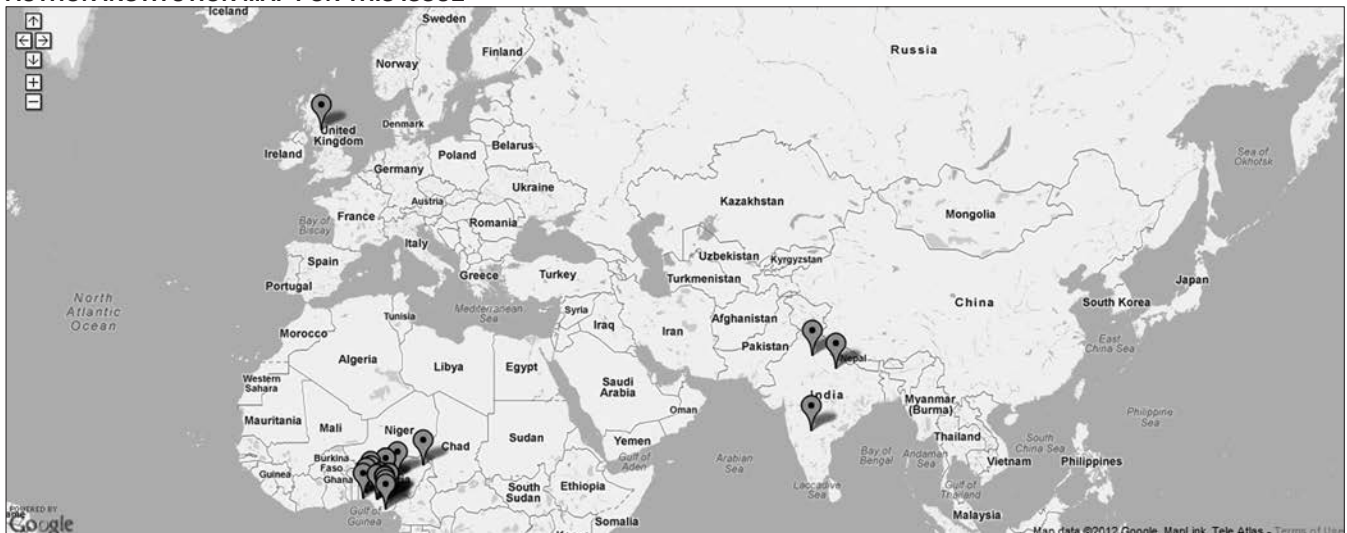1. Babu ML, Bhasin SK, Kumar A. Extradural haematoma - an experience with 300 cases. *Surg Neurol* 2005;7:205-7.
2. Reale F, Biancotti R. Acute bilateral epidural hematoma. *Surg Neurol* 1985;24:260-2.
3. Idei M, Shima T, Nishida M, Yamane K, Mihara C, Hatayama T, et al. Symmetrical bilateral extradural haematoma after head injury in the mid-parietal region: case report. *No Shinkei Geka* 2004;32:379-82.
4. Subrahmanian MV, Rajendraprasad GB, Rao BD. Bilateral extradural haematomas. *Br J Surg* 1975;62:397-400.
5. Bret P, Gavin C, Massini B, Bascoulergue Y, Huppert J. Bilateral extradural haematomas. Report of two cases. *Neurochirurgia (Stuttg)* 1987;30:193-6.
6. Gelabert-González M, Iglesias-Pais M, Serramito-García R, Fernández-Villa J, García-Alluz A, Martínez-Rumbo R. Simultaneous bilateral epidural haematomas. *Neurocirugia (Astur)* 2005;16:256-60.
7. Dharker SR, Bhargava N. Bilateral epidural haematoma. *Acta Neurochir (Wien)* 1991;110:29-32.
8. Gorgulu A, Cobanoglu S, Armagan S, Karabagli H, Tervuz M. Bilateral epidural hematoma. *Neurosurg Rev* 2000;23:30-3.
9. Baykaner K, Alp H, Cerviker N, Keskil S, Seçkin Z. Observation of 95 patients with extradural hematoma and review of the literature. *Surg Neurol* 1988;30:339-41.
10. Crooks DA. Pathogenesis and biomechanics of traumatic intracranial haemorrhages. *Virchows Arch A Pathol Anat Histopathol* 1991;418:479-83.
11. Ugarriza LF, Cabezudo JM, Fernandes-Portales I. Rapid spontaneous resolution of an acute extradural haematoma: case report. *Br J Neurosurg* 1999;13:604-5.
12. Servadei F, Staffa G, Pozzati E, Piazza G. Rapid spontaneous disappearance of an acute extradural hematoma: case report. *J Trauma* 1989;29:880-2.

13. Kuroiwa T, Tanabe H, Takatsuka H, Arai M, Sakai N, Nagasawa S, et al. Rapid spontaneous resolution of acute extradural and subdural hematomas. Case report. *J Neurosurg* 1993;78:126-8.
14. Mishra A, Mohanty S. Contre-coup extradural haematoma: A short report. *Neurol India* 2001;49:94-5

How to cite this article: Udoh DO. Bilateral post-traumatic acute extradural hematomas: A report of four cases and review of literature. *Niger J Clin Pract* 2012;15:104-7.

Source of Support: Nil, **Conflict of Interest:** None declared.

AUTHOR INSTITUTION MAP FOR THIS ISSUE



Please note that not all the institutions may get mapped due to non-availability of requisite information in Google Map. For AIM of other issues, please check Archives/Back Issues page on the journal's website.