

# Oxyphil cell adenoma in a Nigerian: Case report and review of the literature

AE Aghaji, DB Olushina<sup>1</sup>, OI Okoye

Departments of Ophthalmology, and <sup>1</sup>Morbid Anatomy, University of Nigeria Teaching Hospital, Enugu, Nigeria

## Abstract

Oncocytomas of the lacrimal gland are rare tumors. We report the first documented case in Nigeria. This was an interventional case report. A complete ophthalmologic and systemic examination with available pertinent investigations was done, followed by a modified exenteration and histopathologic examination. A 60-year-old Nigerian housewife was evaluated for a slow-growing, right upper lid mass associated with visual lesion in the ipsilateral eye. Plain skull x-rays revealed a soft tissue in the right eye orbit without any bony extension. A modified exenteration was done. Histopathology showed sheets of oxyphil cells in the lacrimal gland. Although rare, more cases of oncocytomas may exist than are reported in the literature.

**Key words:** Adult Nigerian female, lacrimal gland, oxyphil cell adenoma, rare

**Date of Acceptance:** 14-Feb-2011

## Introduction

Oxyphil cell adenoma (oncocytoma) like the name implies is a benign epithelial tumor of glandular origin. Although it has been found in salivary, pituitary, and adrenal glands,<sup>[1]</sup> it is extremely rare in the lacrimal gland.<sup>[2,3]</sup> Most cases of this rare tumor in the ocular adnexa have been found in the lacrimal caruncle or lacrimal sac.<sup>[3]</sup> A MEDLINE search (1954–2009) reveals that there are a total of only 10 documented cases of lacrimal gland oncocytomas worldwide. Though the tumor is uncommon, it is seen in women after the fifth decade.<sup>[4]</sup> We report a single case of oxyphil cell adenoma of the lacrimal gland in an adult Nigerian female.

## Case Report

A 60-year-old housewife from South East Nigeria presented at the eye clinic of the University of Nigeria Teaching Hospital, with a 3-year history of gradually progressive painless swelling of the right upper lid.

There was no history of trauma, diplopia, weight loss, or chronic cough. Neither was there any history of intermittency, heat intolerance, or palpitations.

### Address for correspondence:

Dr. A. E. Aghaji,  
Department of Ophthalmology, UNTH, Enugu, Nigeria.  
E-mail: aaghaji@yahoo.co.uk

There was associated gradual visual loss with with redness and discharge and the patient admitted to using a traditional eye medication in the form of a topical herbal concoction. Three months prior to presentation, she instilled a more potent herbal concoction into the affected eye, resulting in severe pains.

She also complained of headaches on waking. There were no relieving factors and no projectile vomiting.

General examination revealed that she was not in any obvious distress with a large swelling over her right upper eyelid. She was not pale, jaundiced, or cachectic. However, there were palpably enlarged preauricular and submandibular lymph nodes on the affected side which were firm and discrete.

The ocular examination revealed a distance visual acuity of light perception with poor projection in the right eye and 6/36 in the left.

### Access this article online

#### Quick Response Code:



Website: [www.njcponline.com](http://www.njcponline.com)

DOI: 10.4103/1119-3077.86787

PMID: 22037088

There was a mass in the superolateral quadrant of the orbit, measuring 5×5 cm, which was lobular and firm with a cystic portion at the apex. There was 30 mm of proptosis using the Hertel's exophthalmometer at an intercanthal distance of 120 mm. The affected eye was displaced downward and inward. The orbital margins were free and regular except for the superotemporal aspect which could not be palpated due to the mass [Figure 1].

Ocular motility in the right eye was restricted superiorly and laterally.

There was ectropion of the lower lid, lagophthalmos, and poor Bell's phenomenon.

The cornea was diffusely hazy with pannus formation inferiorly.

Hematological and biochemical indices were within normal limits. The patient was negative for HIV I and II antibodies.

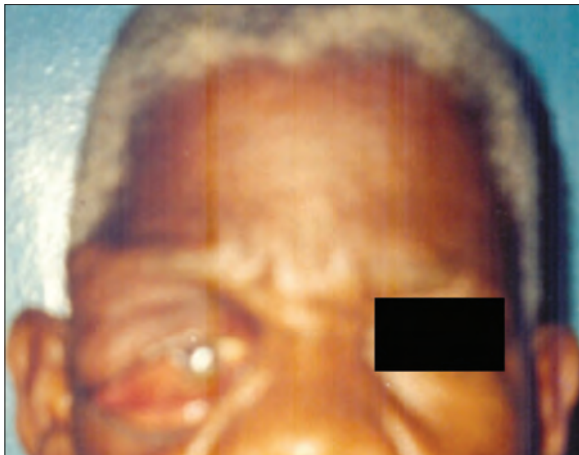A plain skull X-ray (anteroposterior and right lateral views) revealed a large soft tissue mass in the right eye orbit. The wings of the sphenoid were unaffected.

A modified exenteration was done and the entire mass sent for histology.

The cut surface revealed a uniformly brown surface.

Microscopy of the specimen revealed a tumor which comprised cords and sheets of round cells with abundant eosinophilic granular cytoplasm and uniform round vesicular nuclei [Figure 2].

A diagnosis of oxyphil cell adenoma was made and confirmed by a second pathologist.



**Figure 1:** Patient with proptosis in right eye

## Discussion

Lacrimal gland lesions are divided into nonepithelial and epithelial lesions.

The nonepithelial lesions which make up about 65% of lacrimal gland lesions include pseudotumor, lymphoid hyperplasia, nonspecific dacryoadenitis, Sjogren's syndrome, sarcoidosis, malignant lymphoma, and leukaemia.<sup>[5]</sup>

Of the epithelial tumors, benign mixed cell tumor (pleomorphic adenoma) is the most common, accounting for approximately 50% while about 50% are carcinomas.<sup>[6]</sup>

Oxyphil cell adenomas like the name implies are benign epithelial tumors of glandular origin arising in the ductal cell lining of apocrine glandular structures.<sup>[2]</sup>

They are well-circumscribed round or oval mass with a smooth or lobular surface.<sup>[4]</sup>

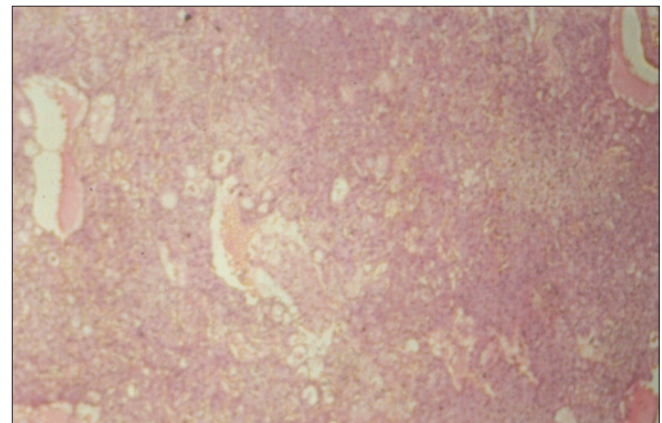
Our specimen was well-circumscribed and did not invade the globe or orbit.

The cut surface is uniformly pink or brown, sometimes showing small cysts.<sup>[4]</sup>

Lesions could be divided into three histological groups:<sup>[7]</sup>

- Tumors composed of tubules lined by tall columnar epithelium with fine granular cytoplasm
- Cystic tumors with prominent epithelial tufts projecting from much of the cyst wall
- Tumors with solid areas composed of variably cuboidal or polygonal cells, largely in trabecular arrangement and co-existing with the other tubular and cystic elements.

Other authors describe this tumor as being formed by large



**Figure 2:** Low power micrograph showing sheets of oxyphil cells and foci of microcyst formation

cells with eosinophilic granular cytoplasm with minimal lymphoid reaction of the stroma.<sup>[4]</sup>

Oncocytomas of the lacrimal gland are rare. In a Japanese study of 244 orbital tumors over a 21 year period, 86 lacrimal gland tumors were seen out of which none were oxyphil cell adenomas.<sup>[8]</sup> In 1969, Greer<sup>[9]</sup> reported two cases of oxyphil cell adenoma of the lacrimal caruncle but none in the lacrimal gland. The earliest reported case was by Beskid and Zarzycka in 1959.<sup>[10]</sup> They described a 39-year-old female who developed the tumor as a recurrence of a partially excised lacrimal gland tumor. A cystic oncocytoma was reported by Riedel<sup>[11]</sup> in 1983. There have been two reported cases of oncocytic carcinoma.<sup>[1,12]</sup>

Oncocytomas are well-circumscribed round or oval masses with smooth or lobular surface formed by large cells with eosinophilic granular cytoplasm<sup>[5]</sup> [Table 1].

This compares favorably with our own case. The tumor was well circumscribed and did not invade the orbit. Microscopy of the specimen revealed a tumor which comprised cords and sheets of round cells with abundant eosinophilic granular cytoplasm and uniform round vesicular nuclei.

The patient was female in her sixth decade of life. Other authors have reported the predilection of this rare tumor

for elderly females.<sup>[3,5,12]</sup>

Visual loss is not a common presentation of lacrimal gland tumors.

Loss of vision in this patient could have resulted from exposure keratopathy (from the proptosis, ectropion, and poor Bell's phenomenon), or from traditional eye medication or a combination of both factors.

In rural areas of developing countries, there is a tendency to seek orthodox therapy as a last resort.

Even though this patient had a proptosed blind eye, she resisted orthodox treatment until she was forced to do so by her more enlightened children.

## Conclusions

To our knowledge, this is the first reported case of lacrimal gland oncocytoma in Nigeria.

More cases may exist, but they may be lost to unorthodox medical practice.

Prospectively, it will be worthwhile to find out if lacrimal gland oncocytoma is as rare in individuals of African descent as it is in Caucasians.

**Table 1: List of reported cases of oxyphil cell tumors of the lacrimal gland to date**

Author	Date	Diagnosis	Sex	Age (years)	Comment
Beskid and Zarzycka <sup>[10]</sup>	1959	Oncocytoma	F	39	Recurrence from a partially excised lacrimal gland tumor
Riedel <sup>[11]</sup>	1983	Oncocytoma	F	76	Cystic oncocytoma
Hartman <sup>[13]</sup>	2003	Oncocytoma	M	72	Diagnosed by fine-needle aspiration. Treated by total excision. Diagnosis confirmed by histology. No recurrence after 18 months. Reduced postoperative visual acuity due to poor tear secretion
Calle <sup>[1]</sup>	2006	Oncocytoma	F	40	Partial resection was done. The patient had 6/6 vision in that eye and the extent of tumor precluded total excision without collateral damage. The patient has remained recurrence free after 22-month follow-up
Economou <sup>[14]</sup>	2007	Oncocytoma	M	68	Tumor showed weak-to-moderate immunoreactivity for S-100 while the immunoreactivity for the epithelial markers AEI/3 was more distinct. Poor tear secretion postoperatively
Archondakis et al. <sup>[2]</sup>	2009	Oncocytoma	M	83	Diagnosed by fine-needle aspiration. Treated by total excision. Diagnosis confirmed by histology. Authors want cytological criteria that distinguish benign from malignant oncocytoma as these may be confusing when cytology is done alone
Oncocytic carcinomas					
Dorello <sup>[1]</sup>	1961	Oncocytic carcinoma	M	59	Developed exophthalmos, diplopia, and intracranial extension; was treated by exenteration and radiation. Died 2 years postpresentation
Biggs and Font <sup>[12]</sup>	1977	Mucus secreting oncocytic adenocarcinoma	F	81	Out of a total of 18 rare oncocytomas of the ocular adnexa analyses, this was the only one involving the lacrimal gland; lost to follow-up
Riedel et al. <sup>[11]</sup>	1983	Oncocytic carcinoma	M	58	Presented with intracranial extension; died of liver metastasis 6 months later despite exenteration and radiation

## Acknowledgment

The authors thank Robert Eagle of the Department of Ocular Pathology, Wills Eye Hospital, Philadelphia, and Dr. Mario Economou, Department of Ophthalmic Pathology, St. Erik's Eye Hospital, Sweden, for their support.

## References

1. Calle CA, Castillo IG, Eagle RC, Daza MT. Oncocytoma of the lacrimal gland: Case report and review of the literature. *Orbit* 2006;25:243-7.
2. Archondakis S, Skagias L, Tsakiris A, Sambaziotis D, Daskalopoulou D. Oncocytoma of the lacrimal gland diagnosed initially by fine needle aspiration cytology. *Diagn Cytopathol* 2009;37:443-5.
3. Lamping KA, Alnert DM, Ni C, Fournier G. Oxyphil cell adenomas. 3 case reports. *Arch Ophthalmol* 1984;102:263-5.
4. Giarelli L, Melato M, Antonutto G. *Colour Atlas of Pathology*. London: Butterworth's; 1987. p. 13.
5. Juan Rosai. *Ackerman's Surgical Pathology*. 8th ed, vol.2. St Louis Missouri: Mosby; 1996. p. 2458.
6. Basic and Clinical Science Course. Section 7; Orbit, Eyelids and Lacrimal system. San Francisco; *Am Acad Ophthalmol*; 2004-2005. p .89.
7. Percorella I, Garner A. Ostensible oncocytoma of accessory lacrimal glands. *Histopathology* 1997;30:264-70.
8. Ohtsuka K, Hashimoto M, Suzuki Y. A review of 244 orbital tumours in Japanese patients during a 21 year period: Origins and locations. *Jpn J Ophthalmol* 2005;49:49-50.
9. Greer CH. Oxyphil cell adenoma of the lacrimal gland and caruncle, report of 2 cases. *Br J Ophthalmol* 1969;53:198-200.
10. Beskid M, Zarzycka M. A case of oncocytoma of the lacrimal gland. *Klin Oczna* 1959;29:311-5.
11. Reidel K, Stephani FH, Kampika. Oncocytoma of the ocular adnexa. *Klin Monotal Augenheilkd* 1983;182:544-8.
12. Biggs SL, Font RL. Oncocytotic lesions of the caruncle and other ocular adnexa. *Arch Ophthalmol* 1977;95:474-8.
13. Hartman LJ, Mounts MP, Canninga-van Dijk MR. An unusual tumour of the lacrimal gland. *Br J Ophthalmol* 2003;87:363.
14. Economou MA, Seregard S, Sahlin S. Oncocytoma of the lacrimal gland. *Acta Ophthalmol Scand* 2007;85:576-7.

**How to cite this article:** Aghaji AE, Olushina DB, Okoye OI. Oxyphil cell adenoma in a Nigerian: Case report and review of the literature. *Niger J Clin Pract* 2011;14:373-6.

**Source of Support:** Nil, **Conflict of Interest:** None declared.