

# Periapical granuloma associated with extracted teeth

FO Omoregie, MA Ojo, BDO Saheeb, O Odukoya<sup>1</sup>

Department of Oral and Maxillofacial Surgery and Pathology, School of Dentistry, College of Medical Sciences, University of Benin, Benin City, <sup>1</sup>Department of Oral Pathology, Dental Center, Lagos University Teaching Hospital, Lagos, Nigeria

## Abstract

**Objective:** This article aims to determine the incidence of periapical granuloma from extracted teeth and correlate the clinical diagnoses with the histopathological types of periapical granuloma.

**Patients and Methods:** Over a period of eight months, a prospective study designed as a routine biopsy of recoverable periapical tissues obtained from patients who had single tooth extraction was carried out.

**Results:** One hundred and thirty-six patients participated in the study, with 75 (55.1%) histopathologically diagnosed periradicular lesions. There were 23 (16.9%) cases of periapical granuloma, with a male to female ratio of 2: 1. The lesion presented mostly between the third and fourth decades of life ( $n=9$ , 6.6%). Clinically diagnosed acute apical periodontitis was significantly associated with periapical granuloma, with predominantly foamy macrophages and lymphocytes ( $P<0.05$ ).

**Conclusion:** Periapical granuloma appears to be a less common periapical lesion in this study compared to the previous reports. In contrast to reports that relate to an acute flare of the lesion with abundant neutrophilic infiltration, this study has shown marked foamy macrophages and lymphocytes at the acute phase, which are significantly associated with the clinical diagnosis of acute apical periodontitis. We recommend the classification of periapical granuloma into early, intermediate, and late stages of the lesion, based on the associated inflammatory cells.

**Key words:** Clinical diagnoses, histopathological types, periapical granuloma

**Date of Acceptance:** 21-Mar-2011

## Introduction

The most common periapical lesions are periapical granuloma, periapical cyst, and periapical abscess.<sup>[1,2]</sup> Periapical granuloma is a chronic inflammatory lesion at the apex of a non-vital tooth, consisting of granulation tissue and scar, infiltrated by variable numbers of chronic inflammatory cells (lymphocytes, plasma cells, mast cells, macrophages). This lesion is different from a granulomatous inflammation, with a predominance of macrophages (histiocytes) and multinucleated giant cells. During an acute flare of a periapical granuloma, there is abundant neutrophilic infiltration, in addition to granulation tissue and chronic inflammatory cells.<sup>[3-6]</sup>

Clinically diagnosed acute apical periodontitis may be diagnosed as an acutely exacerbated periapical granuloma, histologically,<sup>[3]</sup> while a periapical abscess at the quiescent phase may develop into a periapical granuloma.<sup>[7]</sup> Therefore, further studies that relate to histological types of periapical granuloma, with a clinical diagnosis of the lesion, may be useful for dental practitioners, to predict whether a clinically diagnosed periapical lesion could be periapical granuloma, a known sequelae of pulpal necrosis.<sup>[8]</sup> In addition, studies on the histopathological types of periapical granuloma may help modify the previous classification of the lesion.

### Address for correspondence:

Dr. F. O. Omoregie,  
Department of Oral and Maxillofacial Surgery and Pathology,  
School of Dentistry, College of Medical Sciences, University of  
Benin, Benin City, Nigeria.  
E-mail: omoregiefo@yahoo.com

### Access this article online

Quick Response Code:



Website: [www.njcponline.com](http://www.njcponline.com)

DOI: 10.4103/1119-3077.86770

PMID: 22037071

A Medline search and a review of the literature show no known study in our environment that correlates a clinically diagnosed periapical lesion with the histopathological type of periapical granuloma. This study aims to determine the incidence of periapical granuloma from the extracted teeth and correlate the clinical diagnoses with the histopathological types of periapical granuloma.

### Patients and Methods

This is a prospective study of over a period of eight months, from February to September 2005, involving patients who had single tooth extractions with routine histopathological examination of recoverable periradicular tissues from the extracted teeth, at the Department of Oral and Maxillofacial Surgery and Pathology, University of Benin Teaching Hospital, Benin City, Nigeria.

We obtained permission to carry out the study from the Medical Ethics Committee of the Hospital and took a written informed consent from the patients for biopsy of the specimen, for the study. The patients selected for the study were those who had clinically obvious or suspected periapical lesions involving non-vital teeth (using electric pulp tester), with preoperative periapical radiological changes. The study excluded patients who had endodontic surgical treatment with periapical tissues obtained during histological examination.

Tooth extraction was performed under local anesthesia, using either a forceps delivery or the transalveolar method. The extraction sockets were curetted to recover any retained periapical tissues for processing and staining with the Hematoxylin and Eosin (H and E) technique. The diagnosis of periapical granuloma was made after a histopathological examination, microscopically, under low (×10) and high power (×40) magnifications.

The data collected were patients' age, sex, clinical diagnoses, histopathological types (based on the type of inflammatory cell), and the stages of development of the periapical granuloma. Statistical testing was carried out to estimate the strength of the correlation (using Pearson's correlation coefficient) of the clinical diagnoses with the histopathological types of periapical granuloma. The confidence level regarded as significant was set at 95% and probability values (*P*-value) at *P*<0.05.

### Results

One hundred and thirty-six patients participated in the study, with 75 (55.1%) histopathologically diagnosed periradicular lesions [Table 1]. There were 23 (16.9%) cases of periapical (inflammatory) granuloma consisting of fifteen males and eight females, giving a male to female ratio of 2: 1. The lesion presented mostly between the third and

fourth decades of life (*n*=9, 6.6%) [Table 2].

The most common histopathological type of lesion consists of macrophages and lymphocytes (*n*=19, 14.7%) [Table 3]. The histological stages of development of the lesion demonstrated include early [Figure 1], intermediate [Figure 2], and late [Figure 3] stages.

Correlation of the seven different clinical diagnoses of the periapical lesions with the histopathological types of periapical granuloma, showed a significant association of acute apical periodontitis with periapical granuloma, consisting predominantly of foamy macrophages and lymphocytes (*P*<0.05) [Table 2, Figure 1].

### Discussion

The periapical (inflammatory) granuloma studied, presented mostly among adult males, which represented less than a fifth of the periapical lesions (16.9%). This contradicts the

**Table 1: Types of the histopathologically diagnosed periradicular lesions**

Histopathologic diagnosis	Frequency	%
Periapical abscess	30	22.1
Periapical granuloma	23	16.9
Periapical cyst	2	1.5
Chronic osteomyelitis	2	1.5
Pulse granuloma	1	0.7
Fibroepithelial hyperplasia	1	0.7
Periapical cemental dysplasia	3	2.2
Ossifying fibroma	2	1.5
Odontogenic fibroma	1	0.7
Central giant cell granuloma	3	2.2
Granular cell tumour	1	0.7
Adenolymphoma	1	0.7
Intraosseous naevi	1	0.7
Squamous cell carcinoma	1	0.7
Burkitt's lymphoma	2	1.5
Non-Hodgkin's lymphoma	1	1.5
Total	75	55.1

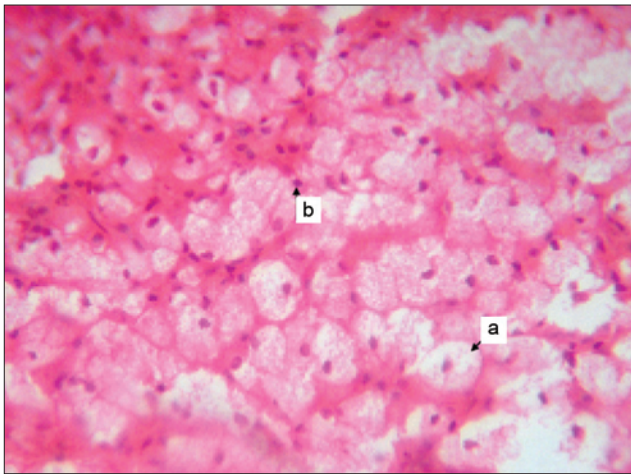
**Table 2: Age and sex distribution of the periapical granuloma**

Age (Years)	Male	Female	frequency	%
0 – 10	3	-	3	2.2
11 – 20	2	1	3	2.2
21 – 30	5	-	5	3.7
31 – 40	2	2	4	3.0
41 – 50	1	2	3	2.2
51 – 60	2	1	3	2.2
61 – 70	-	1	1	0.7
> 70	-	1	1	0.7
Total	15	8	23	16.9

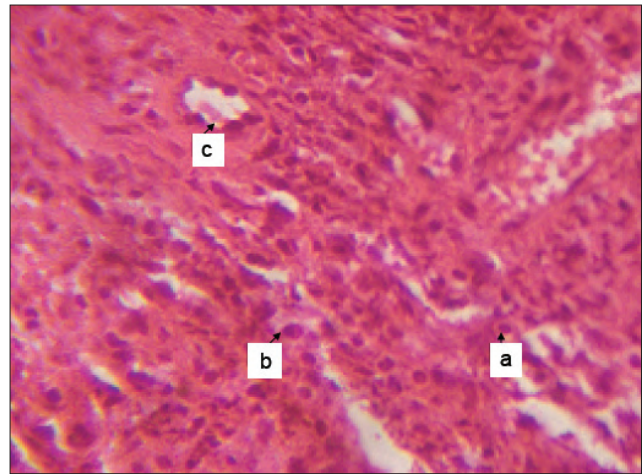
**Table 3: Correlation of clinical diagnoses with histopathologic types of the periapical granuloma**

Clinical diagnosis	Histopathologic types			Frequency	%
	LMN	LM	LMP		
Dentoalveolar abscess	-	5	-	5	3.7
Acute apical periodontitis	1	8	1	10	7.4
Pathological fracture	-	-	1	1	0.7
Chronic apical periodontitis	-	3	-	3	3.7
Retained deciduous tooth	-	1	-	1	0.7
Periapical cyst	-	1	-	1	0.7
Lateral periodontal abscess	-	1	1	2	0.7
Total	1	19	3	23	16.9

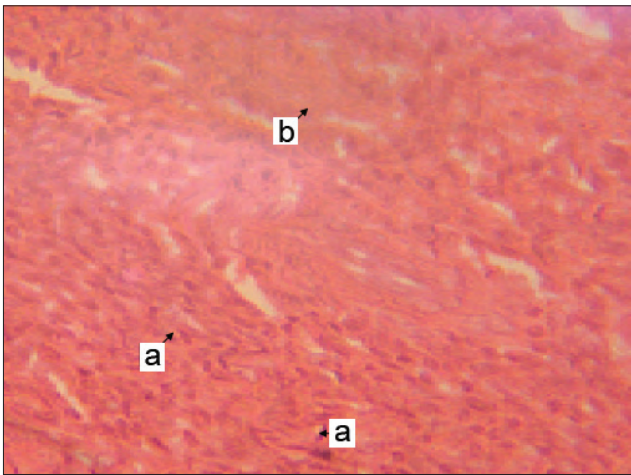
LMN = Lymphocyte, macrophage and neutrophil; LM = Lymphocyte and macrophage; LMP = Lymphocyte, macrophage and plasma cell



**Figure 1:** Early stage of periapical granuloma with predominantly foamy macrophages (a) and lymphocytes (b) [H and E, ×40]



**Figure 2:** Intermediate stage of periapical granuloma with prominent lymphocytes (a), plasma cells (b) and blood vessels (c) [H and E, ×40]



**Figure 3:** Late stage of periapical granuloma with prominent fibroblasts (a) in hemosiderin pigmented fibrotic stroma (b) [H and E, ×40]

report of a high incidence of periapical granuloma from the previous studies.<sup>[1]</sup> Perhaps, the exclusion of patients who had endodontic surgical treatment from this study might be the reason for the lower incidence of the lesion. However, this study suggested a higher tendency for delayed

presentation of cases of periapical granuloma, for treatment among adult male subjects, until there was an acute flare of the lesion.

In this study, we observed a significant correlation of the clinical diagnosis of acute apical periodontitis with the histopathological diagnosis of periapical granuloma, consisting mainly of foamy macrophages and lymphocytes. This finding is in contrast to the previous reports that relate an acute flare of periapical granuloma with marked neutrophilic infiltration, in addition to chronic inflammatory cell infiltration within the granulation tissue.<sup>[3-6]</sup> However, the study suggests a higher possibility of the histopathological diagnosis of an acute flare of a periapical granuloma, when a periapical lesion presents clinically to the dentist as acute apical periodontitis, while the clinical diagnosis of an abscess in the periradicular region rarely signifies an acute flare of a periapical granuloma.

We have classified the histological types of the periapical granuloma into early, intermediate, and late stages based on

the associated inflammatory cells. A majority of the periapical granuloma in this study were early-stage lesions. The early stage has inflammatory edema (exudates), with marked infiltration by macrophages, with foamy (pale) cytoplasm, with or without neutrophils, and a few lymphocytes [Figure 1]. Other chronic inflammatory cells infiltrate the lesion shortly after. These findings are similar to what Shafer *et al*,<sup>[9]</sup> described as acute phase, with hyperemia, edema, and chronic inflammatory cell (predominantly macrophages) infiltration of the periodontal ligament.

At the intermediate stage, other chronic inflammatory cells such as lymphocytes and plasma cells predominate, with numerous blood vessels [Figure 2]. These features are similar to those reportedly associated with the chronic form of the lesion.<sup>[5,6]</sup> In addition, the findings at the intermediate stage are consistent with what Shafer *et al*,<sup>[9]</sup> described as the stage of increased vascularity, with resorption of the root apex and supporting adjacent bone.

The late or healing stage shows fewer chronic inflammatory cells and blood vessels, with prominent fibroblasts and hemosiderin granules within a fibrous connective tissue stroma [Figure 3].<sup>[3]</sup> This appears similar to what Stern *et al*,<sup>[10]</sup> described as a stage of periapical granuloma with proliferation of fibroblasts and endothelial cells, resulting in the formation of tiny vascular channels and numerous delicate connective tissue fibrils, with predominant infiltration by macrophages, lymphocytes, and plasma cells.

A classification subdivides periapical granuloma into immune and non-immune granuloma.<sup>[9,11,12]</sup> The immune granuloma has marked infiltrates of chronic inflammatory cells consisting mainly of lymphocytes and plasma cells. The non-immune granuloma consists mainly of macrophages and giant cells, with plasma cells rarely found in the lesion. However, this classification fails to take into consideration that macrophages are also immune cells. Their presence during the acute or early stage of the lesion suggests an early immune response, in which they act as scavenger cells that mop up the exudates and act as 'mop up the exudates and act as antigen presenting cells' to other immune cells.

In conclusion, periapical granuloma appears to be a less

common periapical lesion in this study compared to previous reports.<sup>[1,2]</sup> In contrast to reports<sup>[3-6,13]</sup> that relate an acute flare of the lesion with abundant neutrophilic infiltration, this study shows marked foamy macrophages and lymphocytes at the acute phase, which is significantly associated with a clinical diagnosis of acute apical periodontitis. We recommend the classification of periapical granuloma into early, intermediate, and late (healing) stages of the lesion, based on the associated inflammatory cells.

## References

1. Peters E, Monica L. Histopathologic examination to confirm diagnosis of periapical lesions: A review. *J Can Dent Assoc* 2003;69:598-600.
2. Gbolahan O, Fatusi O, Owotade F, Akinwande J, Adebiji K. Clinicopathology of soft tissue lesions associated with extracted teeth. *J Oral Maxillofac Surg* 2008;66:2284-9.
3. Regezi JA, Sciubba JJ. *Oral Pathology: Clinical Pathologic Correlations*. 3<sup>rd</sup> ed. Philadelphia, New York: W. B Saunders Company; 1999. p. 384-6.
4. Ledesma-Montes C, Garces-Ortiz M, Rosales-Garcia G, Hernandez-Guerrero JC. Importance of mast cells in human periapical inflammatory lesions. *J Endod* 2004;30:855-9.
5. Liapatas S, Nakou M, Rontogianni D. Inflammatory infiltrate of chronic periradicular lesions: An immunohistochemical study. *Int Endod J* 2003; 36:464-71.
6. Gasparoni A, Regoli M, Della Casa M, Fonzi M, Fonzi L. Immunological and ultrastructural characterization of plasma cells of human periapical chronic inflammatory lesions (granulomas). *Ital J Anat Embryol* 2005;110:1-9.
7. Neville BW, Damm DD, Allen CM. *Oral and Maxillofacial Pathology*. 1<sup>st</sup> ed. Philadelphia, New York, USA: W.B Saunders Company; 1995. p. 103.
8. Kuc I, Peters E, Pan J. Comparison of clinical and histologic diagnoses in periapical lesions. *Oral Surg Oral Med Oral Pathol Oral Radiol Endod* 2000;89:333-7.
9. Shafer WG, Hine MK, Levy BM. *A textbook of Oral Pathology*. 4<sup>th</sup> ed. Philadelphia, New York: W.B. Saunders Company; 1983. p. 486-2.
10. Stern MH, Dreizen S, Mackler BF, Selbst AG, Levy BM. Quantitative analysis of cellular composition of human periapical granuloma. *J Endod* 1981;7:117-22.
11. Athanassiades TJ, Spear RS. Granuloma induction in peritoneal cavity: A model for the study of inflammation and cytopoiesis in non-lymphatic organs. *J Reticuloendothelial Soc* 1972;11:60-76.
12. Page RC, Davies P, Allison AC. Pathogenesis of chronic inflammatory lesion induced by Group A streptococcal cell walls. *Lab Invest* 1974;30:568-81.
13. Omoregie FO, Saheeb BD, Odukoya O, Ojo MA. A clinicopathologic correlation in the diagnosis of periradicular lesions of extracted teeth. *J Oral Maxillofac Surg* 2009;67:1387-91.

**How to cite this article:** Omoregie FO, Ojo MA, Saheeb B, Odukoya O. Periapical granuloma associated with extracted teeth. *Niger J Clin Pract* 2011;14:293-6.

**Source of Support:** Nil, **Conflict of Interest:** None declared.

### Announcement

#### iPhone App



Download  
iPhone, iPad  
application

FREE

A free application to browse and search the journal's content is now available for iPhone/iPad. The application provides "Table of Contents" of the latest issues, which are stored on the device for future offline browsing. Internet connection is required to access the back issues and search facility. The application is Compatible with iPhone, iPod touch, and iPad and Requires iOS 3.1 or later. The application can be downloaded from <http://itunes.apple.com/us/app/medknow-journals/id458064375?ls=1&mt=8>. For suggestions and comments do write back to us.