

Neck masses in children: Etiopathology in a tertiary center

OD Osifo, EE Ugiagbe¹

Department of Surgery, Paediatric Surgery Unit and ¹ Department of Morbid Anatomy, University of Benin Teaching Hospital, Benin City, Nigeria

Abstract

Background: Neck masses are common in children; they could present diagnostic challenges, and some may be malignant. This study determines the etiology, histopathology, and outcome of treatment in a Nigerian tertiary center.

Materials and Methods: This is a three-year retrospective study of children managed with neck masses at the University of Benin Teaching Hospital between January 2007 and December 2009. The biodata, side distribution of the masses, clinical conditions of the children at presentation, methods of biopsy, histopathology results, definitive treatment options, follow-up, and outcome were analyzed.

Results: A total of 35 children who were aged between one month and 16 years (mean, 8.1 ± 2.6 years) with a male : female ratio of 1.9 : 1 (23 males to 12 females) were managed with 26 (74.3%) acquired and nine (25.7%) congenital neck masses. The masses were located in the anterior triangle in 14 (40%) cases, right side of the neck in 12 (34.3%), and left side of the neck in seven (20%), with two (5.7%) bilateral/confluent. Twelve (34.3%) cases were enlarged lymph nodes; five (41.7%) of them due to malignant lesions. Except for the neck mass, 16 (45.7%) of the children enjoyed clinically stable health on presentation. Twenty (57.1%) acquired tumors were malignant compared with 15 (42.9%) mainly congenital tumors which were benign. Four malignant tumors (11.4%) were rare in anterior triangle. Hodgkin's lymphoma, 9 (25.7%), and thyroglossal duct cyst, 5 (14.3%), were most common malignant and nonmalignant masses, respectively. Surgical excision was curative in 12 (34.3%) cases, but others required additional chemo and/or radiotherapy, with two (5.7%) mortality recorded due to late referral of children with Hodgkin's lymphoma.

Conclusions: Many neck masses in otherwise healthy children in our setting were malignant. We advocate early surgical consultation and thorough histopathologic analysis of neck masses in children in our subregion.

Key words: Etiopathology, children, neck masses, outcome

Date of Acceptance: 15-Feb-2011

Introduction

Neck masses in infants and children are common worldwide and constitute a major indication for surgical consultation in many pediatric surgical centers.^[1,2] The etiology varies from benign/congenital lesions which may be present at birth to acquired/neoplastic lesions which may manifest in late childhood.^[1-5] Neoplastic and nonneoplastic tumors could involve the whole neck or may present as a small lump located to a triangle of the neck. The conspicuous location and the

frequently associated cosmetic problem create anxiety for both parents and family physicians, which often result in early presentation.^[1,2] In many tumors, however, symptoms and signs depend on the location, systemic effects of the etiopathology, and compression of important structures in the neck.^[6-8]

Neck masses could occasionally present diagnostic challenge in many resource-poor centers where affected children often

Address for correspondence:

Dr. Osarumwense David Osifo,
Department of Surgery, Paediatric Surgery Unit,
University of Benin Teaching Hospital,
Benin City, Nigeria.
E-mail: leadekso@yahoo.com

Access this article online

Quick Response Code:



Website: www.njcponline.com

DOI: 10.4103/1119-3077

PMID: 21860146

present late and there may be a lack of sophisticated imaging facilities required for prompt and precise diagnosis.^[9,10] Consequently, although clinical assessment may result in straightforward diagnosis in many cases, histopathologic analysis of neck masses remains an important step in managing affected children even in centers with advanced diagnostic tools.^[7,11] Current information on the relative frequency of etiology and histopathologic analysis of infancy and childhood neck masses which may influence early institution of appropriate treatments are scant in this African subregion.^[11,12]

In this study, we undertook a retrospective analysis of infants and children managed with neck masses over three years to determine the etiopathology and outcome of treatment.

Materials and Methods

This is a three-year retrospective study on neck masses in infants and children undertaken at the University of Benin Teaching Hospital between January 2007 and December 2009. During the period, the diagnostic evaluation protocol for neck masses included hematological, blood chemistry, and radiological assessments as well as obtaining tissue for histopathological analysis. The case files of 35 of 37 affected children managed during the period were retrieved from Medical Records Department. Thereafter, the biodata, side distribution of the masses, clinical conditions of the children at presentation, methods of biopsy, histopathology results, definitive treatment options, follow-up, and outcome were analyzed. In addition, clinical information was corroborated with request cards and the surgical day books of Pathology Department. Slides were also retrieved from the archives of the Pathology Department and when necessary, new slides were made from formalin-fixed and/or paraffin-embedded blocks. Children with acute inflammation of the neck and incomplete records were excluded from the study.

Statistical analysis

The data collated were entered into Microsoft Office Excel 2007 sheet and analyzed as counts, frequency, and percentages, while continuous data were expressed as mean/standard deviation. The results are presented in simple Tables and Figures.

Results

A total of 35 children who were aged between one month and 16 years (mean, 8.1 ± 2.6 years) with a male : female ratio of 1.9 : 1 (23 males to 12 females) were managed with 26 (74.3%) acquired and nine (25.7%) congenital neck masses. As shown in Table 1, 14 (40%) children had their masses located in the anterior triangle of the neck, 12 (34.3%) on right, and seven (20%) on the left. Bilateral/confluent mass was diagnosed in two (5.7%) children, including a child with

superimposed infection of cystic hygroma who presented with features of respiratory obstruction [Figure 1].

Except for the neck mass, 16 (45.7%) of the children enjoyed clinically stable health on presentation, but 15 (42.9%) were chronically ill and four (11.4%) were severely compromised clinically. Anorexia, weight loss, failure to thrive, anemia, and extensive scarifications of the mass by traditional healers were other presenting features in many children, especially those with malignant neck mass. Only 7 (20%) of the children who were at the early stages of the disease presented directly to the study center within the first week of noticing the neck mass. On the other hand, 13 (37.1%) were referred from private clinic, while 15 (42.9%) came from traditional and spiritual clinics after failure of response to treatment. This resulted in late presentation and advanced diseases in these children despite early detection of the mass.

Surgical excision alone was curative in 12 (34.3%) masses, while the others required additional chemotherapy and/or radiotherapy. Successful single-stage surgical excision was achieved in nine (25.7%) of the masses, while 15 (42.9%) required multiple excision due to recurrence and incomplete primary excision. On the other hand, incisional biopsy alone was possible in eight (22.9%) cases, while fine needle aspiration biopsy was done in three (8.5%). Children with lymphangioma (cystic hygroma) who presented with respiratory compromise due to superimposed infection and huge confluent mass

Table 1: Correlation between side distribution and histological diagnosis

Variables	Malignant (%)	Benign (%)	Total (%)
Anterior	4	10	14 (40)
Right	9	3	12 (34.3)
Left	7	0	7 (20)
Bilateral/ confluent	0	2	2 (5.7)
Total	20 (57.1)	15 (42.9)	35 (100)

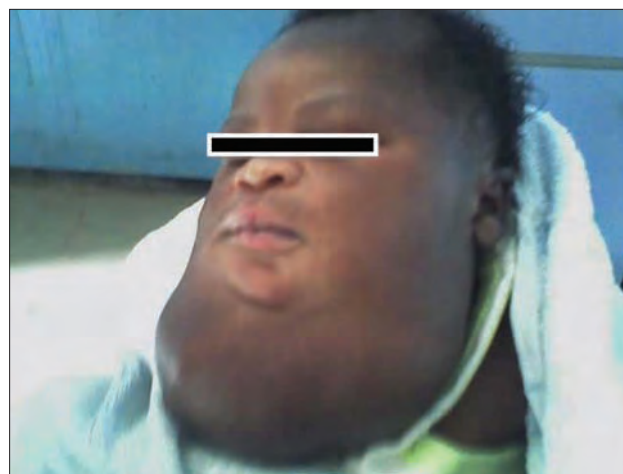

Figure 1: A 3-month-old male baby with infected cystic hygroma involving the whole neck with features of respiratory obstruction

had initial incision and drainage/antibiotics and repeated aspiration, respectively, before definitive surgical excision was undertaken. Sistrunk's operation gave excellent outcome in those with thyroglossal duct cyst, while additional combination antituberculous chemotherapy was used in those with tuberculous lymphadenopathy.

Of the entire specimens sent for histopathologic analysis, 20 (57.1%) were reported as malignant compared with 15 (42.9%) nonmalignant lesions. Malignant and nonmalignant tumors had equal sex distribution, but the incidence of malignant tumor increased with the age at which neck mass appeared in the children. The duration of neck mass before presentation did not, however, increase the incidence of malignant neck mass. Anterior triangle neck masses were mainly nonmalignant, 10 (28.6%), compared with four (11.4%) malignant submandibular/submental lymphadenopathy. There was, however, a near equal distribution between nine (25.7%) right and seven (20%) left malignant lesions [Table 1]. Twelve (34.3%) of the masses were clinically diagnosed and histologically confirmed to be lymph nodes. Of the 12 lymph nodes, three each were reported as tuberculous lymphadenitis and Hodgkin's lymphoma, respectively. Two were reactive hyperplasia, while one each was Kaposi's sarcoma, chronic granulomatous lesion, metastatic carcinoma, and granulomatous sialadenitis.

Of the 20 malignant neck masses, Hodgkin's lymphoma accounted for nine (25.7%), while Burkitt's lymphoma accounted for five (14.3%). Others which accounted for two (5.7%) each were rare, as shown in Figure 2. Tuberculous lymphadenitis was only diagnosed in lateral neck swellings. There was a near even distribution of nonmalignant lesions as thyroglossal duct cyst which was most common accounted for five (14.3%), lymphangioma for four (11.4%), and reactive hyperplasia and tuberculous lymphadenitis accounted for three (8.5%) each [Figure 3]. Except those children in poor clinical condition before surgery, immediate postoperative conditions were uneventful. On follow-up, as depicted in Table 2, children with nonmalignant lesions were cured with no mortality recorded, but two

with lymphangioma had residual neck deformity which improved on physiotherapy. On the other hand, although surgery, chemotherapy, and/or radiotherapy were used in the management of malignant lesions, two (5.7%) children with Hodgkin's lymphoma succumbed to the illness because they presented very late, and three (8.6%) had residual deformity which also improved on physiotherapy.

Discussion

In this study, the majority of neck masses (74.3%) were due to acquired causes which corresponded with earlier studies^[4,5] in which congenital causes were reported to

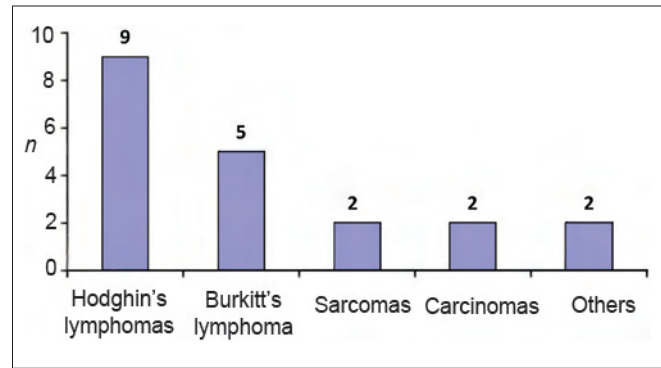


Figure 2: Histologic diagnosis of malignant neck masses

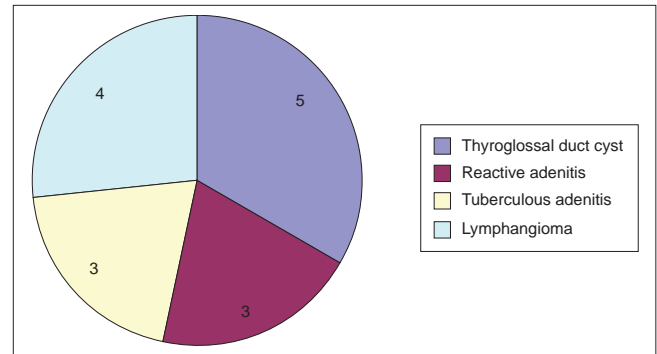


Figure 3: Histologic diagnosis of Benign neck masses

Table 2: The diagnosis, treatment, and outcome of neck masses				
Diagnosis	Frequency	Percent	Treatment	Outcome
Malignant				
Hodgkin's lymphoma	9	25.7	Biopsy, excision, radio/chemotherapy, physiotherapy	2 died, 3 residual deformity, 4 excellent outcome
Burkitt's lymphoma	5	14.3	Biopsy, chemotherapy	All cured, excellent outcome
Sarcomas	2	5.7	Excision biopsy, chemotherapy	All cured, excellent outcome
Carcinomas	2	5.7	Biopsy, chemotherapy	All cured, excellent outcome
Others	2	5.7	Biopsy, chemotherapy	All cured, excellent outcome
Non-malignant				
Thyroglossal cyst	5	14.3	Sistrunk's operation	All cured, excellent outcome
Reactive adenitis	4	11.4	Biopsy, antibiotics	All cured, excellent outcome
TB adenitis	3	8.6	Biopsy/anti-TB chemotherapy	All cured, excellent outcome
Lymphangioma	3	8.6	Excision/physiotherapy	2 minor neck deformity, all cured

account for between 12 and 22% of cases. However, unlike other studies^[13,14] in which many neck masses were benign, more than half (57.1%) of cases were malignant and resulted in the 5.7% overall mortality recorded due to late presentation in this series. The sex of the patients did not significantly influence incidences of congenital or acquired neck masses diagnosed during the period. However, the incidence of malignant neck masses increased with the age of development of acquired neck masses, which was similar to reports by other authors.^[12-14] Malignant and tuberculous lesions were diagnosed mainly in lateral neck masses, with a near equal distribution between right- and left-side involvement. Only 11.4% anterior triangle masses were confirmed to be malignant lymphadenopathy on histopathologic analysis.^[12-15]

About half of the children (45.7%) were clinically stable at presentation, with cosmetic problem and the fears of malignant tumor as the indications for surgical consultation of some children. Despite obvious location of the masses, anorexia, weight loss, failure to thrive, and anemia had supervened in many children and were the indications for seeking surgical consultation in many cases, as also reported by others.^[12,14] Also, ignorance and religious beliefs played significant role in influencing late presentation as a large proportion of children presented only after failed response to traditional and spiritual remedy unlike what obtains in other regions.^[11,2] Consequently, only 20% of the children in this review presented directly to the study center within the first week of noticing the neck mass.^[12,14] The use of scarification and application of native concoction remain common modality of treatment of many ailments by African traditional healers. Prior employment of this modality of treatment was obvious in these children as extensive scarification marks were present on arrival in many children, especially those with malignant neck masses.

Moreover, late presentation resulted in 42.9% cases arriving chronically ill, with 11.4% in terminal stages of the diseases which corresponded with earlier observations in this African subregion.^[5,12,14] Also, repeated excision due to recurrence and incomplete primary tumor excision and the additional use of combination chemo and/or radiotherapy were necessary in the management of malignant cases.^[1,12,14] However, late presentation, the dangers of injury to vital structures in the neck, especially in those with recurrent masses, and cosmetic consideration influenced carrying out only palliative treatment, less-invasive biopsy such as incisional biopsy and fine needle aspiration biopsy in some cases, which were similar to the experiences of others authors.^[2,13,15]

The commonest nonmalignant neck masses in this study were thyroglossal duct cyst which accounted for 14.3% and lymphangioma which accounted for 11.4%. This finding corresponded with the reports of earlier authors.^[4,5] Although late presentation also affected children with

nonmalignant neck masses in this series, children with cystic hygroma, including a child with superimposed infection of a huge confluent mass did well on initial incision and drainage, aspiration, use of broad-spectrum antibiotics, and a definitive surgical excision, even though many cases required multiple excision due to incomplete primary excision. Similarly, Sistrunk's operation and additional combination antituberculous chemotherapy gave excellent outcome in those with thyroglossal duct cyst and tuberculous lymphadenopathy, respectively, as reported in earlier studies.^[1-5] The place of physiotherapy in managing both malignant and nonmalignant neck masses, especially following surgical excision, cannot be overemphasized. In present review, all the residual postoperative neck deformity responded to physiotherapy, with significant improvement during follow-up. This is similar to earlier reports in which physiotherapy and reassurance of parents resulted in favorable outcome of postoperative neck deformity.^[2,4,5,8,13-15]

Cervical lymphadenopathy accounted for 34.3% of the neck masses which was similar to what was also reported by others.^[1,2,12-15] On histopathologic analysis, however, tumors of cervical lymph nodes in this review were found to be due mainly to tuberculous lymphadenitis and Hodgkin's lymphoma, with a few cases due to reactive hyperplasia, Kaposi's sarcoma, chronic granulomatous lesion, metastatic carcinoma, and granulomatous sialadenitis, unlike in other reports.^[3,16] Hodgkin's lymphoma (25.7%) and Burkitt's lymphoma (14.3%) were the commonest malignant cervical masses in this series which tallied with findings in other studies.^[12-15] Despite late presentation, all the children with Burkitt's lymphoma survived in this series, unlike those with Hodgkin's lymphoma of whom two succumbed to the illness during treatment, which was similar to earlier reports in this subregion.^[17-20]

The majority of neck masses were acquired with many of them due to unsuspected malignant lesions in otherwise healthy children. Despite the late presentation of many children with the majority in advanced stages of the diseases, timely determination of histopathology influenced the prompt choices of definitive treatments which resulted in encouraging outcome. We recommend the need for public enlightenment campaign that will result in early referral of children with neck masses by parents/caregivers, traditional and spiritual healers, general practitioners, family physicians, and pediatricians for surgical consultation in this subregion. Efforts should be made to subject all neck masses to histopathologic analysis as many of them in otherwise healthy children may be due to malignant lesions.

References

1. Turkington JR, Paterson A, Sweeney LE, Thornbury GD. Neck masses in children. *Br J Radiol* 2005;78:75-85.
2. Tracy TF, Muratore. Management of common head and neck masses. *Semin Pediatr Surg* 2007;16:3-13.
3. Maharjan M, Hirachan S, Kafle PK, Bista M, Shrestha S, Toran KC, et al. Incidence

- of tuberculosis in enlarged neck nodes, our experience. *Kathmadu Univ Med J* 2009;7:54-8.
4. Al-Khateeb TH, Al Zoubi F. Congenital neck masses: A descriptive retrospective study of 252 cases. *J Oral Maxillofac Surg* 2007;65:2242-7.
 5. Ayugi JW, Ogeng'o JA, Macharia IM. Pattern of congenital neck masses in a Kenya paediatric population. *Int J Pediatr Otorhinolaryngol* 2010;74:64-6.
 6. Imhof H, Czerny C, Hormann M, Krestan C. Tumors and tumor-like lesions of the neck: From childhood to adult. *Eur Radiol* 2004;14:L155-65.
 7. Hsieh YY, Hsueh S, Hsueh C, Lin JN, Luo CC, Lai JY, et al. Pathological analysis of congenital cervical cysts in children: 20 years of experience at Chang Gung Memorial Hospital. *Chang Gung Med J* 2003;26:107-13.
 8. Turkyilmaz Z, Karabulut R, Bayazit YA, Sonmez K, Koybasioglu A, Yilmaz M, et al. Congenital neck masses in children and their embryologic and clinical features. *B-ENT* 2008;4:7-18.
 9. Malik A, Odita J, Rodriguez J, Hardjasudarma M. Pediatric neck masses: A pictorial review for practicing radiologists. *Curr Probl Diagn Radiol* 2002;31:146-57.
 10. Bhatia KS, Rasalkar DD, Lee YP, Wong KT, King AD, Yuen YH, et al. Real-time qualitative ultrasound elastography of miscellaneous non-nodal neck masses: Applications and limitations. *Ultrasound Med Biol* 2010;36:1644-52.
 11. Mueller JS, Schultenover S, Simpson J, Ely K, Netterville J. Value of rapid assessment cytology in the surgical management of head and neck tumors in a Nigerian mission hospital. *Head Neck* 2008;30:1083-5.
 12. Adeyemi BF, Adekunle LY, Kolude BM, Akang EE, Lawoyin JO. Head and neck cancer: A clinicopathological study in a tertiary care center. *J Natl Med Assoc* 2008;100:690-7.
 13. Sengupta S, Pal R, Saha S, Bera SP, Pai I, Tuli IP. Spectrum of head and neck cancer in children. *J Indian Assoc Pediatr Surg* 2009;14:200-3.
 14. Amusa YB, Olabanji JK, Akinpelu VO, Olatuju SO, Agbakwuru EA, Ndukwe N, et al. Pattern of head and neck malignant tumours in a Nigerian teaching hospital: A ten year review. *West Afr J Med* 2004;23:280-5.
 15. Chadha NK, Forte V. Pediatric head and neck masses malignancies. *Curr Opin Otolaryngol Head Neck Surg* 2009;17:471-6.
 16. Sayn I, Biskin S, Cakabay TT, Yazici ZM, Meric A, Kayhan FT. Tuberculous lymphadenitis. *Kulak Burun Bogaz Ihtis Derg* 2010;20:184-90.
 17. Amusa YB, Adeniran IA, Akinpelu VO, Famurewa OC, Olateju SO, Adegbehingbe BO, et al. Burkitt's lymphoma of the head and neck region in a Nigerian tertiary hospital. *West Afr J Med* 2005;24:139-42.
 18. Adeyemi BF, Kolude BM, Ogun GO, Akang EE. Paediatric head and neck malignancies in Ibadan, Nigeria. *Afr J Med Sci* 2009;38:55-62.
 19. Ologe FE, Adeniji KA, Segun-Busari S. Clinicopathological study of head and neck cancers in Ilorin, Nigeria. *Trop Doct* 2005;35:2-4.
 20. Agboola AO, Adekambi FA, Musa AA, Sotimehin AS, Deji-Agboola AM, Shomubi AM, et al. Pattern of childhood malignant tumours in a teaching hospital in south-western Nigeria. *Med J Aust* 2009;190:12-4.

How to cite this article: Osifo OD, Ugiagbe EE. Neck masses in children: Etiopathology in a tertiary center. *Niger J Clin Pract* 2011;14:232-6.

Source of Support: Nil, **Conflict of Interest:** None declared.