

COMPARING THE LEVEL OF CD₄ T LYMPHOCYTES, TO PULMONARY FEATURES OF TUBERCULOSIS IN HIV PATIENTS IN A LOCAL HOSPITAL

TT Marchie, OT Akhigbe

Department of Radiology, University of Benin Teaching Hospital, Benin Nigeria

ABSTRACT

Aim: This study is to assess the effect of CD₄ T lymphocytes, on features of pulmonary tuberculosis on HIV positive patients with co-existing tuberculosis attending clinic in university of Benin Teaching Hospital Benin Nigeria.

Setting: University of Benin Teaching Hospital Benin, Nigeria.

Method: This study was carried out on 200 patients who had laboratory confirmation of HIV, CD₄ T lymphocytes measured, with tuberculosis co-infection, and control group of 100 patients, who were HIV negative, but positive for tuberculosis infection, between 1st July, 2003 and 30th May, 2004, were further examined with chest radiography, in the hospital. The standard procedures of chest radiography were used, with minor adjustment to allow good image quality on the radiograph. Two Radiologists analyzed these on standard image viewing box.

Results: The average CD₄ T lymphocyte count in the study group (HIV sero-positive) was 173.90 cells/nl and median of 172 cells/nl. 128(64%) subjects had CD₄ T lymphocyte counts less than 200cell/nl while 72(36%) subjects had CD₄ lymphocyte count above or equal to 200 cells/nl. 111(86.72%) subjects with a CD₄ T lymphocyte count less than 200 cells/nl and 31(43.1%) subjects with CD₄ T lymphocyte count 200cells/nl or more had an atypical chest radiographic pattern of primary pulmonary tuberculosis. Atypical chest radiographic pattern was more frequent among patients with CD₄ T lymphocyte count less than 200 cell/nl (86.72%) compared with patients with CD₄ T lymphocyte count greater than 200cells/nl (43.1%) (P<0.001).

Conclusion: There is significant relationship and correlation between immune status of HIV positive patient and pulmonary pattern of tuberculosis. The variation on pulmonary pattern of tuberculosis noted also collaborated well with the level of CD₄ T lymphocyte in the patients.

Key Words: Human immune-deficiency virus (HIV), Tuberculosis (TB), CD₄ T Lymphocytes.

(Accepted 9 June 2009)

INTRODUCTION

HIV and tuberculosis are regarded as a socioeconomic disease and are commonly found in the environment in which this study was conducted.

A lot of studies had shown strong relationship between HIV and tuberculosis especially among the underprivileged and in many African societies where both diseases are considered highly endemic^{1,2}

The World Health organization estimates that of nearly five million people in the world who are co-infected with TB and HIV, three quarter are in Africa². HIV has contributed to increase in the global incidence and mortality from tuberculosis.

CD₄ T lymphocyte is a subgroup of T lymphocyte which are involve in immune response to viral infection particularly HIV. The degree of immunosuppression in HIV infected patients is

assessed by determining the level of CD₄ T lymphocyte in the patient blood. Hence the level CD₄ T Lymphocytes suggest the immune state of HIV patients, therefore could determine the trend and pattern of chest manifestations of opportunistic infection^{3,4,5}. There are two main ways in our hospital to assess CD₄ count, this include the manual CD₄ count, and automated CD₄ count using the patient's blood.

There is paucity of reports on HIV coexisting with tuberculosis and the effect on the progression of the disease which has not been adequately evaluated in the environment of this study. Considering its endemic incidence, there is a need to undertake a prospective study to compare the Level of CD₄ T lymphocytes to the pulmonary features of tuberculosis on chest radiograph in HIV Patients co-existing with tuberculosis in the local hospital.

In this study typical pulmonary manifestation of tuberculosis refers to post primary tuberculosis

Correspondence: Dr TT Marchie
E-Mail: tmarchie2000@yahoo.com

which consists of consolidation, cavitations, fibrosis and apical location of lesions. While atypical pulmonary manifestations of tuberculosis are referred as manifestation of primary tuberculosis consisting of broncho-pulmonary infiltrates, miliary pulmonary infiltrates lymphadenopathy and pleural effusion.

Lawn et-al⁶ has shown radiographic features of tuberculosis suggesting less broncho-pulmonary spread (27.9% vs. 58.5%) in HIV positive compare to HIV negative in selected West African patients. These radiographic findings are not in line with the expected pattern but may be as a result of the immune competence of the individual patient. These radiographic findings will be further analyzed in this study.

HIV being a highly immuno-compromising condition may take the pattern of the pulmonary features of tuberculosis as seen in non-immune patients that present as primary tuberculosis. But in the case of HIV infected patients the tuberculous infection is due to re-infection or reactivation of dormant foci. The tuberculous spread may take the forms of the haematogenous spread (as seen as miliary lung parenchyma changes) and broncho-pulmonary spread (as seen as broncho-pulmonary infiltrates). Post-primary pulmonary tuberculous lesion seen in immune patient presents as localized apical consolidation, fibrosis and cavitory destruction^{6,7}.

Comparing the level of CD4 T lymphocyte, which suggests the level of HIV infected patients' immunity, to the pulmonary pattern of tuberculosis on chest radiograph will help clarify the reasons behind the appearances of atypical and typical pulmonary features of tuberculosis seen in HIV positive coexisting with tuberculosis. This has been also noted in some literatures^{6,7}.

There has been a confusing scenario in assessing the pulmonary pattern of tuberculosis on chest radiograph in HIV positive patient coexisting with tuberculosis in our centre, necessitating the need for this study. It is believed, that the data and outcome of this study will guide in the future radiological diagnosis, management and health policy implementation in HIV infected patient in our environment.

MATERIALS AND METHOD

This study is done in University of Benin Teaching Hospital Benin, on 200 patients who had laboratory confirmation of HIV, with tuberculosis co-infection, and control group of 100 patients, who were HIV negative, but positive for tuberculosis infection, between 1st July, 2003 and 30th May, 2004. They were examined with chest radiography, in the hospital, after obtaining patients' consent.

The standard procedures of chest radiography were used, with minor adjustment to allow good image quality of the radiograph. These were analyzed with standard image viewing box by the two authors, who are Radiologists. The typical radiographic features of post primary tuberculosis were evidence of consolidation, fibrosis, cavitations and apical location of lesions, whereas atypical manifestation of primary tuberculosis were evidence of broncho-pulmonary/ miliary infiltrates, hilar lymphadenopathy, and pleural effusion. The other vital data taken was, CD4 T- lymphocyte count of the patients. Majority of the patient had automated CD4 T Lymphocyte count. Data analysis was carried out using Microsoft excel worksheet

RESULTS

A comparison of the chest radiographic findings of tuberculosis between HIV-sero-positive and HIV-sero-negative group in this study showed that the HIV-sero-positive group had significantly higher proportions of pleural effusion (24% v/s 8%) ($P < 0.001$), lymphadenopathy (47.5% v/s 14%) ($P < 0.001$) and broncho-pulmonary spread (73.5% v/s 49%) ($P < 0.001$); but had significantly lower proportions of volume loss (32% v/s 62%) ($P < 0.001$), fibrosis (27% v/s 73%) ($P < 0.001$), consolidation (43.5% v/s 71%) ($P < 0.001$), and cavitations (30.5% v/s 72%) ($P < 0.001$) (Fig 1).

Apical involvement of the lung in the study group was seen in 59(29.5%) patients while 141(70.5%) did not have changes in the apices of the lung. In the control group, apical involvement of the lung was seen in 79(79%) patients while 21(21%) had no changes in the apices of the lung. Apical involvement was significantly more in the control subjects when compared with the study group 59(29.5%) ($P < 0.001$)

In the study group, typical pattern of post primary tuberculous changes was seen in 58(29%) patients while 142(71%) patients had an atypical pattern of primary tuberculosis. In the control group, all had typical pattern of post primary tuberculosis while 21(21%) of them had some features of atypical pattern (Fig1). Atypical chest radiographic pattern was found to be significantly more in the HIV sero-positive (study) group when compared with the HIV-sero-negative group ($P < 0.001$).

The average CD₄ T lymphocyte count in the study group (HIV-sero-positive) was 173.90 cells/nl and median of 172 cells/nl. 128(64%) subjects had CD₄ T lymphocyte counts less than 200cell/nl while 72(36%) subjects had CD₄ lymphocyte count above or equal to 200 cells/nl (Table 2).

111(86.72%) subjects of the 128 subjects with a Cd₄

T lymphocyte count less than 200 cells/nl and 31(43.1%) subjects out of 72 with CD₄ T lymphocyte count 200 cells/nl or more had an atypical chest radiographic pattern of primary pulmonary tuberculosis. In fact, atypical chest radiographic pattern was more frequent among patients with CD₄ T lymphocyte count < 200 cell/nl (86.72%) compared with patients with CD₄ T lymphocyte count = 200 cells/nl (43.1%) (P<0.001) (Table2).

Table 1: Frequency and Percentage of Typical and Atypical Pattern in the Chest Radiographs of the Study and Control Groups.

| Type | HIV +ve (Study group) | HIV-ve (Control group) | Total |
|--------------|--------------------------|---------------------------|------------|
| Typical | 58(29%) | 79(79%) | 137 |
| Atypical | 142(71%) | 21(21%) | 163 |
| Total | 200(100%) | 100(100%) | 300 |

Figure 1: Multiple Bar Chart of Frequency of Abnormalities Recorded on the Chest Radiographs of Patients in the Study and Control Groups.

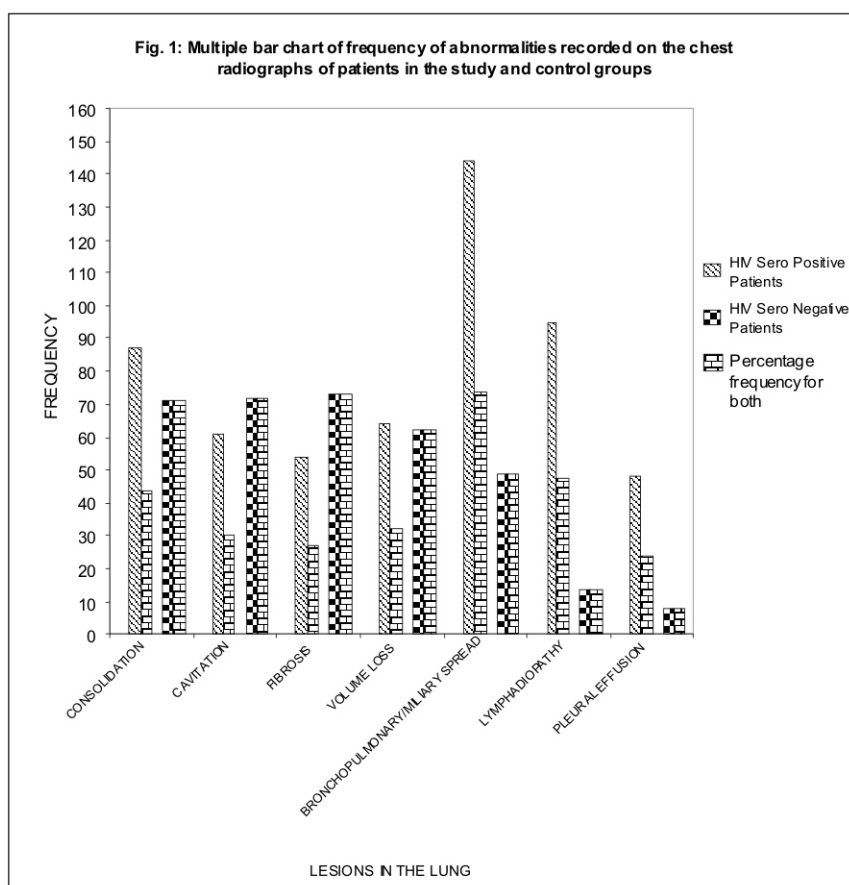


Table 2: Relationship by Frequency and Percentage between CD₄ T Lymphocyte Count and Chest Radiographic Pattern in the Study Group.

| CD ₄ lymphocyte count | Chest radiographic pattern | | Total |
|----------------------------------|----------------------------|------------|------------------|
| | Atypical no | Typical no | |
| CD ₄ < 200c/nl | 111(86.72%) | 17(13.28%) | 128(100%) |
| CD ₄ = 200c/nl | 31(43.1%) | 41(56.9%) | 72(100%) |
| Total | 142 | 58 | 200(100%) |

DISCUSSION

The study group shows that 29 percent of the patients has typical pattern of pulmonary manifestation of post-primary tuberculosis, while 71 percents has atypical pattern of pulmonary manifestation (table 1). The atypical pattern is the chest radiographic feature of primary tuberculosis. The reverse was the case in the control group where all had typical pattern of post primary tuberculosis, while 21 percent had additional features of atypical pattern of primary tuberculosis (table 1) The atypical patterns of primary tuberculosis seen were the following; pleural effusion, broncho-pulmonary nodular infiltrate, miliary nodules and lymphadenopathy (Fig 1). Whereas, the typical pattern of post primary tuberculosis seen were the following cavitations, consolidation, fibrosis, and volume loss (Fig 1).

This study showed that atypical pattern of primary tuberculosis were common in patients with CD4 T lymphocytes less than 200 cells/nl (86.72 percent) while typical pattern of post primary tuberculosis were common in patients with CD4 T lymphocytes more or equal to 200 cells/nl (56.8 percent) as shown in Table 1. These findings can be attributed to the variable immune state of the HIV positive patients at the time of evaluation. This is also suggesting that the better the immune state of the HIV positive patients the better is the control of the dissemination of pulmonary tuberculosis. This in effect may act as a therapeutic guide in the management of HIV positive patient co-infected with tuberculosis.

This study has shown that some typical patterns of pulmonary manifestations of post-primary tuberculosis were seen in HIV positive patients coexisting with tuberculosis who are considered to be immune-compromised. These features are also seen in normal immune patients who have been previously exposed to tuberculosis, since such reactions are due to immunological memory. These chest radiographic patterns have been previously documented in literature and are commonly seen in an endemic environment such as in the site of this study. In addition, normal chest radiogram has also been documented in HIV positive patients infected with tuberculosis⁸⁻¹².

There are other studies that have collaborated the findings of our study i.e., Tshibwabwa-Tumba et al⁷ in Zaire studied 963 cases of HIV-positive adults with tuberculosis in 3 Central African hospitals between 1992 and 1995. This was compared with 1000 age-matched HIV-negative adults with tuberculosis. The findings were that HIV-infected group of patients with tuberculosis had significantly higher proportions of lymphadenopathy (26% vs. 13%), pleural effusion (16% vs. 6.8%), miliary shadowing (9.8% vs. 5%), an interstitial pattern (12% vs. 7%) and consolidation (10% vs. 3%). There

were significantly less cavitations (33% vs. 7.8%) and atelectasis (12% vs. 24%) in the HIV positive group when compared with the HIV-negative group of patients.

Pelman et al¹² in New York, U.S.A. carried out such a study in which baseline chest radiographic findings and CD₄ T lymphocytes counts were compared among patients with HIV-related tuberculosis. It was found that CD₄ T lymphocyte counts of < 200 cells/nl (n=98) were significantly associated with hilar/mediastinal adenopathy on chest radiographs (30% vs. 7%). However counts of greater or equal to 200 cells/nl (n = 30) were more frequently associated with cavitations (20% vs. 7%).

Keiper et al¹³ in Philadelphia and Long et al¹⁴ in Haiti and others confirm similar findings in their studies. Even though some contrary opinion suggests failure to differentiate pneumocystic carina bronchopneumonia from primary tuberculosis and low yield with chest radiography and single sputum specimen test in differentiating HIV sero-positive and sero-negative tuberculous patients¹⁵⁻¹⁸.

Despite contrary opinions, these studies have demonstrated the association between the chest X-ray pulmonary findings of tuberculosis and HIV positive patient immune status. Other studies have significantly corroborated the relationship between tuberculosis and HIV, and the significant effect of immune-suppression on radiological-clinical manifestation of the patients²⁰⁻²⁵. It concluded that the knowledge of the degree of immuno-suppression is important when evaluating chest radiographic findings in HIV and tuberculosis infected patients.

This study is able to corroborate the findings as demonstrated in other places as mention above that the level of CD4 T Lymphocyte in HIV positive patients could determine the pulmonary features of tuberculosis on chest radiograph. The type of chest radiographic pattern in HIV sero-positive co-infected with tuberculosis may be used to imagine immune state of patient and can be a radiographic prognostic guide in the management of HIV positive patients co-infected with tuberculosis especially in this environment with significant limitations such as non availability of follow up laboratory diagnostic kits.

The other question is why are there atypical pulmonary features in HIV negative control group? Could this suggest that there are other contributory factors to pulmonary manifestations of tuberculosis? Lawn et al⁶ has shown radiographic features of tuberculosis suggesting less broncho-pulmonary spread (27.9% vs. 58.5%) in HIV positive compared to HIV negative in selected West African patients. In fact, as also suggested by other authors HIV has changed both the epidemiology and natural history of tuberculosis and despite a generally good response of

tuberculosis to effective anti-tuberculous therapy the prognosis remains poor²⁶⁻²⁸.

In conclusion, this study has shown variable chest radiographic manifestations of HIV positive patients co-infected with tuberculosis combined with the correlation in assessment of their CD4 T lymphocyte count. The relationship found between the two indices will help in the follow up prognostic evaluation of the patients.

REFERENCES

1. **Chakraborty MS, Chakraborty A.** Tuberculosis and HIV illness. *Indian Med Assoc* 2000; 98(3): 103-106.
2. **Lawn SD, Acheampong JW.** Pulmonary tuberculosis in adults. *W Afr J Med* 1999; 18(4): 270-274.
3. **Elliot AM, Lou N, Tembo G, Halwiindi B, Steenbergen G, Machiels L et al.** Impact of HIV on tuberculosis in Zambia: a cross section study. *BMJ* 1990; 301(6749):412-415.
4. **Orlovic, D, Kularatne R, Ferraz V, Smego RA Jr.** Dual Pulmonary Infection with Mycobacterium Tuberculosis and pneumocystis carinii in patients infected with human immunodeficiency virus. *Clin infect Dis.* 2001; 32(2):289-294.
5. **Lee MP, Chan JW, Ng KK, Li PC.** Clinical Manifestation of tuberculosis in HIV infected patients. *Respir* 2000; 5(4):423-426.
6. **Lawn SD, Evans AJ, Sedgwick PM, Acheampong JW.** Pulmonary tuberculosis: radiological features in West Africans co-infected with HIV. *Brit J of Radiol* 1999; 72(856): 339-344.
7. **Tshibwabwa-Tumba E, Mwinga A, Pobee JO, Zumbala A.** Radiographic features of pulmonary tuberculosis in 963 HIV infected adults at three Central African Hospitals. *Clin Radiol* 1997; 52(11): 837-841.
8. **Jasmer RM, Edinburgh KJ, Thompson A, Gotway MB, Creasman JM, Webb RW et al.** Clinical and radiographic predictors of the etiology of pulmonary nodules in HIV-infected patients *Chest* 2000; 117(4):1023-1030.
9. **Palmieri F, Girardi E, Pellicelli AM, Rianda A, Bordi E, Rizzi EB, et al.** Pulmonary tuberculosis in HIV-infected patients presenting with normal chest radiograph and negative sputum smear. *Infection* 2000; 30(2): 68-74.
10. **Asimos AW, Erhardt J.** Radiographic presentation of pulmonary tuberculosis in severely immuno suppressed HIV seropositive patients. *Am Journal of Emer Med* 1996; 14(4):359-363.
11. **Tiouiri H, Louzir B, Ben Salem N, Beji M, Kilani B, Gastli M, et al.** Standard radiological characteristics of thoracic sites of tuberculosis in patients with AIDS in a Tunisian population. *Rev Pneumol clin.* 1995; 51(6):321-324.
12. **Pelman DC, El-Sadr WM, Nelson ET, Matts JP, Telzak EE, Solomon N, et al.** Variation of chest radiographic patterns in pulmonary tuberculosis by degree of human immunodeficiency virus-related immunosuppression. *Clin Infect Dis* 1997; 25(2):242-246.
13. **Keiper MD, Beamont M, Elshami A, Lanhlotz CP, Miller WT Jr.** CD₄ T-lymphocyte count and the radiographic presentation of pulmonary tuberculosis. *Chest* 1995; 107(1): 74- 80.
14. **Long R, Maycher B, Scalcini M, Manfreda J.** The chest roentgenogram in pulmonary tuberculosis patients seropositive for human immunodeficiency virus type 1. *Chest.* 1991; 99(1): 123-7.
15. **Bioselle PM, Tocino I, Hooley RJ, Pumerantz AS, Selwyn PA, Neklesa VP, et al.** Chest radiograph interpretation of penumocystis carinii pneumonia, bacterial pneumonia and pulmonary tuberculosis in HIV positive patients: accuracy, distinguishing features, and mimics. *J of Thoracic Imag* 1997; 12(1): 47-53.
16. **Finch D, Beaty CD.** The utility of a single sputum specimen in the diagnosis of tuberculosis. Comparison between HIV-infected and non-HIV-infected patients. *Chest.* 1997; 111(5): 1153-1155.
17. **Ho TT, Wong KH, Lee SS.** Low yield of chest radiography in screening for active pulmonary tuberculosis in HIV infected patients in Hong Kong. *Int. J of STD AIDS* 1999; 10(6) 409-412.
18. **Mlika-Carbanne N, Brauner M, Kamanfu G, Grenier P, Nikoyagize E, Aubry P, et al.** Radiographic abnormalities in tuberculosis and risk of co-existing human immunodeficiency virus infection. *Am J. Respir Crit Care Med.* 1995; 152(2): 794-9.

19. **Burman WJ, Jones BE.** Clinical and radiographic features of HIV-related tuberculosis. *Semin Respir Infect.* 2003; 18(4): 263-71.
20. **Ormerod L.** Respiratory tuberculosis. In: Davies P.D.O. (ed). *Clinical tuberculosis.* London. Chapman and Hall Medical 1994: 73-92.
21. **Garay SM.** Pulmonary tuberculosis. In: Rom WN and Garay SM (ed) *Tuberculosis.* Boston. Little and Brown 1996: 373-412.
22. **Barnes PF, Bloch AB, Davison PT, Snider Jr. DE.** Tuberculosis in Patients with human immunodeficiency virus infection. *N Engl Med* 1991; 324(23): 1644-50.
23. **Shafer RW, and Edlin BR.** Tuberculosis in patients infected with human immunodeficiency virus: perspective on the past decade. *Clin Infect Dis.* 1996; 22(4): 683-704.
24. **Goodman PC.** Tuberculosis and AIDS. *Radiol Clin North Am.* 1995; 33(4): 707-717.
25. **Cecconi L, Busi Rizzi E, Mazzuoli G, Schinina V.** Pulmonary infection in acquired immunocompromission. *Clinoradiological correlation.* *Radiol Med* 1994; 87(5 suppl 2): 34-51.
26. **Whaleu C, Okwera A, Johnson J, Vjecha M, Hom D, Wallis R, et al.** Predictors of Survival in human immunodeficiency virus infected patients with tuberculosis. *Am J. Respir Crit Care Med.* 1996; 153 (6 pt 1): 1997-1981.
27. **Gold JA, Rom WN, Harkin TJ.** Significance of abnormal chest radiograph findings in patients with HIV-1-infection without respiratory symptoms. *Chest* 2002; 121(5):1472- 1477.
28. **Hlawatsch A, Kauczor HU, Thelen M.** Pulmonary tuberculosis the current radiological diagnosis of an old disease. *Radiol* 2000; 40(6):507-517.