

EXPERIENCE WITH THREE-DIMENSIONAL COMPUTED TOMOGRAPHIC ANGIOGRAPHY IN IBADAN, NIGERIA

GI Ogbole, AO Ogunseyinde, MO Obajimi, OA Adeyinka
Department of Radiology, University College Hospital Ibadan, Nigeria

ABSTRACT

Introduction: The latest versions of spiral CT scanners have provided the radiologist with unparalleled capabilities for vascular imaging. Computed Tomographic Angiography (CTA) has the potential of revolutionizing vascular imaging and with evolving improvements may replace conventional angiography in the near future

Objective: To report our initial experience with CTA in Nigeria; highlighting its usefulness as a non invasive modality and its clinical applications in diagnosis of vascular abnormalities of various parts of the body.

Materials and Methods: We reviewed 62 patients who had CTA between December 2003 and September 2005. The studies were performed using a spiral technique with GE CT/e single-slice scanner (General Electric Medical Systems) having a gantry rotation period of one second. Details of techniques of data acquisition, methods of 3-D reconstruction and clinical applications are discussed.

Results: Vascular abnormalities were demonstrated in 26 (42%) patients including 5 cranial arteriovenous malformations (AVMs), 3 intracranial aneurysms, 1 spinal AVM, 3 aortic aneurysms, 5 carotid artery stenosis, and 2 traumatic peripheral aneurysms.

Conclusion: Correlations between CTA and surgical findings were good. CT angiography has enhanced our practice of vascular radiology in Ibadan as it has done in the west and other parts of the world.

Key Words: 3D, CT angiography; Spiral CT; Vascular imaging.

(Accepted 28 April 2009)

INTRODUCTION

CT angiography (CTA) is a relatively new and vital application of spiral CT that allows an accurate depiction of vascular structures in three dimensions with complete separation of superimposed structures. Catheter angiography developed in 1953, has since been regarded as the gold standard for vascular imaging and has been used extensively; however it is invasive, expensive and has an associated risk of 1.5 to 2% of significant morbidity and mortality.^{1,2}

These disadvantages led to the development of a number of other vascular imaging techniques such as Colour Doppler Ultrasound (CDUS) and Magnetic Resonance Angiography (MRA) which are non-invasive. Over the last few years following the advent of spiral CT, CT angiography has also become an important technique for vascular evaluation. Although the spatial resolution of CT angiography is less than that of conventional catheter angiography, it can be used to assess arteries as small as 2 mm in diameter; moreover the 3-D reconstructed images can be viewed from an unlimited number of angles.³ CTA is not associated with significant patient

risks,⁴ and has an image acquisition time of less than one minute.⁵⁻⁷ MRA has several drawbacks relative to CTA which sometimes include longer examination times with resultant motion artifacts, pulsation artifacts, poor demonstration of calcium and bony landmarks. In addition, post operative status evaluation in patients with metallic clips and stents is not easy with MRA.⁸

Compared to MRA and CDUS, CTA is faster, less expensive, more widely available, more sensitive for mural calcium, can display bony landmarks well and also can be used in patients with aneurysm clips and other MR incompatible metallic hardware.⁸

These advantages along with the non-invasive nature of the technique and reduced scanning time have brought CT angiography into prominence in the arena of vascular imaging. Fortunately CTA techniques are improving rapidly and are likely in the future to replace conventional angiography for the diagnosis of vascular lesions.⁹

The acquisition of a spiral CT scanner by the University College Hospital (UCH) Ibadan, Nigeria-the apex tertiary institution in the country prompted the need for an assessment of its diagnostic potential in vascular imaging, since intra-arterial catheter angiography which is the gold standard is unavailable at the institution.

Correspondence: Dr GIOgbole
E-mail: gogbole@yahoo.com

MATERIAL AND METHODS

A total of 62 CT angiographies were performed from December 2003 to September 2005 on patients referred from various regions in Nigeria. Their ages ranged from 9 to 76 years. The investigations were performed using a spiral technique with GE CT/e single-slice scanner (General Electric Medical Systems) having a gantry rotation period of one second.

An informed consent was obtained from all patients. The various vascular regions studied by CTA are outlined in Table 1.

Spiral CT acquisition: All patients were positioned supine on the CT table, with immobilization achieved where necessary using adhesive tape. A preliminary non-contrast axial CT scan with 5-10 mm collimation was performed to localize the volume of interest and to detect any abnormal vascular calcification. After scan area localization using the scanogram, a delay time was selected. An 18-gauge cannula was inserted into the antecubital vein of each patient for injecting 100-140ml of contrast material (Urografin 76%; Schering, Berlimed S.A. Spain) by using a pump injector at a specified rate. Image acquisition was tailored based on clinical indication, to demonstrate vessels of areas of interest using an appropriate CTA protocol. The scanning parameters and protocols used are depicted in Table 2.

Post processing of images: The advantage of volumetric spiral CT acquisition is that 3D images can be generated, which can be viewed from myriad angles, such views are unattainable with conventional catheter angiography. Reformatting and processing of source images were performed on the CT/e operator workstation (GE Medical Systems) at the end of each procedure. Images were reconstructed using visual thresholding to remove bone without deleting vascular structures. Average post processing time for each study was 40 minutes. The total examination time did not exceed 1 hour including the 3D reconstruction. Standard sagittal and coronal oblique images plus curved multiplanar reformatted images were obtained. 3D Maximum Intensity Projection (MIP) and Shaded-Surface Display (SSD) were the algorithms used to display the images. Targeted MIP imaging of the vertebrobasilar system and circle of Willis were performed in all patients with cerebral CTA. The degree of carotid stenosis was measured separately on axial, and MIP images. Stenosis measurements were made directly using the CT software measurement calipers by comparing the stenosis diameter at its narrowest point to the normal internal carotid artery.

RESULTS

62 patients, 38 males and 24 females, were examined and the abnormalities detected in various vascular territories are recorded in Table 3.

28 patients were examined with varied clinical presentations for cerebral vascular abnormalities (Table 4), 15(53.6%) showed abnormality, these include 6 arteriovenous malformations (AVMs), 3 cerebral aneurysms, and 1 arterial and venous thrombosis each. There were also 3 cases of tumour vascular compression and displacement.

The distributions of these abnormalities are shown in Table 3. Five of the AVMs were intracranial and 1 extracranial. The sizes of the AVMs ranged from 3.0cm to 8.5cm, mean 5.5 ± 0.3 cm (standard deviation). Two of these cases have had successful surgical interventions, while others are awaiting surgery. One of the patients with AVM presented with an associated spontaneous intracerebral haemorrhage. An emergency 3D CTA was able to provide a clear detail of the lesion. (Fig.1)

The three cerebral aneurysms were demonstrated, in the left posterior communicating artery, anterior communicating artery (Fig.2) and the left internal carotid artery. Two of the aneurysms were fusiform and the other saccular in shape. Their widest diameter measured between 5mm and 10mm. The ratio of arteriovenous malformation to cerebral aneurysm was 2 to 1. One patient had post aneurysmal clipping assessment; this revealed a normal vascular appearance.

9 patients had CTA of the extracranial carotid arteries. Out of these, 5 were confirmed to have significant stenosis. The degree of stenosis were graded on a four point scale of A) No Stenosis, B) Mild (<30%) Stenosis, C) Moderate (30%70%) Stenosis, D) Severe (>70%) Stenosis.¹⁰

Four (80%) had moderate stenosis that were caused by tumours including glomus jugulare tumour (Fig. 3). Only 1(20%) was caused by a calcified arterial plaque. There was associated significant displacement of the external carotid artery in 2 patients.

A spinal AVM was demonstrated in a 26 year old female who presented with a 2 months history of progressive quadriplegia (Fig. 4). She became ambulant 6 months after surgical clipping and excision.

CT angiography of the thoracic aorta was performed in 2 patients both of whom had De Bakey type 1 dissection (Fig.5). 3 patients underwent CT angiography of the abdominal aorta. Out of these, 2 were confirmed of having abdominal aortic aneurysms; one of these patients had multiple aneurysms with an area of stenosis close to the aortoiliac junction (Fig. 6).

12 renal CT angiography were performed out of

which 2 were for pre-surgical evaluation of patients with renal tumours. The remaining 10 were potential renal transplant donors (Fig.7). Findings are as shown in Table 3.

Seven patients had a peripheral CTA of iliac and lower limb vasculature. A huge post-traumatic aneurysm of the superior gluteal artery was demonstrated in one patient, this was subsequently successfully excised, and another patient had traumatic aneurysm of the femoral artery (Fig.8). Other findings including multiple femoral artery stenosis and peripheral vascular tumour are as shown in Table 3. Figure 9 shows the case of a scalp arteriovenous malformation in a 19-year-old male. No case of adverse contrast reaction was recorded.

Table 1: **Regional Distribution and Clinical Indications of CT Angiography (N=62)**

Region	Indications	No of Patients
Intracranial circulation		
	Suspected aneurysm	7
	Suspected AVM	9
	Subarachnoid haemorrhage	2
	Evaluation of post clipping status of aneurysm	1
	Post-operative follow up of AVM	1
	Pre-operative vascular evaluation of tumours	6
	Suspected carotico-carvenous fistula	1
	Cerebrovascular ischaemia	1
Extracranial carotid arteries		
	Evaluation of carotid vessels	4
	Evaluation of vascularity of neck masses	5
Thoracic aorta		
	Suspected of aneurysm of thoracic aorta	3
Abdominal aorta		
	Evaluation of abdominal aortic aneurysm	2
Renal arteries		
	Potential renal transplant donors	10
	Pre operative evaluation of renal tumour	2
Splanchnic arterial system		
	Evaluation of lower gastrointestinal bleeding	1
Ilio-femoral arteries		
	Evaluation of lower limb tumour	3
	Evaluation of traumatic gluteal aneurysm	1
	Evaluation of vascular trauma	2
	Evaluation of arterial thrombosis	1

Table 2: **Protocols for CT Angiographies of Various Regions.**

Region	Slice thickness (mm)	Pitch	Coverage (mm)	Contrast (ml)	Rate (ml/s)	Delay (s)
Cerebral	1	1	40-50	100	3.5	15-18
Carotid	2	1.5	60-80	120	3.5	18-20
Thoracic aorta	3	2.0	120-150	120	3.5	15-18
Abdominal aorta	3	2.0	120-150	120	3.5	15-20
Renal	3	1.5	120-140	120-140	3.5	15-18
Ilio-femoral	3	1.5	120-150	120-140	3.5	20-25

Table 3: **Analysis of Results of CT angiographic Studies (N=62)**

Cerebral	
Intracranial circulation	
Aneurysm of internal carotid artery	1
Aneurysm of Posterior Communicating Artery	1
Aneurysm of Anterior Communicating Artery	1
AV malformations	5
Status of clipped aneurysm (normal)	1
Basal vein thrombosis	1
MCA thrombosis	1
Tumour vascular displacement/compression	3
Extracranial	
Extracranial AVM (cirsord aneurysm)	1
Normal	13
Carotid	
Spinal AVM	1
Carotid artery stenosis	4
Atherosclerotic stenosis of ICA	1
Normal	3
Aortic	
Dissection of thoracic aorta	2
Infrarenal abdominal aortic aneurysm	2
Normal	1
Renal	
Renal artery stenosis	1
Pre-hilar branching	1
Normal (renal donors)	8
Pre-surgical tumour evaluation	2
Iliac and Peripheral	
Superior gluteal artery aneurysm	1
Vascular tumour (<i>Haemangiopericytoma</i>)	1
Traumatic femoral artery aneurysm	1
Diffuse atherosclerotic disease	2
Vascular displacement by soft tissue tumour	1
Normal ilio-femoral arteries	1

Table 4: Clinical Features of Patients with Suspected Intracranial Vascular Abnormality.

Clinical feature	Number	Percentage (%)
Severe headache	17	32.7
Tumour	10	19.2
Seizures	7	13.5
Visual impairment	6	11.5
Hemiplegia / Hemiparesis	5	9.8
Subarachnoid haemorrhage	3	5.7
Ptosis	2	3.8
Proptosis	2	3.8
Total	52*	100

*Some patients presented with more than one feature

Figure 1: 3D-MIP image showing an AVM (arrow) involving the posterior cerebral artery with calcifications within it.

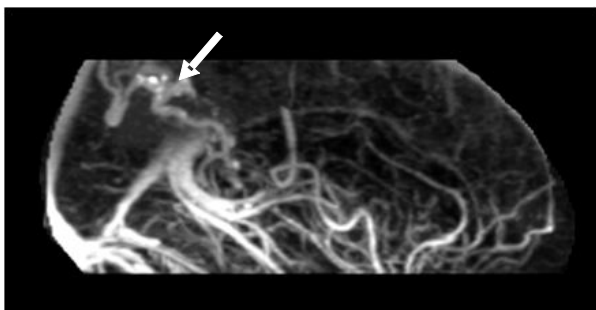


Figure 2: 3D-MIP image shows saccular aneurysmal dilatation (arrow) in the region anterior communicating artery in a 56 year old woman with sudden severe headaches.

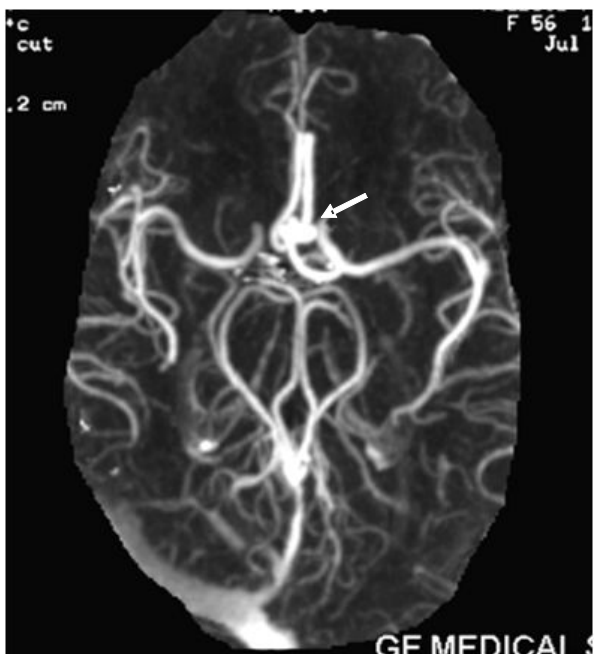


Figure 3: MIP image showing encasement and stenosis of internal carotid artery by a glomus jugulare tumour in a 64-year-old male.

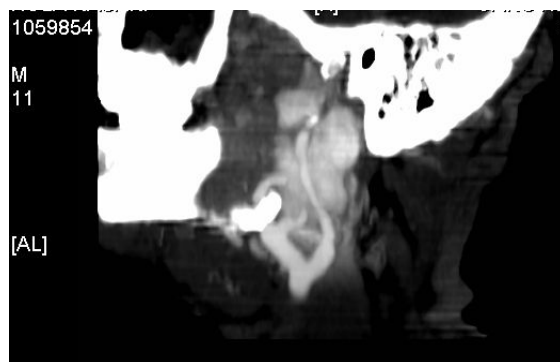


Figure 4: 3D MIP image showing tortuous network of intra-spinal vessels (arrow) in the neck of a patient with a spinal arteriovenous malformation.

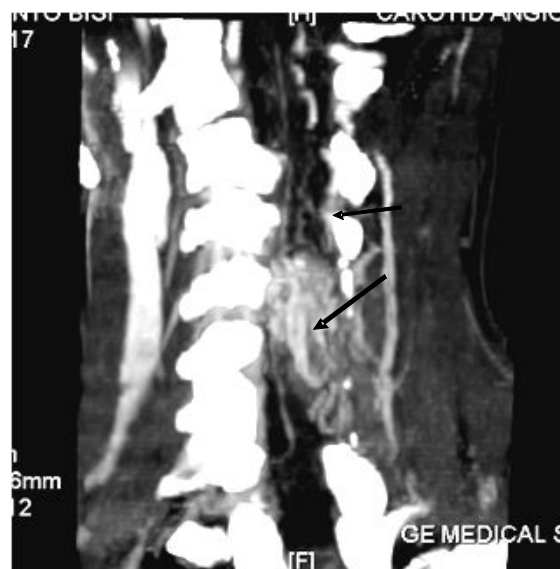

Figure 5: Oblique reformatted 3-d mip image showing aneurysmal aortic dilatation with extensive mural calcifications and intramural haematoma (arrow).

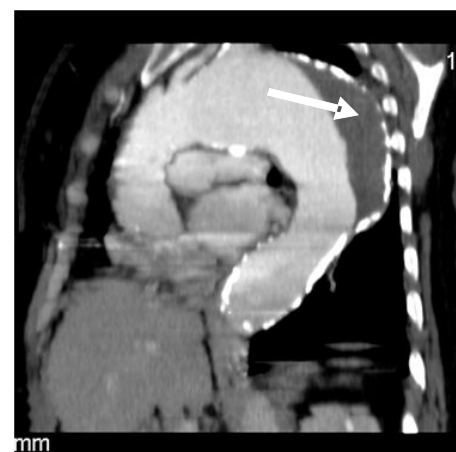

Figure 6:SSD Image showing multiple infrarenal and aorto-iliac aneurysms (arrows) with associated aortic stenosis (arrow head) in a 19-year-old male.

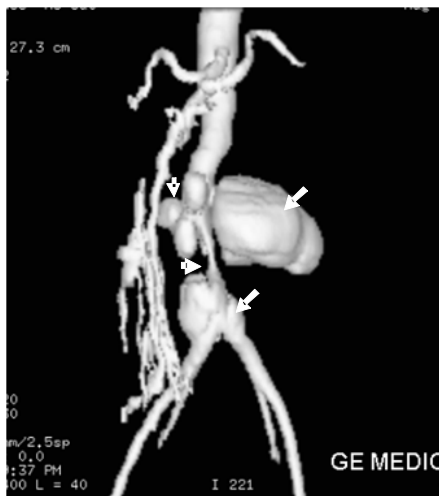

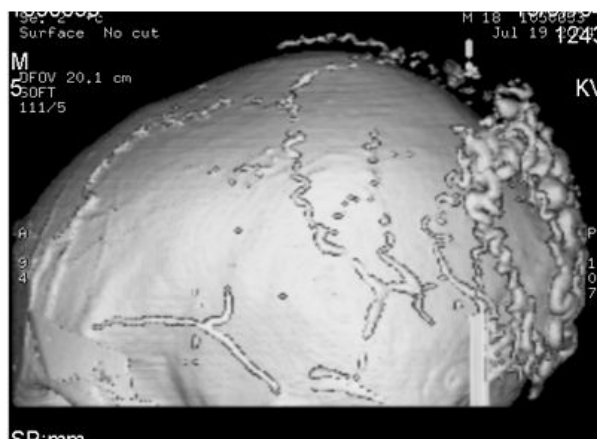
Figure 7: 3D SSD image showing normal renal arteries in a potential renal donor.

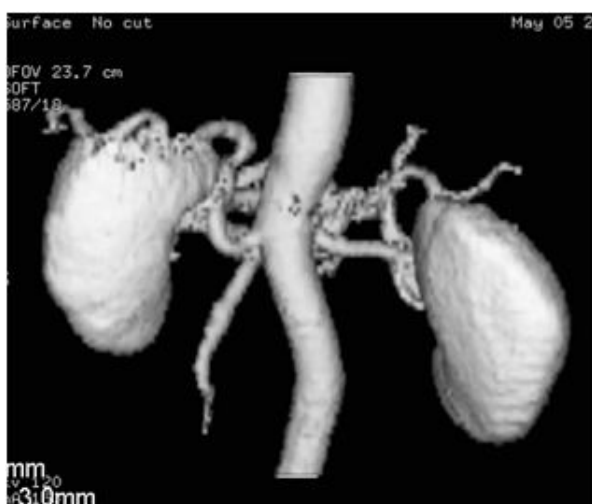

Figure 8: MIP Image showing traumatic femoral aneurysm (arrow) following a gunshot injury to the right thigh.

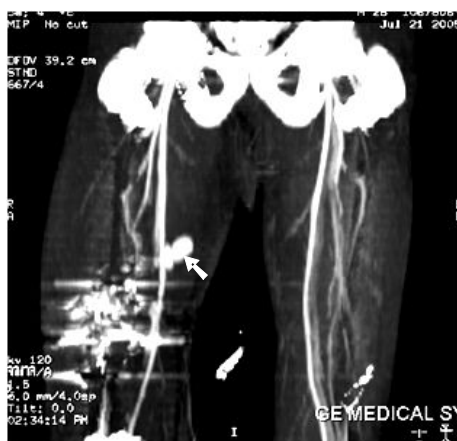

Figure 9: 3D surface shaded display image showing dilated tortuous occipital vessels in a patient with an extracranial scalp arteriovenous malformation.



DISCUSSION

Although catheter angiography and specifically digital subtraction angiography (DSA) is considered the gold standard in the evaluation of vascular abnormalities, this technique is however time consuming, invasive and carries a complication risk of about 1% and 0.5% risk of persistent neurological deficit.¹¹ Moreover, when performed during the first six hours of bleeding has been associated with an increased rebleeding rate.¹² CT angiography is better than catheter angiography in the characterization of aneurysms, as it provides detailed anatomy of the vessel of origin of the aneurysm, this information is useful in determining the modality of treatment whether endovascular or surgical. Though CTA is cheaper and safer than catheter angiography, the examination which costs N60, 000.00 (\$450.00) is still unaffordable for most patients in our environment, where 70.2% of the population live on less than \$1.00 per day.¹³

The ratio of intracranial arteriovenous malformation to cerebral aneurysm of 2 to 1 recorded in this series is in contrast with 1 to 3 reported by Adeloje et al,¹⁴ their study which spanned a period of 15 years however may be more representative. This study however confirms the low incidence of intracranial vascular anomaly in Ibadan as the finding of 5 intracranial AVMs and 3 cerebral aneurysms agrees with their report of a hospital incidence of 2 intracranial vascular anomalies per year in Ibadan.¹⁴

The symptomatology of ruptured intracranial aneurysm and bleeding AVM is often so serious that the patient seeks medical attention to relieve distressing headache, neck stiffness, alteration in consciousness or neurological deficit. Nevertheless, some patients never make it to the hospital. The cases reported here show that the clinical picture of

intracranial vascular anomalies is no different from that of previous studies in our environment as well as in Caucasians.^{9,14-17}

With the advent of newer imaging facilities the detection of carotid artery disease has increased. Although catheter angiography is accepted as the imaging modality of choice for estimating carotid artery disease, a number of studies have indicated that the risks of catheter angiography are equal to or even greater than the treatment itself.² Moreover, eccentric or irregular stenosis may not be optimally assessed due to limited number of views available with conventional angiography. CT angiography has shown to have a sensitivity of 88-100% in estimating severe stenosis and occlusion, as it can provide infinite views for accurate estimation of eccentric or irregular stenosis.¹⁸ Studies by Marks et al¹⁹ have shown that in the estimation of carotid stenosis, CT angiography has a definite superiority over MR angiography, especially in estimating high grade stenosis and occlusions. MR angiography however tends to overestimate stenosis when there is turbulent flow due to loss of signal as MR angiography is dependent on flow characteristics and not volume of the blood. CT angiography also gives higher sensitivity and specificity as compared to colour flow Doppler imaging in differentiating severe stenosis from complete occlusion; this is of paramount importance from the therapeutic point of view as severe stenosis is an indication for carotid endarterectomy whereas complete occlusion is a contraindication. In the cases of carotid arterial stenosis, the three types of reconstruction techniques were used (MIP, SSD and axial) to describe the area of stenosis. The reliability of carotid stenosis measurement depends on the scanning technique. The protocol used in this study was very similar to that of previous studies²⁰⁻²⁴ that have recorded impressive results. Castillo who used a 5mm collimation, a small amount of contrast material (60ml) and 3mm increment reported comparatively poorer results.²⁵

In assessing stenosis, intramural calcification was not a limiting factor; axial sections were helpful in delineating the vascular lumen.

Noninvasive evaluation of thoracic aorta and pulmonary arteries is possible with CT angiography. Evaluation of post surgical status of the arch of aorta following stenting can only be achieved with CT angiogram as these patients are unsuitable candidates for MR angiography and catheter angiography is invasive and less accurate. Evaluation of abdominal aortic aneurysm requires an accurate pre-operative anatomy of the abdominal aorta especially the relationship of the aneurysm to the major aortic branch vessels, presence of any accessory renal arteries, assessment of renal artery

stenosis if any. All this information can be provided to the vascular surgeon through a single spiral CT angiography, which also has an added advantage of detecting the presence of calcium and assessing the true diameter of the aneurysm and not merely the patent lumen as in catheter angiography.

Catheter angiography has also been the reference standard for evaluation of renal vasculature, however, CT angiography is a promising technique for identifying or excluding abnormalities. In cases of severe stenosis a discontinuity in the vessel can be observed on CT angiography, however, stenosis and not complete occlusion can be inferred by vascular opacification distal to the stenosis.

CT angiography is the only imaging modality providing fast, non-invasive, inexpensive and accurate pre and post-operative anatomy of the renal parenchyma and vasculature. Pre-operative CTA delineation of the renal arterial system was consistent with intra-operative findings in all the renal units removed. The volume of contrast material used in spiral CTA may be of concern with regard to nephrotoxicity; however, the risk seems to be negligible in healthy renal donors and is the same as that found with conventional arteriography.²⁶

Evaluation of the status of the iliac arteries is mandatory prior to vascular grafting or stenting of abdominal aortic aneurysms. CT angiography enables visualization of the distal abdominal aorta to the bifurcation of the femoral arteries in a single 30-40 second scan. Lawrence et al, have found that correctly performed CT angiograms have a sensitivity of 93% and a specificity of 96% in diagnosing significant stenosis of the iliac arteries as compared to catheter angiography.²⁷ CT angiography accurately demonstrates the presence of diffuse atherosclerotic disease, calcified plaques, evaluates the degree of aorto-iliac stenosis and important collateral arterial supply from the internal iliac, lumbar, intercostal and contralateral iliac arteries. Spiral CT angiography is a rapidly evolving technique with vast potential in the field of vascular imaging. It provides a minimally invasive, fast, accurate and economical alternative for imaging the vasculature that was traditionally performed with catheter angiography. Currently the use of multi-detector CT and availability of sophisticated software such as volume rendering technique avails the radiologist with unprecedented high quality vascular images. However, it remains to be seen whether CT angiography will compete with contrast enhanced MR angiography and surpass it or remain second-rate. However the introduction of Multidetector CT (MDCT) has increased scanning speed, allowing shorter acquisition time, greater volume coverage and decreased contrast requirement while diminishing respiratory motion artifacts²⁸. Non-

invasive imaging of cardiac system and coronary arteries is also now possible with MDCT through multiple image acquisition at 125-250msec²⁹.

Thus far the unavailability of conventional angiography in Ibadan has made our surgeons to rely on CTA in managing patients with vascular abnormalities and have recorded remarkable results.

CONCLUSION

With its ability to perform comprehensive examinations from head to toe, CT angiography has enhanced our practice of vascular radiology in Nigeria as it has done in the west and other parts of the world. Adapting to required changes has provided a foundation for modifications in work pattern and improvements in technical skills. Our initial experience has been a time of both challenge and opportunity. It is hoped that this article will stimulate an excitement in radiologists and surgeons in this region to utilize the benefits of this fast growing imaging modality.

REFERENCES

1. **Waugh JR, Sacharia N.** Arteriographic complications in the DSA era. *Radiology.* 1992; 182:243-6.
2. **Kuszyk BS, Norman JB Jr, Fishman EK.** Neurovascular applications of CT angiography. In *CT angiography. Seminars in Ultrasound, CT & MR.* 1998; 19: 394-403.
3. **Rubin GD, Dake MD, Semba CP.** Current status of three dimensional spiral CT scanning for imaging the vasculature. *Radiol Clin North Am* 1995; 33:51-70.
4. **Mikkonen R, Kontkanen T, Kivisaari L.** Acute and late adverse reactions to low-osmolar contrast media. *Acta Radiol.* 1995; 36:72-76.
5. **Lenhart M, Bretschneider T, Gmeinwieser J, Ullrich OW, Schlaier J, Feuerbach S.** Cerebral CT angiography in the diagnosis of acute subarachnoid hemorrhage. *Acta Radiol.* 1997; 38:791-796.
6. **Velthuis BK, Rinkel GJE, Ramos LMP, Witkamp TD, Berkelbach van der Sprenkel JW, Vandertop PW, van Leeuwen MS.** Subarachnoid hemorrhage: aneurysm detection and preoperative evaluation with CT angiography. *Radiology.* 1998; 208 :423-430
7. **Villablanca JP, Martin N, Jahan R, Gobin YP, Frazee J, Duckwiler GR, Bentson J, Hardart M, Coiteiro D, Sayre J, Vinuela F.** Volume-rendered helical computerized tomography in the detection and characterization of intracranial aneurysms. *J Neurosurg.* 2000; 93:254-264.
8. **Prashant GS, Jhaveri KS.** Neurovascular Applications of CT Angiography. *Ind J Radiol Imag.* 2000; 10:123-41.
9. **Sasiadek M, Hendrich B, Turek T, Kowalewski K, Maksymowicz H.** Our own experience with CT angiography in early diagnosis of cerebral vascular malformations. *Neurol Neurochir Pol.* 2000; 34:48-55.
10. **Leclerc X, Godefroy O, Lucas C, Benhaim J, Michel TS, Leys D, Pruvo P.** Internal Carotid Arterial Stenosis: CT Angiography With Volume Rendering. *Radiology.* 1999; 210:673-682.
11. **Heiserman JE, Dean BL, Hodak JA, et al.** Neurologic complications of cerebral angiography. *AJNR* 1994; 14: 1401-7.
12. **Saitoh H, Hayakawa K, Nishimura K, et al.** Re-rupture of cerebral aneurysms during angiography. *AJNR* 1995; 16:539-42.
13. Country profiles for population and reproductive health: policy development and indicators 2003. pp 70 UNFPA publication 2003 (<http://www.unfpa.org/profile>).
14. **Adeloye AA, Olumide A, Bademosi O, Kolawole TM.** Intracranial vascular anomalies in Nigerians. *Trop. Geogr.Med.* 1981; 33:263-267
15. **Odeku EL.** Intracranial vascular anomalies in Nigerians. *J Nat. Med. Ass.* 1968; 60:173-180.
16. **Ohaegbulam SC.** Racial bias in intracranial arterial aneurysms. *Trop. Geogr.Med.* 1978; 30:305-311.

17. **Rieger J, Hosten N, Neumann K, Langer R, Molsen P, Lanksch WR, Pfeifer KJ, Felix R.** Initial clinical experience with spiral CT and 3D arterial reconstruction in intracranial aneurysms and arteriovenous malformations. *Neuroradiology* 1996; 38:245-251.
18. **Wise SW, Hopper KD, Have TT, Schartz T.** Measuring carotid artery stenosis using CT angiography : the dilemma of artifactual lumen eccentricity. *AJR* 1998;170:919-23.
19. **Marks MP, Napel S, Jordan JE, Enzmann DR.** Diagnosis of carotid artery disease. Preliminary experience with maximum intensity projection spiral CT angiography. *AJR* 1993; 160:1267-71.
20. **Link J, Mueller-Huelsbeck S, Brossmann J, Grabener M, Stock U, Heller M.** Prospective assessment of carotid bifurcation disease with spiral CT angiography in surface shaded display (SSD)-technique. *Comput Med Imaging Graph.* 1995; 19:451-456.
21. **Link J, Brossmann J, Grabener M, Mueller-Huelsbeck S, Steffens JC, Brinkmann G, Heller M.** Spiral CT angiography and selective digital subtraction angiography of internal carotid artery stenosis. *Am J Neuroradiol.* 1996; 17:89-94.
22. **Schwartz RB, Jones KM, Chernoff DM, Mukherji SK, Khorasani R, Tice HM, Kikinis R, Hooton SM, Steig PE, Polak JF.** Common carotid artery bifurcation: evaluation with spiral CT. *Radiology.* 1992; 185:513-519.
23. **Cumming MJ, Morrow IM.** Carotid artery stenosis: a prospective comparison of CT angiography and conventional angiography. *Am J Roentgenol.* 1994; 163:517-523.
24. **Dillon EH, Van Leeuwen MS, Fernandez MA, Eikelboom BC, Mali WPTM.** CT angiography: application to the evaluation of carotid artery stenosis. *Radiology.* 1993; 189:211-219.
25. **Castillo M.** Diagnosis of disease of the common carotid artery bifurcation: CT angiography vs. catheter angiography. *Am J Roentgenol.* 1993; 161:395-398.
26. **Olbricht CJ, Paul K, Prokop M, Chavan A, Schaefer-Prokop CM, Jandeleit K, Koch KH, Galanski M.** Minimally invasive diagnosis of renal artery stenosis by spiral computed tomography angiography. *Kidney Int.* 1995; 48:1332-1337.
27. **Lawrence JA, Kim D, Kent KC, Stehling MK, Rosen MP, Raptopoulos V.** Lower extremity spiral CT angiography versus catheter angiography. *Radiology* 1995; 194:903-8.
28. **Indrajit IK, Souza JD, Bedi VS, Pant R.** Impact of Multidetector CT on 3D CT Angiography. *MJAFI* 2005; 61 : 360-363.
29. **Giesler T, Baum U, Ropers D, Ulzheimer S et al.** Noninvasive visualization of coronary arteries using contrast-enhanced multidetector CT: influence of heart rate on image quality and stenosis detection. *Am J Roentgenol.* 2002; 79:911-6.